

Dysphagia in Hereditary Sensory Autonomic Neuropathy Type IV

Pages with reference to book, From 121 To 123

Uzma Shah (Departments of Pediatric Gastroenterology, The Aga Khan University Hospital, Karachi.)
Muhammad Arshad (Departments of Nutrition, Pediatric Surgery, The Aga Khan University Hospital, Karachi.)
Tahseen Mozaffar (Departments of Medicine and Pathology, The Aga Khan University Hospital, Karachi.)

Introduction

There has been tremendous progress in the detection and diagnosis of hereditary neuropathies and while the genes responsible for these rare neuropathies have improved our understanding of the development of the sensory system, they remain clinical enigmas with rare occurrences and diverse presentations^{1,2}. In 1963, Swanson first described two brothers with congenital insensitivity to pain, anhidrosis and mild mental retardation³. Several different types of hereditary sensory autonomic neuropathies (HSAN) have been delineated since then¹.

Case Report

Patient 1: This 13 year old boy, product of a consanguineous marriage, presented to the pediatric gastroenterology clinic , for persistent vomiting for four months. His post-prandial vomiting occurred more with solids and had worsened over the past month. Vomitus contained undigested food material and eating was associated with retrosternal discomfort. Constipation was a constant feature and there had been considerable weight loss over the past few months. He had anhidrosis with difficulties in body temperature control. His past history was significant for numerous hospitalizations for “sepsis” and fever since early neonatal life. Because of insensitivity to pain, he had had repeated trauma to his extremities with traumatic auto amputation and acro-mutilation. He also had multiple laceration injuries to his mouth and oral cavity with resultant fibrosis and scarring. Although he retained freedom of movement of all extremities, he had developed Charcot joints. He had been seen by numerous physicians and surgeons in his 13 years of life, with failure to reach a unifying diagnosis. Family history was positive for similar features in a three year old female sibling. There was an absence of pain sensation in an 11-year-old and an eight year-old female sibling as well. He had two other normal siblings.

Examination revealed growth retardation (5th centile for height and weight). His vital signs were normal and orthostatic hypotension was not detected. Multiple areas of scarring and ulceration were present over his forehead and scalp. His mouth was small, deformed (Figure 1)

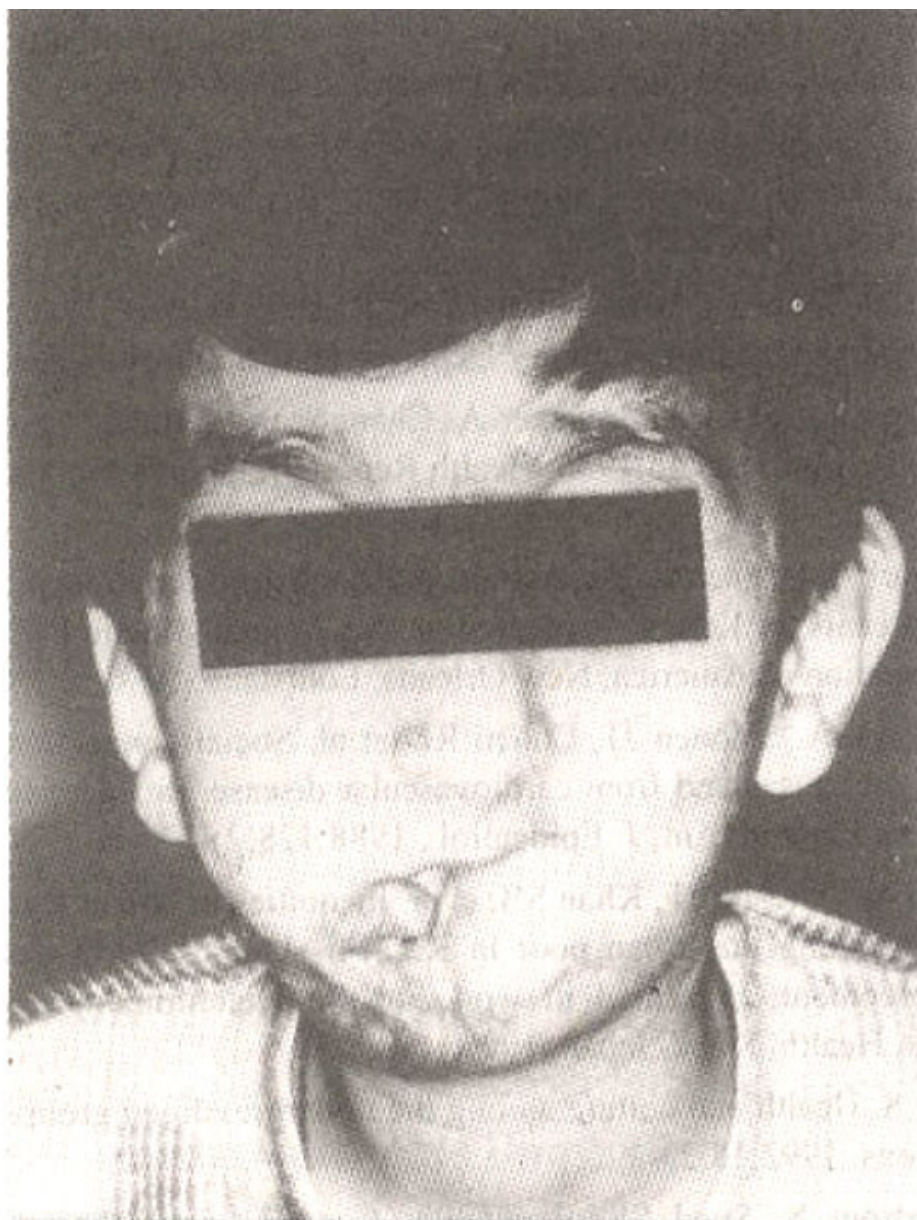


Figure 1. Congenital pain insensitivity involves the face as well, leading to repeated mutilation and severe disfiguration of the mouth

and stenotic with an oral cavity that was also deformed with a high palatal defect and fibrous adhesions of the tongue. He had hypodontia with severe malocclusion. His cardiovascular, respiratory and abdominal examination, including the genitalia was normal. There was traumatic amputation and scarring of digits on his hands (Figure 2)

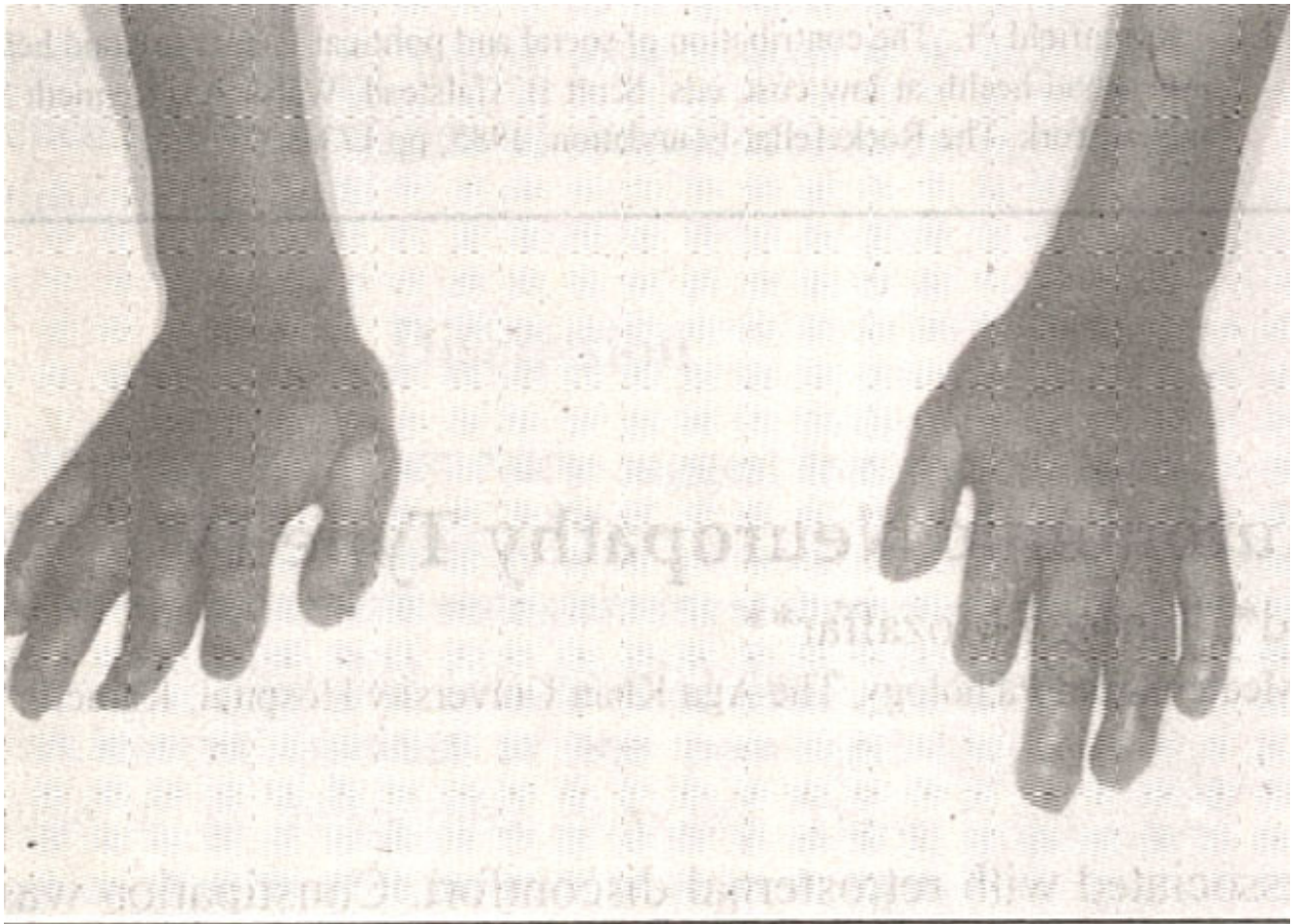


Figure 2. Pain insensitivity leading to auto-amputation of the digits.

and feet with extensive areas of ulceration, desquamation and scarring over the anterior shins and ankles. Both ankle joints were deformed, edematous and hypermobile. Neurological examination was significant for severe sensory loss to pinprick and temperature. Deep tendon reflexes were intact. There was no mental retardation.

Barium swallow with follow through showed the presence of a stricture at the distal one third of the oesophagus, with esophageal dysmotility and a hiatal hernia. Basic investigations including a complete blood count, serum electrolytes, blood urea nitrogen and creatinine were normal. Autoantibodies (anti-nuclear, anti-smooth muscle and anti-mitochondrial) were negative. Chest X-ray showed normal pulmonary and cardiac shadows. Electrodiagnostic testing revealed normal motor and sensory nerve conductions, including H-reflexes. Even though sympathetic skin responses were not done, the study suggested normal large fiber sensory and motor functions and raised suspicion for a pure “small fiber” (A6 and unmyelinated C fiber) involvement.

The stricture was considered to be secondary to gastroesophageal reflux and dilation followed by fundoplication was planned to prevent stricture recurrence. Endotracheal intubation was very difficult because of the distorted oral anatomy, a feature that also precluded endoscopic dilation of the esophageal stricture. Dilatation of the stricture was performed using a 12 F Nelaton catheter to facilitate insertion of a guide wire under fluoroscopic guidance. An antegrade esophageal dilatation was then done using Savory Gillard Dilators (Wilson Cook Medical Inc, Salem NC). Dilatation was repeated after an interval of three weeks and was successful in alleviating the discomfort and dysphagia. A fundoplication was planned to prevent gastroesophageal reflux and recurrence of the stricture.

Patient 2: Three year old female sibling of patient I who suffered from similar symptoms of repeated

episodes of hyperthermia, anhidrosis, insensitivity to pain and temperature and mutilating acral injury. She had frequent cutaneous ulceration and infections but had greater freedom of movement and ambulation as compared to patient I. Autonomic dysfunction was evident by drooling and feeding difficulties. There was no developmental delay or mental retardation.

Discussion

The purpose of this report is to highlight features of HSAN IV and to elucidate the supportive measures that are necessary to ensure prolonged survival and quality of care in these patients. The two patients described above had a recessively inherited insensitivity to pain combined with anhidrosis. The differential diagnosis includes hereditary sensory and autonomic neuropathies and Tangier disease. Normal motor and sensory nerve conductions preclude Tangier and the first 3 types of hereditary sensory autonomic neuropathies (Type I-III). The presence of anhidrosis similarly, would exclude type V HSAN (congenital insensitivity to pain without anhidrosis; CIPA).

Swanson et al, described 2 brothers with congenital insensitivity to pain and anhidrosis (despite normal appearing sweat glands on skin biopsy)^{3,4}. Temperature sensation was also defective. One, of the brothers died after a 24-hour illness during which his temperature reached 109° F. Almost complete absence of the first order afferent system considered responsible for pain and temperature was found at autopsy⁵. Pinsky and DiGeorge, Wolfe and Henkin and Vassella et al. Subsequently reported similar cases⁶⁻⁸. Sweating could not be elicited by thermal, painful, emotional or chemical stimuli. Histamine evoked no axon flare. Subcutaneous administration of mecholyl or neostigmine in doses capable of producing lacrimation in normal children, failed to do so in these patients, despite their occasional spontaneous lacrimation. Rafel et al, studied the cutaneous branch of the radial nerve by electron microscopy and found complete absence of small myelinated and unmyelinated fibers⁹. They concluded that this is not a sensory neuropathy but a developmental abnormality. Some of these cases have been incorrectly diagnosed as dysautonomia or Biemond congenital and familial analgesia. Ishii et al. Described an affected Japanese girl who after the establishment of dentition bit off the apical part of her tongue and began self-mutilating her lips and the tips of her fingers¹⁰. Courtney and Freedenberg described a patient that appeared to have HSAN-IV but did not have developmental delay¹¹.

Roseberg's review demonstrated that 20% of the patients succumbed to hyperpyrexia, most of them before age three¹². Most of the children were mentally retarded, with IQs varying from 41 to 78, the majority being in the 60s.

Gastrointestinal manifestations such as feeding difficulties due to autonomic dysfunction have been reported, however, this is the first report of an esophageal stricture presenting with dysphagia in such patients. The autonomic dysfunction contributed to ineffective peristalsis and the development of reflux associated strictures of the distal esophagus in our patient. Successive esophageal dilatation, acid suppressive therapy and measures to reduce gastroesophageal reflux with prokinetic drugs and possible surgery were the aims of therapy.

Other features reported in patients with hereditary sensory autonomic neuropathy include, acro-osteolysis, trophic changes, cutaneous pustules and ulcers, self mutilation secondary to the lack of pain and temperature sensation, multiple fractures and hypohidrotic skin⁵. Genetic defect underlying HSAN IV has been discovered recently, initially in mice and subsequently in human patients with this form of hereditary neuropathy. Three different mutations (a deletion, a splice-site aberration and missense mutation) in the tyrosine kinase domain of TRKA, the receptor for nerve growth factor (NGF), have been characterized^{13,14}. These findings strongly suggest that the NGF-TRKA system has a crucial role in the development and function of the nociceptive reception system as well as establishment of thermal regulation via sweating in humans.

The case reported has features that fit this syndrome. A nerve biopsy was not possible as skin over the sural nerve is severely inflamed and ulcerated at the time. Mental retardation was not grossly obvious although formal IQ testing was not done. His acral deformities requires special orthotic devices for support and physiotherapy was instituted. Nutritional support was required as well, especially during the time of surgical correction of his esophageal stricture. The parents were educated about the symptoms and implications of the disease. An active search was made for afflicted siblings and other family members as well.

References

1. Reilly MM. Genetically determined neuropathies. *J. Neurol.*, 1998;245:6-13.
2. McDougall AJ, McLeod JG. Autonomic neuropathy, II: Specific peripheral neuropathies. *J. Neurol. Sci.*, 1996;138:1-13.
3. Swanson AG, Buchan GC, Alvord EC. Absence of Lissauer's tract and small dorsal root axons in familial, congenital, universal insensitivity to pain. *Trans. Am. Neurol. Assoc.*, 1963;88:99-103.
4. Swanson AG, Buchan GC, Alvord EC. Anatomic changes in congenital insensitivity to pain. Absence of small primary sensory neurons in ganglia, roots and Lissauer's tract. *Arch. Neurol.*, 1965;12:12-18.
5. Swanson AG, Congenital insensitivity to pain with anhidrosis: A unique syndrome in two male siblings. *Arch. Neurol.*, 1965;8:299-306.
6. Pinsky L, DiGeorge AM. Congenital familial sensory neuropathy with anhidrosis. *J. Pediatr.*, 1966;68:1-13.
7. Wolfe SM, Henkin RI. Absence of taste, in type II familial dysautonomia: Unresponsiveness to methacholine despite the presence of taste buds. *J. Pediatr.* 1970;77:103-108.
8. Vassella F, Emrich HM, Kraus-Ruppert R, et al. Congenital sensory neuropathy with anhidrosis. *Arch. Dis. Child.*, 1968;43: 124-130.
9. Rafel E, Alberca R, Bautista J, et al. Congenital insensitivity to pain with anhidrosis. *Muscle Nerve*, 1980;3:2 16-20.
10. Ishii N, Kawaguchi H, Miyakawa K, et al. Congenital sensory neuropathy with anhidrosis. *Arch. Dermatol.*, 1988;124:564-66.
11. Courtney KB, Freedberg DL. A new variant of hereditary sensory neuropathy type IV: Anhidrosis, pain sensitivity and normal intelligence. *Am. J. Hum. Genet.*, 1990;47 (suppl):A53.
12. Rosenberg S, Nagahashi Marie SK, Kliemann S. Congenital insensitivity to pain with anhidrosis (hereditary sensory and autonomic neuropathy type IV). *Pediatr. Neurol.* 1994; 11:50-56.
13. Smeyne RJ, Klein R, Schnapp Act al. Severe sensory and sympathetic neuropathies in mice carrying a disrupted Trk/NGF receptor gene. *Nature*. 1994;368:246-49.
14. Indo Y, Tsuruta M, Hayashida Y. et al. Mutations in the TRKA/NGF receptor gene in patients with congenital insensitivity to pain with anhidrosis. *Nature Genet.*, 1996;13:485-88.