

Role of endovascular treatment in vascular injuries

Muhammad Misbah Tahir, Tanveer-ul-Haq

Department of Radiology, Aga Khan University Hospital, Karachi, Pakistan.

Corresponding Author: Tanveer-ul-Haq. Email: tanveerhaq@aku.edu

Abstract

Objective: To evaluate retrospectively the results, complications and follow-up of patients after endovascular treatment of vascular injuries.

Methods: Fifty transcatheter embolisation procedures (TCE) were performed in 46 patients between 1999 and 2008 at the Aga Khan University Hospital, Karachi. Injuries in 14 (30.4%) patients were due to road traffic accident; iatrogenic in 13 (28%); accidental in 6 (13%). Firearms, bomb blasts and earthquake contributed to injuries in 8(17%), 4(8.8%) and 1(2.2%) patients respectively. All patients underwent angiography and had evidence of either active haemorrhage, pseudo-aneurysm, abnormal vascularity or arteriovenous fistula. Follow-up ranged from 1 day to 6 years with mean of 10.5 months. Medical record files, lab results and imaging reports were utilised for the study.

Procedure was declared as technically successful when there was cessation of extravasation, occlusion of fistula or exclusion of pseudo-aneurysm in the post-embolisation angiograms. Treatment was deemed clinically successful if there was resolution of the indication for which the procedure was done.

Results: Transcatheter embolisation was technically successful in occluding vascular lesions in all 46 (100%) patients. Lesions recurred in 4 (9%) patients who underwent initially successful TCE. These patients were treated effectively with repeated TCE. Three patients died during the same hospital stay and 3 patients died after being discharged from the hospital. All these patients were treated successfully with TCE and had factors other than TCE contributing to their mortality.

Conclusion: Transcatheter embolisation for vascular injuries was found to be a satisfactory procedure, with low morbidity and mortality rates.

Keywords: Transcatheter embolisation, Endovascular treatment, Vascular injuries (JPMA 62: 470; 2012).

Introduction

Vascular trauma is a challenging issue for the surgeons requiring effective and quick team work. Time delay and inappropriate management can result in significant morbidity and mortality. Worldwide bombings, civilian landmine injuries, and combat-related injuries are becoming more common, and most physicians are expected to encounter these patients at some point or the other in their careers.

Transcatheter repair takes preference over surgical repair in vascular trauma because of several aspects. There is decrease in morbidity and mortality, especially when there is coexisting large haematoma, pseudo-aneurysm or arteriovenous fistula.¹⁻⁵

Intraluminally placed stents and stent grafts designed to bridge traumatic lesions as well as various types of more traditional occlusive devices, such as balloons, coils and other thrombogenic materials, can be used for transcatheter embolisation. The retrospective study reviewed the endovascular management of patients with vascular trauma presenting at Aga Khan University Hospital, Karachi,

between 1999 and 2008. There were 46 patients reporting with a variety of complex or inaccessible vascular injuries who were treated successfully, emphasising the utility of the endovascular approach. Cases were performed according to the institutional guidelines and protocols with interventional radiologist and doctors from surgical and medical specialties working in collaboration as a team.

Patients and Methods

It was a retrospective descriptive study carried out at the AKU Department of Radiology. The archives of the angiography suite were used to identify all patients who had undergone TCE for vascular injuries at the interventional radiology section between January 1999 and May 2008. Being retrospective in nature, the study did not require the approval of the institutional review board.

In all cases, the patients had been fully briefed about the procedure and only offer their informed consent, basic laboratory investigations had been performed before performing TCE. These included complete blood count with platelet counts, serum creatinine, electrolytes, prothromin

time and activated partial thromboplastin time. For stent graft procedures, Aspirin 325 mg/day was started at least 3 days before the procedure and was advised to be continued indefinitely. In addition, Clopidogrel 300 mg was given a day prior and 75 mg a day to be taken for 6 weeks post-procedure (Figure 1-A,B).

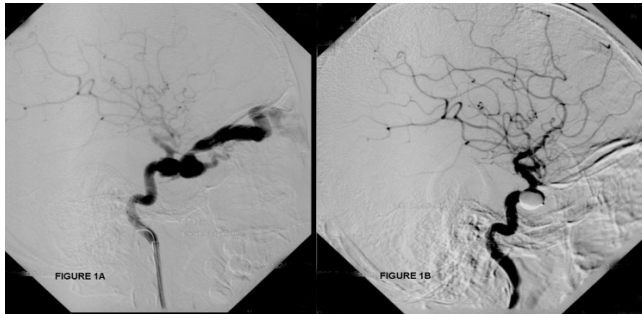


Figure-1: A) Digital subtraction angiogram of right internal carotid artery showing mature traumatic direct right carotocavernous fistula. B) Successful detachable balloon embolization of right carotocavernous fistula.

Selective digital subtraction angiography was performed by transfemoral approach. Catheter was manoeuvred into a more distal position with guide wire after the source of bleeding was identified. In majority of cases a 3-F super selective coaxial catheter (Progreat Terumo Japan) had been introduced coaxially in proximity to the bleeding branch. Coils (Boston Scientific U.S.A) (Cook U.S.A), Poly Vinyl Alcohol particles (PVA) (Cordis Johnson and Johnson U.S.A) Gel foam (Gelita Medical BV Netherlands), detachable balloons (Minvasys France) and Cyanoacrylate glue (Histoacryl, B.Braun Germany) were used alone or in combination for embolisation. In cases of stenting, guide wire was placed through the diseased segment of the vessel and self-expanding polytetrafluoroethylene (PTFE) covered stents (Boston Scientific U.S.A) were deployed to exclude the pseudo aneurysm. All embolisation procedures had been performed by interventional radiologists who had 5-15 years of experience with intra-arterial catheter embolisation techniques. Follow-up consisted of radiological and clinical assessment and ranged from 1 day to six years with a mean of 10.5 months. Medical record files, lab results, imaging reports were utilised for the purpose of this study.

Fifty TCE procedures were performed in 46 patients between January 1999 and May 2008. Thirty-eight (83%) of the patients were male and 8 (17%) were female. Their ages ranged from 13 to 79 years (mean 37years). Injuries involved predominantly head and face in 17 (37%) patients, pelvis in 9 (19.6%), extremities in 5 (10.9%), kidneys in 12 (26.1%), and liver and thorax in 1 (2.2%) patient each. One (2.2%) patient presented with polytrauma.

The lesions encountered included 16 post-traumatic

extravasations, 10 pseudo-aneurysms, 12 arteriovenous fistulas (AVFs), 6 AVFs and false aneurysms occurring together, and 2 cases of abnormal vascularity (hyperemia). Most injuries were encountered in renal arteries (Table).

Table: Arteries embolized by names & number.

| Name of artery | No. of Patients |
|-------------------------|---|
| Renal | 14 |
| Internal iliac | 6 |
| Internal pudendal | 3 |
| Common iliac | 2 |
| External iliac | 1 |
| Common femoral | 2 |
| Internal carotid | 11 including 9 carotid cavernous fistulas |
| External carotid | 4 |
| Common carotid | 2 |
| Hepatic artery | 1 |
| Ascending aorta | 1 |
| Anterior tibial artery | 1 |
| Posterior tibial artery | 1 |

Injuries in 14 (30.4%) patients were due to road traffic accident. Four of them with pelvic fractures were unstable with extravasations from branches of iliac artery. Transcatheter embolisation was performed effectively in these patients with coils, poly vinyl alcohol and Gelfoam. Two patients suffered renal injuries resulting in avulsion of interpolar branches of renal artery and arteriovenous malformation. They were managed successfully with coil embolisation.

Firearms, bomb blasts contributed to injuries in 8 (17.4%) and 4 (8.7%) patients respectively. Two patients had injury to common iliac artery resulting in development of arteriovenous fistulae and pseudo-aneurysms which were excluded successfully with covered stents. One gunshot victim had extravasation from the branch of right hepatic artery resulting in haemobilia. He was cured with coil embolisation of the bleeding vessel. One bomb blast victim developed AVF between internal jugular vein and internal carotid artery which was occluded uneventfully with coil embolisation.

Injuries in 13 (28.3%) patients were Iatrogenic. Two of these 13 had common femoral artery pseudo-aneurysms and were treated with covered stents. One of them had excision of inguinal lymph node and radiotherapy while the other was intravenous drug abuser. Another patient developed pseudo-aneurysm of common carotid artery as a complication of Joe catheter insertion and was treated with combination therapy involving covered stent, coil and glue embolisation (Figure-2 A-B). Five patients had vascular injuries following pyelolithotomies. Pseudoaneurysms were noted in 3 cases and extravasation was detected in 2. These lesions were treated with coil embolisation. Two patients developed gross

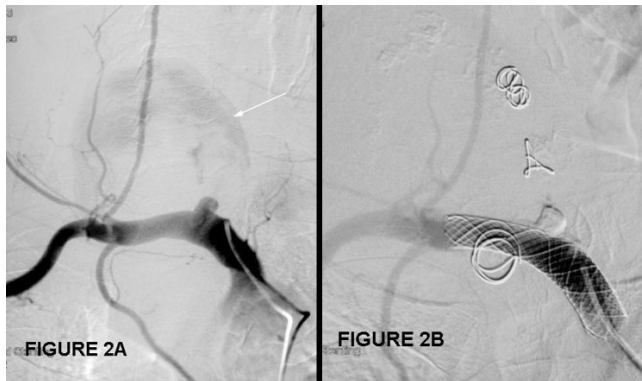

Figure-2: A) Right brachiocephalic artery digital subtraction angiogram showing common carotid stump filling large pseudo aneurysm. (Arrow) and non-filling of the distal common carotid artery and its branches. This is an iatrogenic injury following central line placement. B) Successful embolization with self expanding metallic stent, coils and histoacryl glue resulting in complete exclusion of the pseudo aneurysm.

haematuria following transplantation of kidneys. Pseudo-aneurysm and arteriovenous fistula was detected in one patient, which was taken care of with balloon and coil embolisation. The other had extravasation which was treated with coil embolisation. Another coronary artery bypass graft (CABG) patient developed pseudoaneurysm of ascending aorta during surgery and was immediately shifted to the angiography suite where pseudo-aneurysm was excluded with detachable coil embolisation. Active extravasation was noted in a patient following renal biopsy. He was embolised successfully with coils, but could not recover from the shock and died during the same hospital stay.

Six (13%) patients had accidental vascular injuries. One of them developed priapism due to pseudo-aneurysm and arteriovenous fistula of internal Pudendal artery. He was treated with poly vinyl alcohol particles and coil embolisation. Another patient had suicidal attempt with knife resulting in pseudo-aneurysm in the left proximal internal carotid artery. He was treated with a covered stent.

One (2.2%) patient had head injury due to earthquake, resulting in caroto-cavernous fistula and pseudo-aneurysm of the internal carotid artery. Balloon embolisation was performed with occlusion of fistula and pseudo-aneurysm along with good cross-flow preserving the cerebral circulation.

Radiologic records and patient charts were reviewed by two of the researchers together to extract information about the technical and medical success of the procedure, and technical and medical complications. Technical success of the procedure was defined as complete occlusion of bleeding, pseudo-aneurysm or AVF with arterial embolisation as documented with arterial angiography at the end of the procedure. Medical success was defined by the disappearance of indication for which embolisation was performed like the

absence of recurrent haematuria, absence of recurrent need for erythrocyte administration, absence of recurrent decrease of haemoglobin by more than 1.5 g/dL (15 g/L), and absence of need for angiographic re-embolisation or subsequent surgery.

Results

Transcatheter embolisation (TCE) was technically and clinically successful in occluding vascular lesions in all 46 (100%) patients. Lesions recurred in 4 patients. Three patients had recurrence of the carotid cavernous fistula (CCF), while one patient had recurrence of leg arteriovenous fistula (AVF). These patients were treated effectively with repeated TCE.

In one patient there was dislodgment of coil in the profunda femoris artery without any clinical consequences while attempting embolisation of branches of the external iliac artery. No other angiographic embolisation-related complications were encountered.

Of the total, 43 patients survived to be discharged from the hospital. Three patients died during the same hospital stay. One patient had a fall from the sixth floor and had bled profusely before being brought to the angiography suite. He died of multi-organ failure after being treated successfully for vascular injuries. Another patient, who had road traffic accident, died of intracranial haemorrhage after being treated for pelvic bleed. The third patient had post-renal biopsy bleed and was brought in shock. He was treated successfully with embolisation of the renal artery, but could not recover from the shock and died five days later. Three patients had died after being discharged from the hospital. All these patients were treated successfully with TCE and had other concomitant diseases like chronic renal failure, scrotal carcinoma and cirrhosis which contributed to their death.

Six patients had been treated with covered metallic stents. No stent occlusion or infection was noted in our study. The longest stent patency interval noted in the study was six years.

Discussion

Endovascular management of patients with traumatic vascular lesions is an attractive conception with the facility of diagnosis and treatment in the same session along with relatively easy access to difficult locations like the base of the skull, infraclavicular region and the pelvis.

Vascular injuries can be treated with transcatheter embolisation by stent grafts, occlusive intervention devices and combination therapy. For the exclusion of a vascular lesion, stent graft is used. It is made of an impermeable endoluminal graft supported by a metallic stent.

One of the largest studies describing the repair of carotid injury with stent graft deployment was carried out at

the Montefiore Medical Center.⁶ In the initial phase of the study six pseudo-aneurysms and one arteriovenous fistula were treated with seven stent grafts. All the stent grafts were deployed successfully with 100% patency at a mean follow-up of 6.5 months. A subsequent report defined the outcome following the repair of six subclavian artery injuries.⁷ All endografts were patent at a mean follow-up interval of 19 months. No stent occlusion was noted in our retrospective, and the study longest patency interval noted was six years.

One of the complications of stent graft is infection though it has not been clearly described. In our series, no case of stent graft infection was found.

In vessels that can be occluded completely without clinical consequences, TCE can be performed with mechanical devices, polymeric solid biomaterials and liquid adhesives. Balloon occlusion has become an accepted modality of treating traumatic carotid-cavernous fistulas (CCF).^{8,9} Our study found that six cases of CCF had been successfully treated with transcatheter detachable balloon occlusion. In 3 of these cases, only micro coils were used as the embolising material. One patient with traumatic AVF of the left leg, and another patient with transplanted kidney and iatrogenic injury to a branch of renal artery resulting in pseudo-aneurysm and AVF formation, were also treated successfully treated with balloon and coil occlusion. All these balloons were placed within the fistula without compromising the arterial lumen.

One of the very important occlusive modalities for the management of endovascular trauma is coil embolisation.¹ In our series, coils were the only embolising agents in 23 of 50 TCE procedures. Gelfoam was used primarily for the temporary control of bleeding before surgical intervention.^{10,11} In two cases, we noticed the use of Gelfoam; one with nasal bleed, and the other with internal iliac artery bleed. PVA expands up to 15 times in length after coming in contact with blood, making it ideal for occlusion when the catheter can be placed closed to the area of injury in selected cases

Histoacryl glue is an important tool of occlusive endovascular management. It is a liquid adhesive material which rapidly polymerises after coming in contact with the blood. It can be used effectively to supplement balloon occlusion. In a patient with AVF of posterior tibial artery,

our study noted the use of combination of glue and balloon successfully. In another patient with pseudo-aneurysm of the common carotid artery, a combination of Histoacryl glue, coils and covered stent had been used for the exclusion of pseudo-aneurysm.

Conclusion

The retrospective review of data revealed satisfactory results in patients treated with transcatheter embolisation for vascular injuries. TCE has replaced surgery in curing carotid-cavernous fistulas. It is the preferred modality for treating lesions at sites difficult to approach by conventional surgery. It also becomes the treatment of choice in patients where surgery is contraindicated because of patient factors like deranged coagulation profile or inability to endure general anaesthesia. It also decreases the hospital stay of patient.

Acknowledgement

We thank all our teachers, especially Dr Azeemuddin, for their encouragement, help and cooperation.

References

1. Cook RE, Keating JF, Gillespie I. The role of angiography in the management of haemorrhage from major fractures of the pelvis. *J Bone Joint Surg Br* 2002; 84: 178-82.
2. Weiss VJ, Chaikof EL. Endovascular treatment of vascular injuries. *Surg Clin North Am* 1999; 79: 653-65.
3. Nicholson AA. Vascular radiology in trauma. *Cardiovasc Intervent Radiol* 2004; 27: 105-20.
4. Dinkel HP, Danuser H, Triller J. Blunt renal trauma: minimally invasive management with microcatheter embolization experience in nine patients. *Radiology* 2002; 223: 723-30.
5. Qasim ZA, Masood R, Mateen MA. Successful use of angiographic embolisation to control haemorrhage from blunt pelvic trauma in a pediatric patient. *J Pak Med Assoc* 2004; 54: 32-3.
6. Ohki T, Veith FJ, Marin ML, Cynamon J, Sanchez LA. Endovascular approaches for traumatic arterial lesions. *Semin Vasc Surg* 1997; 10: 272-85.
7. Patel AV, Marin ML, Veith FJ, Kerr A, Sanchez LA. Endovascular graft repair of penetrating subclavian artery injuries. *J Endovasc Surg* 1996; 3: 382-8.
8. Bavinzski G, Killer M, Gruber A, Richling B. Treatment of post-traumatic carotico-cavernous fistulae using electrolytically detachable coils: technical aspects and preliminary experience. *Neuroradiology* 1997; 39: 81-5.
9. Lewis AI, Tomsick TA, Tew JM Jr. Management of 100 consecutive direct carotid-cavernous fistulas: results of treatment with detachable balloons. *Neurosurgery* 1995; 36: 239-44.
10. Hieshima GB, Grinnell VS, Mehringer CM. A detachable balloon for therapeutic transcatheter occlusions. *Radiology* 1981; 138: 227-8.
11. Katzen BT, Rossi P, Passairello R, Simonetti G. Transcatheter therapeutic arterial embolisation. *Radiology* 1976; 120: 523-31.