

Adult laryngeal haemangioma; a rare entity

Shabbir Akhtar,¹ Adeel Ahmed Shamim,² Shehzad Ghaffar,³ Muhammad Sheryar Ahmed,⁴ Mubasher Ikram⁵
 Department of Surgery,^{1,3-5} Medical Student,² Aga Khan University Hospital, Karachi, Pakistan.

Abstract

Laryngeal haemangioma is commonly seen in children. Adult laryngeal haemangiomas are rare and usually involve the supraglottic region. Most common symptom includes dysphagia, dysphonia and shortness of breath. Detailed history, fiberoptic laryngoscopy and computerized scanning may suggest benign nature of the lesion but diagnosis is only confirmed by a biopsy. In comparison to infantile haemangiomas which usually respond to propranolol, the treatment of adult laryngeal haemangiomas is always surgical removal. We present a case report of a supraglottic haemangioma in an adult male, who was treated surgically without any complications.

Keywords: Laryngeal haemangioma, Fiberoptic laryngoscopy, Computerized scanning.

Introduction

Benign neoplasm's of the larynx are infrequent, about 95% of the benign neoplasm's are papillomas and left over 5% comprise of oncocyctic tumours, pleomorphic adenomas, lymphangiomas, neurofibromas, fibromatosis, paragangliomas, rhabdomyomas and haemangiomas.¹ Accordingly, haemangioma in the larynx is a very uncommon occurrence, especially in an adult. Symptoms associated with this benign tumour are not diagnostic and mostly are related to the obstruction caused by the neoplasm. Patients may present with dysphonia, dyspnoea, and dysphagia. Most of the time (in 80% cases) supraglottic region is involved, followed by glottis and subglottis.¹ A thorough history and complete examination are imperative for diagnosis; however it must be confirmed by radiological imaging and biopsy. Although a biopsy would result in bleeding, differentiating a benign from malignant neoplasm is crucial, as the latter is associated with significant morbidity and mortality. We present a case report of a rare benign supraglottic haemangioma in an adult male, who was treated surgically without any complications.

Case Report:

A 61-year-old male, weighing 64 kg presented to our clinic, complaining of dyspnoea and dysphagia (both for liquids and solids). The symptoms had been progressively

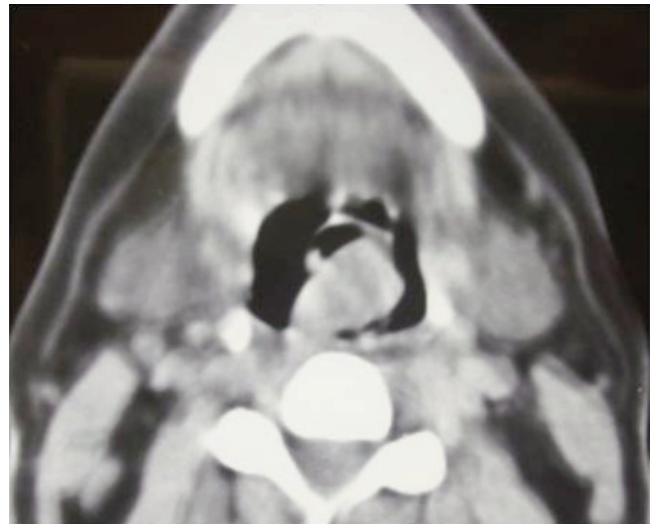


Figure-1: C T scan (axial view) showing mass involving supraglottis.

increasing in severity for the past one month. The patient was a cigarette smoker for the past 30 years (1 pack year) and was also addicted to paan (tobacco) and chalia (betel nut).

General physical examination of the patient revealed a respiratory rate of 22 breaths/minutes, otherwise he was vitally stable. On fiberoptic nasolaryngoscopic examination, right sided exophytic growth was seen involving supraglottic region and occluding the airway. Vocal cords were not visible because of the mass. Patient brought a CT scan film which showed a growth arising from right aryepiglottic fold. Patient was scheduled for emergency tracheostomy and direct laryngoscopy.

Tracheostomy was performed under local anaesthesia followed by direct laryngoscopy. A large protruding mass was noted on arising from right aryepiglottic fold extending into the hypopharynx. A biopsy, measuring 1.5 x 0.8 x 0.3 cm, was taken. This resulted in profuse bleeding, which raised the suspicion of a vascular tumour. Haemostasis was achieved with the help of monopolar suction cautery. Biopsy report showed irregular grey and brown soft tissue showing underlying vascular lesion which was composed of capillary sized channels. There was increased expression of endothelial cell markers CD34 and Cytokeratin was negative. These

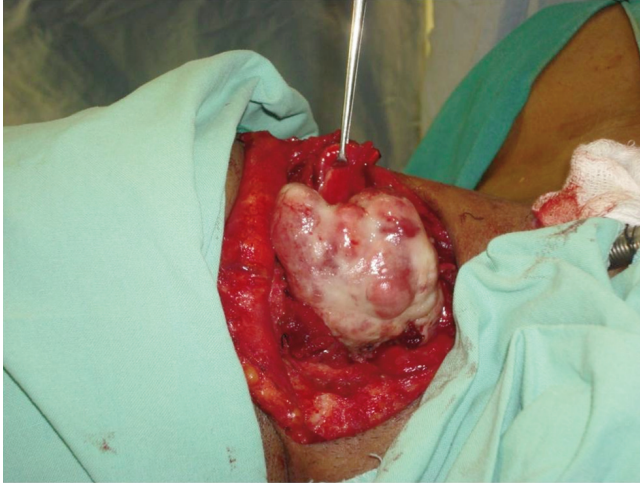

Figure-2: Intraoperative view showing the mass still attached to the larynx.

findings favoured a vascular lesion most likely haemangioma. Two weeks later, the patient was scheduled for excision of the supraglottic neoplasm.

We used a transhyoid vallecular approach for excision of the neoplasm. The larynx was exposed as per protocol i.e. horizontal skin incision, sub-platysmal flap raised, strap muscles divided in midline to expose the larynx. Thyrohyoid membrane was then divided in the midline and thyroid cartilage was split at ridge only. Hyoid bone was also divided in the midline to provide easy access into the laryngeal cavity (Figure-1). Epiglottis was identified and the tumour removed by blunt dissection and ligation of the stump. The whole mass measuring 5 x 4.5 x 4 cm, was removed in one piece (Figure-2). Once haemostasis was ensured, the larynx was closed in layers.

Post-operative stay at the hospital was unremarkable and patient was discharged on 4th post-operative day and is being followed up. Histopathology report that followed, confirmed lobular capillary haemangioma.

Discussion

Incidence of laryngeal haemangioma in adults is unknown due to the scarcity of case reports and case series;

in contrast the incidence in infants is 4-5%.² Pathogenesis is pertinent to the imbalance of positive and negative vasculogenic factors culminating in proliferation of the haemangioma.³ Generally, haemangiomas undergo expansion (proliferative phase) in the first 5 months of life, this is followed by regression (involution phase) of the lesion.^{4,5} When the lesion fails to involute, a persistent haemangioma results and forms the platform for uninhibited proliferation. Another theory is that it responds to oestrogen and progesterone hormones, thus increasing in size during pregnancy and decreasing postpartum.⁶

CO₂ laser excision is the treatment of choice. Previously, Nd:YAG laser and cryotherapy were also utilized.^{7,8} Lucioni et al. successfully treated 5 out of 6 patients with supraglottic haemangioma via CO₂ laser but had one persistent neoplasm.⁹ Recurrence of haemangioma signifies an incomplete excision. Laser has favourable outcome with superior conservation and restoration of laryngeal function. However, where laser facilities are lacking then surgery is indicated, with the surgical approach being governed by the location and extent of the growth.

References

1. Grant DG, Birchall MA, Bradley PJ. Surgery for Benign Tumors of the Adult Larynx. In: Remade M, Eckel HE, eds. Surgery of Larynx and Trachea, Berlin, Heidelberg: Springer, 2010; pp 91-111.
2. Kiline, C, Frieden, IJ. Infantile hemangiomas: how common are they? A systematic review of the medical literature. *Pediatr Dermatol* 2008; 25: 168.
3. Bielenberg DR, Bucana CD, Sanchez R, Mulliken JB, Folkman J, Fidler IJ. Progressive growth of infantile cutaneous hemangiomas is directly correlated with hyperplasia and angiogenesis of adjacent epidermis and inversely correlated with expression of the endogenous angiogenesis inhibitor, IFN-beta. *Int J Oncol* 1999; 14: 401-4.
4. Enjolras O, Mulliken JB. The current management of vascular birthmarks. *Pediatr Dermatol* 1993; 10: 311.
5. Chang LC, Haggstrom AN, Drolet BA, Baselga E, Chamlin SL, Garzon MC, et al. Growth characteristics of infantile hemangiomas: implications for management. *Pediatrics* 2008; 122: 360-7.
6. Brandwein MS, Abramson AL, Shikowitz MJ. Supraglottic hemangioma during pregnancy. *Obstet Gynecol* 1987; 69(3 Pt 2): 450-3.
7. Yellin SA, LaBruna A, Anand VK. Nd:YAG laser treatment for laryngeal and hypopharyngeal hemangiomas: a new technique. *Ann Otol Rhinol Laryngol* 1996; 105: 510-5.
8. O'Neill JV, Snyder GG 3rd, Toomey JM. Cryosurgery of supraglottic cavernous hemangioma. *Arch Otolaryngol* 1976; 102: 55-7.
9. Lucioni M, Marioni G, Della Libera D, Rizzotto G. Adult laryngeal hemangioma CO₂ laser excision. A single institution 3-year experience (Vittorio Veneto 2001-2003). *Acta Otolaryngol* 2006; 126: 621-6.