

## Asymptomatic presentation of giant bulla of the left apical and anterior segment of the left upper lobe of the lung with near complete atelectasis of the remaining left lung

Saulat Hasnain Fatimi,<sup>1</sup> Mahrukh Riaz,<sup>2</sup> Hashim Muhammad Hanif,<sup>3</sup> Marium Muzaffar<sup>4</sup>

Department of Surgery, Division of Cardiothoracic Surgery,<sup>1</sup> Medical College,<sup>2-4</sup> Aga Khan University, Karachi, Pakistan.

### Abstract

Giant bullae may be found in association with emphysema. They present as pockets of entrapped air which grow as the surrounding lung retracts away. As they do not take part in gas exchange and merely occupy space, their presence leads to severe impediment of mechanical ventilation in the adjacent lung parenchyma. Patients may present with dyspnoea, exercise intolerance and a feeling of pressure in the chest. The case of a 54 year old gentleman is presented, who was found to have a giant bulla occupying his left hemithorax on a routine chest X-ray. The patient remained asymptomatic despite the large size of the bulla and was treated with surgical resection via thoracotomy i.e. Bullectomy which is the treatment of choice. If left untreated the condition can be complicated by pneumothorax, infection and a slow progression to malignant changes.

**Keywords:** Giant bulla, Atelectasis.

### Introduction

A giant bulla is a large pocket of air occupying at least one third of the hemithorax.<sup>1</sup> These bullae arise as a result of disease processes like emphysema whereby areas of weakness develop within the lung and eventually reach a size at which they fill preferentially to the adjacent lung tissue. This is attributed to their 'paper bag' compliance making them easier to inflate than normal lung up to a certain volume.<sup>2</sup> The bulla enlarge as the surrounding tissue retracts away by elastic recoil.<sup>3</sup> The bullae do not participate in gas exchange and as they grow, this fact together with their space occupying nature increases the work of breathing with associated exercise limitation and dyspnoea.<sup>1</sup> Surgical bullectomy is the treatment of choice in patients with giant bullae occupying more than half of the hemithorax.<sup>4</sup> It has also been observed that patients with a preoperative FEV1 of approximately half the predicted value gain the most from bullectomy.<sup>2</sup> FEV1 is also the most reliable indicator of post-operative progress.<sup>5</sup> This is the case of a 54 year old asymptomatic gentleman with a giant bulla

occupying almost the entire left hemithorax who underwent successful surgical bullectomy with restoration of pulmonary function.

### Case Presentation:

A 54-year-old man was referred to the clinic/OPD for an abnormal finding in chest X-ray done for a routine physical checkup. His physical examination showed decreased air entry in the left lung. On evaluation with another chest X-ray, a large bulla occupying the left upper hemithorax was found. A CT Scan chest was obtained which showed a giant bulla occupying nearly the entire left hemithorax with compressive atelectasis to the left lung, with the risk of impending pneumothorax. It was decided to proceed with elective left upper lobe resection. Via left posterolateral thoracotomy, the left lung was exposed. A giant bulla was identified which was originating from

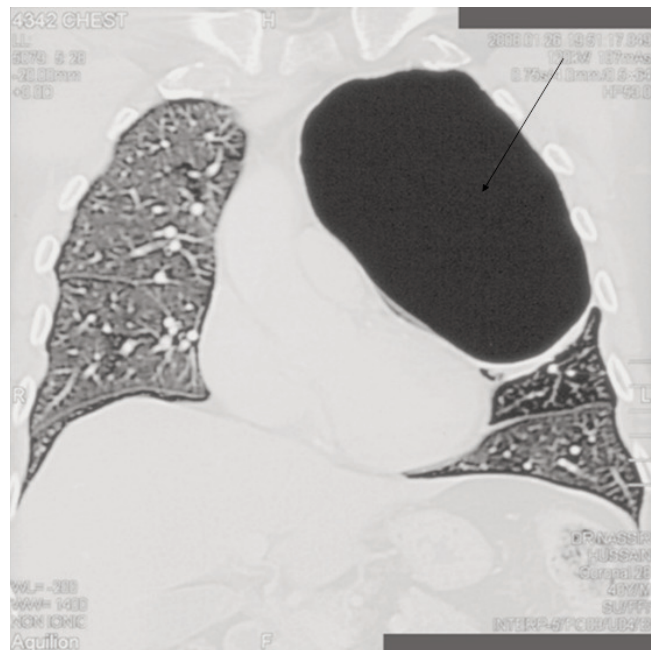


Figure: CT scan chest. Know depicting the bulla.

the apical and anterior segment of the left upper lobe. Segmental lung resection was then performed with Gastrointestinal Anastomosis (GIA) stapler. The remaining lung expanded well. Post-operative course was unremarkable.

### Discussion

Giant bullae often occur in association with emphysema. They increase the residual volume within the lung, and the residual volume to total lung capacity ratio, therefore they worsen the mechanical disadvantage of the respiratory muscles.<sup>6</sup> Symptoms include decreased exercise tolerance and dyspnoea. Resection of these bullae leads to marked improvement in pulmonary function by removing the redundant space occupying destructed emphysematous lung tissue.<sup>7</sup> In general, two main factors determine the postoperative outcome of a bullectomy: i.e. the size of the bulla and the condition of the underlying lung.<sup>2</sup> Patients with bullae occupying more than half of the hemithorax are good candidates for surgery.<sup>8</sup> Previously, it was believed that the presence of generalized emphysema in these patients was a bad prognostic indicator for surgery,<sup>2</sup> however, recent studies show that this may not be true as even small increments in breathing capacity may improve symptoms, exercise tolerance and quality of life in these patients.<sup>7</sup>

Surgical management of emphysematous bullae includes a wide variety of techniques namely local excision of the bullae, intra-cavitary drainage, placcation, stapler resection and lobectomy.<sup>6</sup> The approach used can

either be thoracotomy or video assisted thoracoscopy (VATS). Early mortality rates from bullectomy range from 0 to 0.25%. Post-operative complications include atrial fibrillation (12%), mechanical ventilation (9%), pneumonia (5%) and prolonged air leak of more than 7 days (53%).<sup>1</sup> Due to the significant morbidity and prolonged hospital stay associated with traditional surgical methods, newer less invasive techniques are now being considered.<sup>6</sup> The patient was diagnosed to have a giant emphysematous bulla in the left lung on routine chest X-ray. A lobectomy via thoracotomy was opted for and pulmonary function was restored without any further complications.

### References

1. Noppen M, Tellings JC, Dekeukeleire T, Dieriks B, Hanon S, D'Haese J, et al. Successful treatment of a giant emphysematous bulla by bronchoscopic placement of endobronchial valves. *Chest* 2006; 130: 1563-5.
2. Kinnear WJ, Tattersfield AE. Emphysematous bullae. *BMJ* 1990; 300: 208-9.
3. Morgan MDL, Edwards CW, Morris J, Matthews HR. Origin and behaviour of emphysematous bullae. *Thorax* 1989; 44: 533-8.
4. Palla A, Desideri M, Rossi G, Bardi G, Mazzantini D, Mussi A, et al. Elective surgery for giant emphysema: a 5-year clinical and functional follow up. *Chest* 2005; 128: 2043-50.
5. Pearson MG, Ogilvie C. Surgical treatment of emphysematous bullae: late outcome. *Thorax* 1983; 38: 134-7.
6. Bhattacharya P, Sarkar D, Nag S, Ghosh S, Roychoudhury S. Transbronchial decompression of emphysematous bullae: a new therapeutic approach. *Eur Respir J* 2007; 29: 1003-6.
7. De Giacomo T, Venuta F, Rendina EA, Della RG, Ciccone AM, Ricci C, et al. Video-assisted thoracoscopic treatment of giant bullae associated with emphysema. *Eur J Cardiothorac Surg* 1999; 15: 753-7.
8. Brenner M, Kayaleh KA, Milne EN, et al. Thoracoscopic laser ablation of pulmonary bullae: radiographic selection and treatment response. *J Thorac Cardiovasc Surg* 1994; 107: 883-90.