

## Ocular injuries in blast victims

Mumtaz Alam, Mustafa Iqbal, Akbar Khan, Sher Akbar Khan  
Department of Ophthalmology, Khyber Teaching Hospital, Peshawar.

### Abstract

**Objective:** To study the type and severity of ocular injuries in blast victims.

**Methods:** It was a descriptive case series. The study was conducted at the Department of Ophthalmology, Khyber Teaching Hospital and Iqbal Eye Clinic Peshawar from March 2010 to May 2011. Detailed history was taken and complete ocular examination was done. B-scan was done to know about any posterior segment pathology (when required). Digital X-ray orbit and/or computed tomography were done to rule out intraocular foreign body. The treatment and follow up varied according to the type and extent of eye injury.

**Results:** Total number of patients were 79, 78 (98.73%) males and 1 (1.26%) female. Mean age of patients was  $23.43 \pm 10.67$  years. Ocular injury was unilateral in 50 (63.29%) and bilateral in 29 (36.70%) patients. Forty-one (37.96%) eyes had closed globe injury and 67 (62.03%) had open globe injury. The most common type of injury was corneal/scleral perforation (48.14%) followed by vitreous haemorrhage (38.88%) and traumatic cataract (30.55%). The most commonly performed surgery was corneal/scleral repair (in 33 eyes). Final best corrected visual acuity (BCVA) improved in 56 (51.85%) eyes, remained unchanged in 49 (45.37%) eyes and worsened in 03 (2.77%) eyes.

**Conclusion:** Blast related ocular injuries are becoming increasingly common. In severely injured eyes the visual prognosis remains poor despite development of advanced microsurgical techniques and better methods of visual rehabilitation.

**Keywords:** Digital X-ray, Computed Tomography (CT), Ocular injuries (JPMA 62: 138; 2012).

## Introduction

Ocular injury is an important and potentially preventable cause of ocular morbidity.<sup>1</sup> Ocular injuries form approximately 5-10% of all ophthalmic hospital admissions in non-industrialized areas and 39-42% in the industrialized community.<sup>2</sup> Every year more than half a million potentially blinding ocular injuries occur globally. There are approximately 1.6 million people who go blind from eye injuries, 2.3 million with bilateral visual impairment and 19 million with unilateral visual loss world-wide; thus ocular trauma is the commonest cause of unilateral blindness.<sup>3</sup> In the United States approximately 2.5 million new eye injuries occur annually and around 40% of monocular blindness is due to eye trauma.<sup>4</sup> Eye injuries can be broadly divided into 2 groups i.e. closed globe and open globe. Closed globe injuries are divided into contusion and lamellar laceration. Open globe injuries are divided into rupture and laceration.<sup>5</sup> Etiologically ocular injuries can be classified into domestic, occupational, sports, road traffic accidents, iatrogenic, fights and assaults and war injuries.<sup>6</sup> Almost 100 years ago more than 70% of all serious ocular injuries occurred at the workplace.<sup>7</sup> In the 1960s and 1970s, road traffic accidents became the most common cause of serious ocular injury.<sup>8</sup> In the 1980s, sport and leisure activities became common causes of serious eye injuries.<sup>9-11</sup> The home is now the most common location for eye injuries.<sup>12</sup> However, bomb blast and battlefield ocular injuries are becoming increasingly common in different parts of the world.<sup>13-15</sup> In blast victims ocular injury may result from primary blast exposure. The blast effect shock wave propagates through the different medium of eyeball causing contusion and concussion injuries. Primary blast injury comprises non-penetrating mechanical injuries such as hyphema, globe rupture, subconjunctival haemorrhage, commotio retine and orbital fracture.<sup>16,17</sup> However, ocular trauma is most commonly the result of secondary blast effects, in which debris displaced by the blast causes physical trauma to the eye and/or orbit. Secondary blast injury comprises penetrating or blunt-force injury to any part of the eye or orbit; open globe injuries, lacerations of the lacrimal system and eyelids comprise the majority of injuries in this group.<sup>18,19</sup>

The spectrum of eye injuries in blast victims ranges from very mild, innocuous to extremely serious with potentially blinding consequences. The purpose of our study was to study the type and severity of ocular injuries in blast victims, so that a comprehensive plan could be made for proper management of these patients.

## Patients and Methods:

This prospective study was conducted at Ophthalmology Department of Khyber Teaching Hospital and

Iqbal Eye Clinic Peshawar, from March 2010 to May 2011. The study was done in collaboration with an organization which was working for people suffering from war injuries. All the patients were victims of bomb blast or mine blast, belonging to Afghanistan, Federally Administered Tribal Areas (FATA) and Swat. The patients were completely assessed by a team of physicians and surgeons and any serious systemic injuries were properly managed. Patients were then referred to us for the management of ocular injuries.

It was a descriptive case series study. Patients of all age groups and both genders, having blast-related injury to the eyeball were included in the study. Patients who had only ocular adnexal injury and those who did not come for follow up were excluded. Consecutive sampling technique was employed i.e. all the patients who met the inclusion criteria were studied.

The study was approved by the ethical review board of the institution. Informed (verbal) consent was taken from all the patients and written informed consent was taken from those who needed surgery.

All patients were evaluated for types of ocular injury and extent of damage. Detailed history was taken and complete ocular examination was done including assessment of best corrected visual acuity (BCVA) with a Snellen chart, assessment of pupillary reaction with torch and slit lamp examination (Takagi SM-70, Japan). Intraocular pressure (IOP) was checked with Perkin's tonometer MK2 (Clement Clarke, London), when feasible. Fundus examination was done with 90 diopter lens (Volk, USA) and/or indirect ophthalmoscope (Neitz, Japan). In those patients with poor or no view of fundus, B-scan ultrasonography was done with AB 5500+ A/B Scan (Sonomed, USA). In those with open globe injury, B-scan was performed after restoring the globe integrity. Digital X-ray orbit was done in all patients. In those with high suspicion of intraocular foreign body (IOFB), a CT orbit (2mm section) was undertaken.

Primary repair was done under general anaesthesia (GA), in emergency, in those with corneal or scleral perforation. Evisceration was performed in patients with shattered globe (where repair was not possible) or if there was globe perforation with endophthalmitis. Subsequent management and follow up varied according to the type and extent of eye injury. Complete ocular examination was conducted at each follow up. SPSS-10 was used for data analysis.

## Results

Total number of patients was 79, including 78 males (98.73%) and 1 female (1.26%). Age ranged from 5 to 60 years with a mean of  $23.43 \pm 10.67$  years. Age of the patients was  $\leq 10$  years in 6 (7.59%) patients, 11-20 years in 28 (35.44%), 21-30 years in 31 (39.24%), 31-40 years in 10

**Table-1: Type and number of eye injury.**

Type of injury	No of eyes (%)	Type of injury	No of eyes (%)
Corneal/Scleral perforation *	52 (48.14%)	Vitreous hemorrhage	42 (38.88%)
Cataract	33 (30.55%)	IOFB +	22 (20.37%)
Subconjunctival hemorrhage	22 (20.37%)	Corneal foreign bodies	19 (17.59%)
Corneal oedema	18 (16.66%)	Retinal detachment	16 (14.81%)
Increased IOP++	15 (13.88%)	Sealed perforation #	15 (13.88%)
Hyphema	13 (12.03%)	Retinal hemorrhages	08 (7.40%)
Endophthalmitis	08 (7.40%)	Macular scarring	06 (5.55%)
Corneal epithelial defect	01 (0.92%)	Corneal lamellar laceration	01 (0.92%)
Iridodialysis	01 (0.92%)	Optic atrophy	01 (0.92%)

\* — Including corneal perforation in 22 eyes, scleral perforation in 07 eyes and corneo-scleral perforation in 23 eyes.

+ — 21 eyes had posterior segment IOFB and 1 eye had anterior segment IOFB

++ — Increased IOP was due to topical steroids in 8 eyes, due to free lens matter in 2 eyes, due to peripheral anterior synechiae in 2 eyes, due to silicone oil in 2 eyes and due to angle recession in 1eye.

# — It was corneal in 03 eyes, limbal in 01 eye and scleral in 11 eyes.

**Table-2: Type and number of surgeries\*.**

Type of Surgery	No of Surgeries
Corneal/Scleral repair +	33
Evisceration	19
Vitrectomy ++	14
Cataract Extraction	12
Vitrectomy + Cataract extraction #	10
<b>Others</b>	
Removal of silicon oil	3
Trabeculectomy	1
Opening of peripheral iridectomy	1
Pupilloplasty	1
Corneal autograft	1
Corneal autograft + Cataract extraction	1
Amniotic membrane graft	1
Removal of FB from limbus	1
Total	98

\* — In46 eyes 1 surgery was performed, in 14 eyes 2 surgeries were performed, in 06 eyes 3 surgeries were performed and in 01 eye 4 surgeries were performed.

+ — Including corneal repair in 21 eyes, scleral repair in 7 eyes and corneo-scleral repair in 5 eyes; IOFB removal was done in 1 eye.

++ — With IOFB removal in 5 eyes

# — With IOFB removal in 6 eyes.

(12.65%), 41-50 years in 2 (2.53%) and 51-60 years in 2 (2.53%) patients. The interval between the time of injury and presentation to ophthalmologist ranged from 1 to 10 days in 44 patients (60 eyes) and was more than 10 days in 35 patients (48 eyes). Ocular injury was unilateral in 50 (63.29%) patients and bilateral in 29 (36.70%) eyes. Forty-one (37.96%) eyes had closed globe injury and 67 (62.03%) had open globe injury. Of these 67 eyes, 25 (37.31%) had zone I injury, 6 (8.95%) had zone II injury and 36 (53.73%) had zone III injury. The most common type of injury was corneal/scleral perforation (48.14%) followed by vitreous haemorrhage (38.88%) and traumatic cataract (30.55%). The types of eye injury noted in our patients is given in Table-1. The treatment varied according to the type of injury. Forty eyes (37.03%) were treated medically and 68

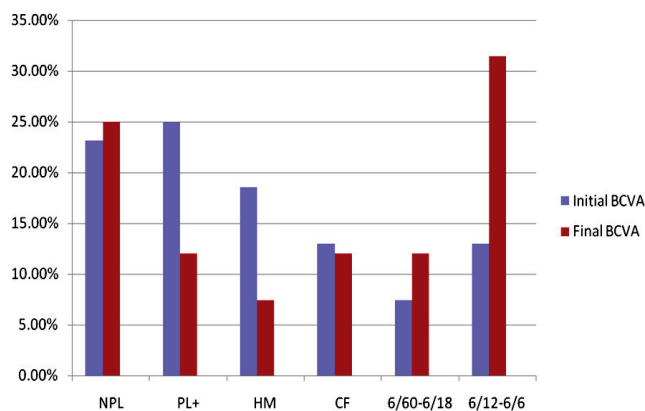


Figure: Initial and Final BCVA. X-axis shows the initial and final best corrected visual acuity (BCVA) of the patients and Y-axis shows the percentage of patients.

(62.96%) eyes were treated surgically. These patients underwent from 1 to 4 surgeries. Corneal/scleral repair was the most commonly performed surgery (33 eyes). Evisceration was done in 19 eyes; it was done in those with shattered globe (where repair was not possible) with poor visual potential or if there was globe perforation with endophthalmitis. Vitreo-retinal surgery was required in patients who had non-resolving vitreous haemorrhage, retinal detachment or posterior segment intraocular foreign body (IOFB) and in 2 patients with endophthalmitis. The type and number of surgeries are given in Table-2. In addition, 360 argon laser was done in 17 (15.74%) eyes, panretinal photocoagulation (PRP) was done in 2 (1.85%) and neodymium-doped yttrium aluminium garnet (Nd:YAG) laser capsulotomy in 2 (1.85%) eyes which had undergone cataract extraction with intraocular lens (IOL) implantation. The initial and final best corrected visual acuities (BCVA) are given in figure I. Final BCVA improved in 56 (51.85%) eyes, remained unchanged in 49 (45.37%) and worsened in 3 (2.77%) eyes.

In our study the initial visual acuity was no perception of light (NPL) in 25 (23.14%) eyes, perception of light (PL+) in 27 (25.0%), hand movement (HM) in 20 (18.51%), counting fingers (CF) in 14 (12.96%), 6/60 to 6/18 in 8 (7.40%) and 6/12 to 6/6 in 14 (12.96%) eyes. While the final VA was NPL in 27 (25.0%) eyes, PL+ in 13 (12.03%) eyes, HM in 8 (7.40%), CF in 13 (12.03%), 6/60 to 6/18 in 13 (12.03%) and 6/12 to 6/6 in 34 (31.48%) eyes.

In 61 (56.48%) eyes the final BCVA was < 6/60. Final BCVA improved in 52 (48.14%) eyes, remained unchanged in 52 (48.14%) and worsened in 4 (3.70%) eyes.

The time of presentation was an important prognostic factor in our study as 91.66% of the patients who presented > 10 days after eye injury had final BCVA < 6/60. Patients presenting within 10 days of injury had better visual outcome; out of these patients 53.33% had BCVA of 6/12-6/6, 18.33% had BCVA of 6/60-6/18 and 28.33% had BCVA < 6/60.

## Discussion

Trauma is a common cause of ocular morbidity. The effect of trauma may be apparent immediately or may develop later as a secondary complication. Ocular trauma can cause permanent visual or cosmetic defect in the affected individuals and is a major cause of monocular blindness and visual impairment throughout the world.<sup>20</sup>

Ocular trauma victims are predominantly young males,<sup>21</sup> as was the case in our study, with 78 (98.73%) males and 1 (1.26%) female.

The causes of ocular trauma varies at different times and at different places.<sup>7-12</sup> Bomb blast and mine blast are becoming increasingly common causes of ocular as well as systemic injuries. In the study conducted by Sethi MJ et al, bomb blast injuries accounted for 3% of ocular trauma.<sup>6</sup> In another study blasts were responsible for 9% cases of ocular trauma.<sup>22</sup>

The majority of blast-related ocular injuries occur in individuals who present with other life-threatening injuries that require immediate intervention. Surgical stabilization of any life-threatening injuries, as well as haemodynamic stability is required prior to initial evaluation by the ophthalmologist. Therefore, initiation of emergent ophthalmic care often occurs hours after injury.<sup>18</sup> In our study, before being referred to us the patients were assessed by a team of physicians and surgeons and any serious systemic injuries were properly managed. Therefore, in most patients the initial eye evaluation was delayed for a few days.

Visual outcomes for patients with ocular trauma due to blast injuries vary, and prognosis depends upon the type of injury sustained. The majority of poor visual outcomes arise from perforating injuries: only 21% of patients with

perforating injuries with initial visual acuity of light perception had a final BCVA better than 6/60. Patients who have choroidal haemorrhage, perforating or penetrating globe injury, retinal detachment, traumatic optic neuropathy, and subretinal macular haemorrhage are more likely to have BCVA worse than 6/60. Reports from Operation Iraqi Freedom indicate that 42% of soldiers with globe injuries had a BCVA equal to or better than 6/12 six months after injury.<sup>18,19,23</sup> During Afghan-Russia war the bomb blast injuries in Afghan refugees led to blindness in 27.2% cases.<sup>24</sup>

The final visual outcome also depends on the type of eye injury.<sup>18</sup> In our study, open globe injuries had poor visual outcome; 73.13% of these eyes had final BCVA < 6/60. On the other hand, only 29.26% of closed globe injuries had final BCVA < 6/60 while 58.65% had BCVA > 6/18.

Initial visual acuity of NPL or PL+, the presence of relative afferent pupillary defect (RAPD), central corneal opacity, retinal detachment, endophthalmitis, macular scarring and optic atrophy were other factors associated with poor final visual outcome.

## Conclusion

The visual prognosis in ocular trauma is variable. Blast associated ocular injuries are becoming increasingly common. Blast victims usually have very severe eye injuries. In such cases the visual prognosis still remains very poor despite development of advanced microsurgical techniques and better methods of visual rehabilitation.

## References

1. Gothwal VK, Adolph S, Jalali S, Naduvilath TJ. Demography and prognostic factors of ocular injuries in South India. *Aust NZ J Ophthalmol* 1999; 27: 318-25.
2. Stegmann D. Treatment of Anterior Segment Ocular trauma. *Montreal Medicopia* 1996; 7-12.
3. Negrel AD, Thylefors B. The global impact of eye injuries. *Ophthalmic Epidemiol* 1998; 5: 143-69.
4. May DR, Kuhn FP, Morris RE, Witherspoon CD, Danis RP, Matthews GP, et al. The epidemiology of serious eye injuries from the United States Eye Injury Registry. *Graefes Arch Clin Exp Ophthalmol* 2000; 238: 153-7.
5. Kuhn F, Morris R, Witherspoon CD, Mester V. The Birmingham Eye Trauma Terminology system (BETT). *J Fr Ophtalmol* 2004; 27: 206-10.
6. Sethi MJ, Sethi S, Khan T, Iqbal R. Occurrence of ocular trauma in patients admitted in Eye Department Khyber Teaching Hospital Peshawar. *J Med Sci* 2009; 17: 106-9.
7. Garrow A. A statistical enquiry into 1000 cases of eye injuries. *Br J Ophthalmol* 1923; 7: 65-80.
8. Canavan YM, O'Flaherty MJ, Archer DB, Elwood JH. A 10-year survey of eye injuries in Northern Ireland, 1967-76. *Br J Ophthalmol* 1980; 64: 618-25.
9. MacEwen CJ. Eye injuries: a prospective survey of 5671 cases. *Br J Ophthalmol* 1989; 73: 888-94.
10. Jones NP. One year of severe eye injuries in sport. *Eye* 1988; 2: 484-7.
11. MacEwen CJ. Sports associated eye injuries: a casualty department survey. *Br J Ophthalmol* 1987; 71: 701-5.
12. Desai P, MacEwen CJ, Baines P, Minaissian DC. Epidemiology and implications of ocular trauma admitted to hospital in Scotland. *J Epidemiol Community Health* 1996; 50: 436-41.
13. Treister G. Ocular casualties in the Six Day War. *Am J Ophthalmol* 1969; 68: 669-75.
14. Belkin M. Ocular injuries in the Yom Kippur War. *J Ocul Therapy Surg*

- 1983; 2: 40-9.
15. Newmann TL, Russo PA. Ocular sequelae of BB injuries to eye and surrounding adnexa. *J Am Optom Assoc* 1998; 69: 583-90.
  16. United States Department of Defense, Joint Publication 1-02, Department of Defense Dictionary of Military and Associated Terms. 2008, amended 2011; 171.
  17. Harlan JBX, Pieramici DJ. Evaluation of patients with ocular trauma. *Ophthalmol Clin North Am* 2002; 15: 153-61.
  18. Weichel ED, Coyer MH. Combat ocular trauma and systemic injury. *Curr Opin Ophthalmol* 2008; 19: 519-25.
  19. Wolf SJ, Bebarta MV, Bonnet CJ, Pons PT, Canhill SV. Blast injuries. *Lancet* 2009; 374: 405-15.
  20. Jackson H. Bilateral blindness due to trauma in Cambodia. *Eye* 1996; 10: 517-20.
  21. Tielsch JM, Parver LM. Determination of hospital charges and length of stay for ocular trauma. *Ophthalmology* 1990; 97: 231-7.
  22. Khan MD, Mohammad S, Islam Z, Khattak MN. An 11 years review of ocular trauma in North West Frontier Province of Pakistan. *Pak J Ophthalmol* 1991; 7: 15-8.
  23. Ramasamy A, Harrison SE, Clasper JC, Stewart MP. Injuries from roadside improvised explosive devices. *J Trauma* 2008; 65: 910-4.
  24. Friesen H, Asmat AA, Salim AG, Khan I. Incidence of incurable blindness in the Afghan refugees in Pakistan. *Pak J Ophthalmol* 1990; 6: 61-3.
-