

## An institutional review of transarterial embolization in haemorrhagic urological emergencies

Raza Sayani, Muhammad Azeemuddin, Tanveer ul Haq, Rana Shoaib Hamid, Basit Salam  
Department of Radiology, Aga Khan University Hospital, Karachi, Pakistan.

### Abstract

**Objective:** To review the effectiveness of therapeutic transarterial embolization in controlling phagic urological emergencies irrespective of the cause of emergencies.

**Methods:** Thirty-seven vascular angiographies were performed in 32 patients (19 males and 13 females, age range 19-70 years) who were referred with haemorrhagic urological emergencies to Aga Khan University Hospital's angiography suite from July 2005 to June 2010. Embolization was performed with coils, polyvinyl alcohol particles, N-Butyl cyanoacrylate glue and gel foam according to the clinical indication. Data on clinical indication, technique, site and type of bleeding lesions were obtained from a retrospective review of medical records. Success rate, clinical outcome and complications of the procedure were analysed.

**Results:** Indications of procedure included iatrogenic injury (16), Renal mass on clinical examination and imaging (4), haematuria with pseudoaneurysm on examination (3), haematuria with no known cause (3), post traumatic renovascular injury (2) Renal arteriovenous fistulas (2), Carcinoma of prostate (1) and pelvic arteriovenous (AV) fistula (1). Twenty four patients underwent successful endovascular control of bleeding. Eight examinations were negative for active extravasation, two of whom showed haemorrhage in second session and were embolized. Two sessions were needed in two patients at different time intervals. Complication as dislodgement of coil in distal profunda femoris artery was seen in one patient with no significant obstruction to flow.

**Conclusion:** Transarterial renal angioembolisation is a safe and effective therapeutic tool for managing haematuria or haemorrhage in urological emergencies. Wherever and whenever indicated it should be the first preferred treatment modality.

**Keywords:** Renal angioembolisation, Urological emergencies (JPMA 62: 107; 2012).

### Introduction

Transarterial angioembolisation (TAE) has a well-established role in endovascular treatment of haemorrhagic urological emergencies.<sup>1</sup> Renal vascular lesions may be iatrogenic, follow trauma or occur spontaneously with or without underlying pathology.<sup>2</sup> These injuries can result in haemorrhage which are self-limiting in most cases and do not need any intervention however presence of massive haemorrhage or continuous haematuria may necessitate aggressive therapy.<sup>3</sup> Treatment options include surgical intervention or minimally invasive transarterial embolization.<sup>4</sup> With the advancement in intervention radiology techniques and materials it is now possible to perform super selective embolization with minimal tissue loss.<sup>5</sup>

We aim to present the radiological and clinical results of patients who presented in our institution with haemorrhagic urological emergencies and were treated with endovascular embolization.

### Methods

The study followed a cross sectional design. The records of all patients who underwent embolization for renal vascular lesions at Department of Radiology, Aga Khan University from July 2005 to June 2010 were reviewed. All patients who presented with active haematuria, perirenal haematoma with drop in haemoglobin and/or deteriorating vitals or known renal mass with associated haematuria were included in the study. It was a convenient sampling strategy.

The procedures were performed by an experienced interventional radiologists in close collaboration with consultant urological surgeons where needed. Few cases were referred directly to radiology department, Aga Khan University from other hospitals. All patients were examined and treated as a part of routine care and gave informed consent. Procedures were carried out in dedicated Interventional Radiology suite on a flat panel monoplane digital subtraction angiography machine Axiom-Artis, Siemens. In most cases the procedure was performed under

local anaesthesia, femoral artery was punctured and a 5Fr vascular access sheath was inserted. 4Fr or 5 Fr Renal double curve (RDC) catheter (Cordis), Simmons (SIM 1) catheter (Cordis), or a Cobra (C1) angiographic catheter (Cordis) were advanced over a 0.035-inch guidewires. For superselective catheterization and embolization a microcatheter (Progreat Terumo) was used which was coaxially placed as near as possible to the lesion, and the embolizing agent was inserted. Embolization was performed when free extravasation, aneurysm, pseudoaneurysm, arteriolecal fistula (ACF), or arteriovenous fistula (AVF) was detected.

Embolizing agents consisted of vascular occlusion coils, polyvinyl alcohol particles (PVA) (355-500  $\mu$ ), a combination of coils and PVA particles or N-butyl cyanoacrylate (NBCA) glue. The procedure was completed when total occlusion of the vascularity of lesion and cessation of the haemorrhage was seen. Age, sex, clinical presentation including the symptoms and type of injury were obtained from the medical records. Site and number of lesions, embolization agents, selective or non-selective embolization were recorded.

The technical and medical success, and procedural complications were recorded from the departmental records and patient charts. Complete cessation of active extravasation after the embolization procedure was defined as technical success. Resolution of gross haematuria with absence of recurrent haematuria and no need for angiographic re-embolization or subsequent renal surgery were regarded as medical success. Technical complications such as non target embolization, iatrogenic vascular damage, and puncture- site bleeding were recorded.

## Results

Total of 37 vascular angiographies were carried out in 32 patients from July 2005 to June 2010. There were 19 males and 13 females. The mean age of these patients was  $48.2 \pm 15.4$  years.

The indications for renal angiography were gross haematuria (28) and perirenal/retroperitoneal haematoma (n=3), subcapsular haematoma (1).

Iatrogenic cause was dominant (16) out of these two were of post percutaneous nephrostomy (PCN) insertion, twelve were secondary to percutaneous nephrolithotomy (PCNL) and two were post renal biopsy. One patient had haematoma because of gunshot injury and in other renal vascular injury was due to fall. Four patients had renal masses on previous CT examinations suggestive of angiomyolipomas. Two had arteriovenous malformation. Three patients had pseudo aneurysms with unknown cause. One patient had haematuria post prostatectomy for carcinoma prostate. One had a pelvic arteriovenous fistula. Four patients had haematuria, however, no active extravasation or bleeder

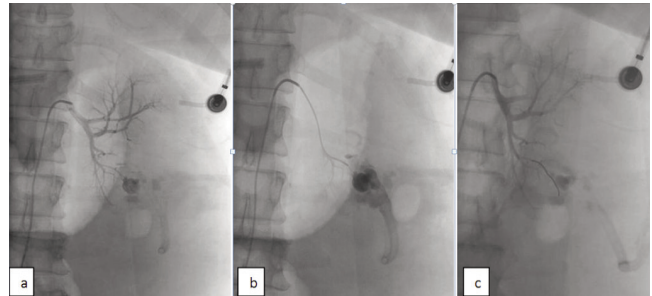


Figure-1: Angiogram showing pseudoaneurysm with active extravasation post pyelolithotomy. Pre (a&b) and post successful coil embolization(c).

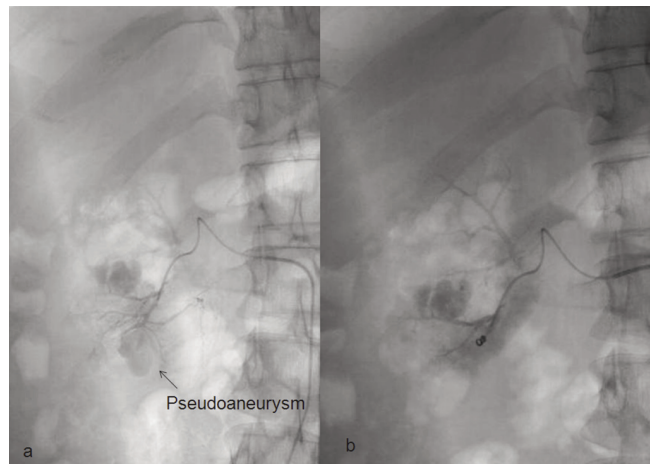


Figure-2: Angiogram showing pseudoaneurysm with active extravasation post pyelolithotomy. Pre (a) and post successful coil embolization(b) Calculus is also seen.

could be identified on angiography. Embolization was super selectively performed using microcatheters in most patients.

Most of the patients underwent angiography as the first imaging modality. Twenty nine lesions (Seventeen pseudoaneurysms, five free extravasations, four angiomyolipomas, two arteriovenous malformations and one arteriolecal fistula) were detected.

Sixteen patients underwent US or CT examination prior to the embolization procedure. US were performed in nine patients. It provided information about the presence of mass, hydronephrosis with echoes or haematoma. CT, which was performed in seven patients, showed the type of the lesion and location. Both modalities showed the condition of both kidneys.

Out of thirty two patients, twenty four patients had transarterial embolization (29 angiographies) for control of haemorrhage as an emergency. Embolization was successful in all except two (91%) patients, who continued to have bleeding in post-embolization period and required emergency nephrectomy. The histopathology showed angiomyolipoma. Figure 1 and 2 shows successful embolization using

microcatheter in a patient with hematuria status post nephrolithotomy.

One patient with haematuria post PCNL was embolized however repeat session was required after 11 days as haematuria persisted. Free extravasation was identified from different subsegmental branch which was selectively catheterized and vessel was occluded successfully with a micro coil.

One patient was diagnosed as having four pseudo aneurysms filling from different subsegmental arteries; and all subsegmental branches were selectively cannulated selectively and embolized separately.

Two patients were diagnosed with renal AV fistulas and embolization was performed using NBCA glue in one and fibered steel coil in other.

Four patients presented with angiomyolipoma (AML) of which one patient had bilateral lesions. Second session was repeated after 3 years however as the tumour had increased in size and haematuria persisted, nephrectomy was performed. Another patient with AML was embolized using PVA, however, later nephrectomy was performed due to uncontrolled haematuria.

One patient had carcinoma of prostate, operated and presented with haematuria which persisted and embolization of internal iliac using PVA was performed.

Eight angiographies in seven patients were negative for any active extravasation; one had a renal mass which was faintly vascular, two were post PCNL, one was post renal biopsy and two had haematuria with no known cause. Two of these patients showed active extravasation in repeat angiography performed later because of persistent complaints. First patient's angiography was repeated after 2 days and revealed active extravasation and was embolized using microcoil. Other patients who's first renal angiography was negative for active extravasation, however because of persistent complaints, repeat angiography was performed 6 days later which included internal iliac arteries and showed AV fistula in pelvis which was embolized.

Technical success was achieved in all patients, and clinical success was achieved in (91%) patients. Complications as puncture-site bleeding, postembolization syndrome, perirenal abscess or renal abscess were not detected in any of the patients. There was dislodgement of coil in distal profunda femoris artery in one patient however no significant obstruction to flow was seen.

## Discussion

Transarterial embolization is a highly effective method for controlling bleeding in urological emergencies and has been successfully used for over 30 years. The use of this

technique in controlling massive bleeding in urological injuries could be life saving.<sup>2</sup> Limitation in our setup is the cost of the procedure which is variable and depends on usage of microcatheter and number of microcoils. It is around hundred thousand Pakistan rupees in many cases. The main presenting complaints are persistent haematuria, perirenal haemorrhage, and drop in haemoglobin with deteriorating vitals.

Most of the renal injuries are minor with healing which occurs spontaneously in the majority so conservative management becomes the preferred approach.<sup>6,7</sup> Surgical intervention to control haemorrhage is required in patients if haematuria is persistent or life threatening, vitals are deteriorating and size of haematoma is increasing. Surgical intervention may be averted because of endovascular management aimed at localizing and embolizing the vascular lesion.

Angiography has a very high specificity in depicting the bleeding lesion and has been able to identify lesions in the majority of the reported studies.<sup>8,9</sup> However in rare instances angiography may not be able to demonstrate the traumatized vessel.<sup>10</sup> This was observed in one of our patient where initial angiography was unable to demonstrate extravasation however repeat procedure showed the bleeder. The choice between surgical or percutaneous management largely depends on the condition of the patient and the availability of interventional services in the institution. Patients with severe haemodynamic instability undergo emergent laparotomy however those patients who can maintain a relatively stable status can benefit from percutaneous angioembolisation.<sup>11</sup>

Iatrogenic injuries have been seen to be the most common cause of injury to renal artery or its branch. They have significant morbidity and even mortality.<sup>12</sup> The causes include percutaneous nephrolithotomy, biopsy or percutaneous nephrostomy. Arterial lacerations and ruptures, pseudoaneurysms, arteriovenous fistulae and arterio-calyceal fistulae are the most common renal vascular injuries.<sup>9,13</sup> The bleeding site can be exactly diagnosed and embolization can be performed by selectively cannulating the vessel. Kessaris et al<sup>14</sup> performed 2,200 percutaneous renal procedures with 17 (0.8%) patients requiring angiography and embolization for significant bleeding. Only 2 patients required open exploration following embolization. Bhaskar K Somani et al<sup>2</sup> performed 1,800 nephrolithotomies with 5 (0.3%) needing embolization. None required surgical intervention. Phadke et al<sup>15</sup> treated iatrogenic renovascular injury in 27 patients after percutaneous renal procedure.

Post traumatic haemorrhage as in fall or gunshot injury is an emergency where an early diagnosis is the key to save life. Embolization may be necessary to stop the haemorrhage as patient may not be suitable for surgical intervention.

A high risk of recurrent bleeding is associated with tuberous sclerosis. RAE has now become the initial treatment of choice for most symptomatic AMLs. Kothary and colleagues<sup>16</sup> performed angioembolisation in 30 patients of angiomyolipomas (AML). In our series we had 4 patients with angiomyolipomas and we were able to embolize two patients successfully. One patient with bilateral large angiomyolipomas needed two sessions of embolization and finally nephrectomy was performed after 4 years of first session due to recurrence of haematuria.

Nabi et al<sup>17</sup> performed successful embolization of anterior division of internal iliac artery in 6 patients for palliative management of intractable haematuria due to bladder tumour. Gujral et al<sup>18</sup> suggested performing this procedure in peri-operative phase to control intractable bleeding following transurethral resection of bladder tumour. We had good results in a patient with haematuria post transurethral resection of prostate.

Other imaging modalities like ultrasound and MRI may be helpful in early and accurate diagnosis.<sup>19,20</sup> Recent studies with MDCT have shown promising results in diagnosis of renal vascular injuries however angiography remains the standard with the edge of performing therapeutic intervention during the same imaging session.<sup>21</sup> Ultrasound being readily available helps in diagnosing mass or any procedure related haematoma or collection. In our experience patients with active haematuria should be transferred to the angiography unit as soon as possible

The choice of the embolization material is important for efficient treatment of vascular injuries. The site and size of the vessels to be occluded, the material available and experience of radiologist with specific material all influence this choice.<sup>22</sup> The embolizing agents used for renal vessels predominantly include coils however PVA, gel foam and NBCA are available and used. The exact localization and catheterization of the abnormal vessel with the use of microcatheters and microcoils results in reduced tissue loss however the main disadvantage of coils is the cost as usually more than one coil is frequently required for adequate occlusion. In our experience the coil was the most effective tool in controlling the bleed however more than one coil was required in most of the cases.

PVA is biocompatible and inert and provides rapid occlusion of the vessels. Therefore we utilize this for mass lesions with occlusion of microvasculature. The use of NBCA in renal arteries has been reported by Yamakado et al<sup>23</sup> and Parildar et al.<sup>24</sup> We used glue in one of our patient with high flow AV fistula.

Complications related to endovascular embolization procedures are rare.<sup>14</sup> Minor complication such as puncture site haematoma or bleed may be there. Inadvertent or

nonselective embolization due to inability to control the embolizing material as PVA has been reported, also the dislodgement at undesired sites have been experienced as in one of our patients where coil lodged in profunda femoris. Vascular dissection has been reported in literature in a few patients. Other complication as renal failure, contrast nephropathy and haemorrhagic shock induced acute tubular necrosis have been reported to result in renal impairment however this has significantly reduced with superselective angiographic techniques. In most of our patients microcatheters were used to superselectively cannulate the abnormal vessel thus resulting in reduced post embolization infarct size

## Conclusion

Percutaneous transarterial embolization is an effective method of treatment of renovascular injuries. In institutions where close coordination between urology service and interventional radiologists is possible life threatening emergencies can be managed with minimally invasive arteriography and embolization as the first choice.

## References

1. Brkovic D, Moehring K, Doersam J, Pomer S, Kaelble T, Riedasch G, et al. Aetiology, diagnosis and management of spontaneous perirenal haematomas. *Eur Urol* 1996; 3: 302-7.
2. Somani BK, Nabi G, Thorpe P, McClinton S. Endovascular control of haemorrhagic urological emergencies: an observational study. *BMC Urol* 2006; 6: 27.
3. Brandes SB, McAninch JW. Urban free falls and patterns of renal injury: a 20-year experience with 396 cases. *J Trauma* 1999; 47: 643-9.
4. Dinkel HP, Danuser H, Triller J. Blunt renal trauma: minimally invasive management with microcatheter embolization experience in nine patients. *Radiology* 2002; 223: 723-30.
5. Poulakis V, Ferakis N, Becht E, Deliveliotis C, Duex M. Treatment of renal-vascular injury by transcatheter embolization: immediate and long-term effects on renal function. *J Endourol* 2006; 20: 405-9.
6. Pollack HM, Wein AJ. Imaging of renal trauma. *Radiology* 1989; 172: 297-308.
7. Cass AS, Luxenberg M. Which renal lacerations will heal satisfactorily with nonsurgical management? *Urology* 1989; 33: 367-70.
8. Corr P, Hacking G. Embolization in traumatic intrarenal vascular injuries. *Clin Radiol* 1991; 43: 262-4.
9. Fischer RG, Ben-Menachem Y, Whigham C. Stab wounds of the renal artery branches: Angiographic diagnosis and treatment by embolization. *AJR Am J Roentgenol* 1989; 152: 1231-5.
10. Sofocleous CT, Hinrichs C, Hubbi B, Broutztes E, Kaul S, Kannmarkat G, et al. Angiographic findings and embolotherapy in renal arterial trauma. *Cardiovasc Intervent Radiol* 2005; 28: 39-47.
11. Sclafani SJ, Sahaftan GW, Mitchell WG, Nayaranaswamy TS, McAuley J. Interventional radiology in trauma victims: Analysis of 51 consecutive patients. *J Trauma* 1982; 22: 353-60.
12. Naem M, Anwar K. Iatrogenic injuries of renal pelvis and ureter following open surgery for urolithiasis. *J Pak Med Assoc* 2001; 51: 282-5.
13. Uflacker R, Paolini RM, Lima S. Management of traumatic hematuria by selective renal artery embolization. *J Urol* 1984; 132: 662-7.
14. Kessaris DN, Bellman GC, Pardalidis NP, Smith AG. Management of haemorrhage after percutaneous renal surgery. *J Urol* 1995; 153: 604-8.
15. Phadke RV, Sawlani V, Rastogi H, Kumar S, Roy S, Bijlal SS, et al. Iatrogenic renal vascular injuries and their radiological management. *Clin Radiol* 1997; 52: 119-23.
16. Kothary N, Soulen MC, Clark TW, Wein AJ, Shlansky-Goldberg RD, Crino PB,

- et al. Renal angiomyolipoma: long-term results after arterial embolization. *J Vasc Interv Radiol* 2005; 16: 45-50.
17. Nabi G, Sheikh N, Greene D, Marsh R. Therapeutic transcatheter arterial embolization in the management of intractable haemorrhage from pelvic urological malignancies: preliminary experience and long-term follow-up. *BJU Int* 2003; 92: 245-7.
  18. Gujral S, Bell R, Kabala J, Persad R. Internal iliac artery embolization for intractable bladder haemorrhage in the perioperative phase. *Postgrad Med J* 1999; 75: 167-8.
  19. Sullivan RR, Johnson MB, Lee KP, Ralls PW. Color Doppler sonographic findings in renal vascular lesions. *J Ultrasound Med* 1991; 10: 161-5.
  20. Dong Q, Schoenberg SO, Carlos RC, Neimatallah M, Cho KS, Williams DM, et al. Diagnosis of renal vascular disease with MR angiography. *Radiographics* 1999; 19: 1535-54.
  21. Chazen MD, Miller KS. Intrarenal pseudoaneurysm presenting 15 years after penetrating renal injury. *Urology* 1997; 49: 774-6.
  22. Mavili E, Dönmez H, Ozcan N, Sipahioğlu M, Demirtaş A. Transarterial embolization for renal arterial bleeding. *Diagn Interv Radiol* 2009; 15: 143-7.
  23. Yamakado K, Nakatsuka A, Tanaka N, Takano K, Matsumara K, Takeda K. Transcatheter arterial embolization of ruptured pseudoaneurysms with coils and n-butyl cyanoacrylate. *J Vasc Interv Radiol* 2000; 11: 66-72.
  24. Parildar M, Oran I, Memis A. Embolization of visceral pseudoaneurysms with platinum coils and N-butyl cyanoacrylate. *Abdom Imaging* 2003; 28: 36-40.
-