

# Gram Negative Meningitis resulting from Rupture of a Spinal Epidural Abscess Into The Subarachnoid Space

Saba Lodhi, Tahseen Mozaffar, Arif R. Sarwari ( Department of Medicine, The Aga Khan University Faculty of Health Sciences, Karachi. )

## Introduction

Although a frequent and extensively described cause of meningitis in neonates, gram-negative meningitis is unusual in adults. Most of the cases reported are secondary to trauma or surgery<sup>1,2</sup>. Spontaneous cases are rare and almost always have a primary focus of infection elsewhere which needs to be explored<sup>3</sup>. We report the case of a young woman with gram—negative meningitis secondary to rupture of a spinal epidural abscess into the subarachnoid space.

## Case Report

A 27 year old married female developed an excruciating neck pain, over a period of 20 days, (described as being worse than labor pain by the patient) for which she went to a local doctor, Her X-ray of the cervical spine were normal. Physiotherapy provided minor relief. On the twentieth day of her illness, she developed high-grade fever with vomiting and altered mental status. She was seen at a hospital and a CT scan of the head was done which showed signs of meningitis. She was advised a lumbar puncture which she refused and came to our hospital.

On examination she was disoriented and confused. She had bilateral sixth and seventh nerve paresis and left hemiparesis. Lumbar puncture yielded pus at high pressure. CSF proteins were 1053 mg/dl, glucose was 0, white cells were 57800 with predominantly lymphocytes (60%). Latex particle agglutination test was negative for Haemophilus influenzae, Streptococcus pneumoniae and Neisseria meningitidis. CSF gram stain showed gram negative bacilli but bacterial and mycobacterial cultures showed no growth. She was started on meningitic doses of third generation cephalosporins and an antituberculous regimen. MRI of the cervical spine (Figure)

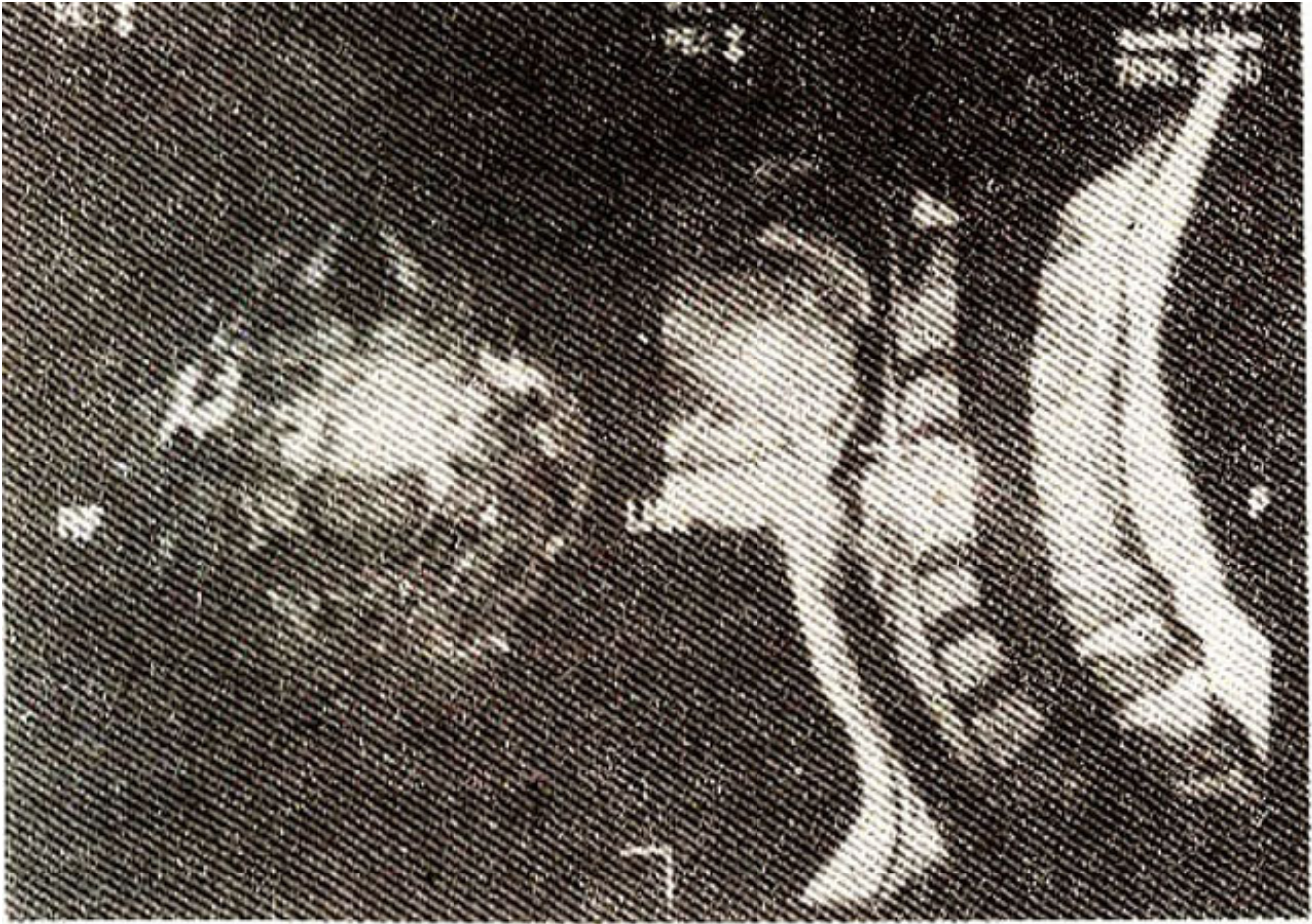


Figure. Gadolinium enhanced T-1 weighted MRI images of the cervical spine. The left panel shows axial sections through C4, highlighting the contrast enhancing inflammatory tissue in front of the vertebral body. No compression of the spinal cord is seen. The right panel shows a sagittal view of the cervical spine. Note the contrast enhancement of the C4 and C5 vertebral bodies and the prevertebral and the epidural inflammatory tissue (arrow). No spinal cord compression is seen.

showed infective spondylitis involving C4 and C5 vertebrae associated with extensive meningeal and arachnoid inflammation and focal myelitis at these levels. A CT guided vertebral body fine needle aspiration was obtained which revealed no growth on bacterial or mycobacterial cultures. The antituberculous regimen was stopped and she was treated for a total of six weeks with Fourteen days of intravenous antibiotics followed by four weeks of oral fluoroquinolones. Her cervical pain resolved and her examination and condition improved with resolution of the cranial nerve paresis.

## Discussion

Meningitis caused by gram negative bacilli was first reported in 1892<sup>4</sup>. Subsequent reports have been infrequent and have primarily focussed on neonates and on post surgical and post traumatic patients. Literature on non traumatic gram negative meningitis shows an association with underlying bacteremia and/or alcoholism, usually in patients who are old, immunosuppressed or chronically debilitated<sup>5</sup>. Instrumentation of the urinary tract constitutes the commonest portal of entry of the infectious agents<sup>3</sup>. Other genitourinary or pelvic sources, spinal anaesthesia and bacteremias arising from pneumonias and wound infections have also been reported. A few cases have also occurred following direct extension of an infective focus such as mastoiditis or chronic sinusitis<sup>6</sup>. Gram negative meningitis may also occur

secondary to intraventricular rupture of a brain abscess.

Spinal epidural abscess is most commonly caused by *Staphylococcus aureus* followed by aerobic or facultative gram negative bacilli<sup>7</sup>. Although the presentation may be acute or chronic, published experience over the past years suggests that the clinical features evolve through four stages; spinal ache, root pain, motor weakness and finally paralysis<sup>8,9</sup>. Concomitant overlying osteomyelitis is common as is extension of infection to the subdural space, an event that influences the clinical consequence. Meningitis following the rupture of a spinal epidural abscess is rare.

Meningitis arising secondary to a ruptured epidural abscess may present a clinical picture highly suggestive of TBM. save for the spinal ache, and with the high incidence of TBM in our population is likely to be misdiagnosed. The physician therefore must maintain a high index of suspicion, especially concerning patients with fever and focal vertebral pain, because delayed diagnosis may result in devastating neurological sequelae.

## References

1. Jang TN, Watt g FD, Waite IS, et al. Gram negative bacillary meningitis in adults: a recent six-year experience. *J Formos Med Assoc* 1993; 92: 540-6,
2. Hsu-GJ Young-TG Chou SW. et al Gram negative bacillary meningitis in adults *J. Formos. Med. Assoc.* 1993 :92. 3 7—23.
3. Steven I. B William R . Meningitis caused by gram negative bacilli. *Ann Intern Med*, 1980;93 :253-54.
4. Macsiste M . *Le bacterium coil cominute sen stile dana Ia pathologic* ( Thesis. Paris tin. 1974) Paris Societe el Editors Scientifiques: 1892.
5. Crane LR, I crner AM Non-traumatic gram negative bacillary meningitis III the Detroit medical centre (with special mention of cases due to *E. coli*) 1964— 974: *Medicine*. 1978;57:197-209.
6. Gower DJ, Barrows AA, Kelly DI, et al. Gram negative bacilli II acute meningitis in the adult review of 39 cases. *South. Med J* - 1986; 71): I 499-502
7. Daroviete RO, Hiunill RJ Greenberg SB, et al. Bacterial Spinal epidural abscess, Review of 43 cases and literature survey *Medicine*, (Baltimore) 1992;71:369-85.
8. Baker AS. Ojemann RG, Swartz MN, et al. Spinal epidural abscess *N Engl. J. Med.* I 1975;293:463-68.
9. Danner RL. Hartman BJ, Update of spinal epidural abscess: 35 cases and review of literature. *Rev. Infect. Dis*, 1987;9 265-74.