

Endocrine Cell Dysplasia (Nesidioblastosis): A Relatively Unrecognized Entity in Pakistan?

Nasim Sabir, Irshad Nabi Soomro, Zafar Nazir, Abdul Jabbar, Sheema H. Hasan (Department of Pathology, The Aga Khan University Hospital, Karachi.)

Introduction

Nesidioblastosis is quantitative as well as qualitative abnormality of pancreatic endocrine cells. There is scattering of small endocrine cell clusters arranged haphazardly rather than the peripheral location within the lobule^{1,2}. Islet contours are irregular, tailing off into parenchyma³. These islets are present in intimate association with ducts forming ductuloinsular complexes¹. We recently encountered a new born baby with signs and symptoms of endocrine cell dysplasia.

Case Report

A baby boy was born to a mother who had lost two of her previous babies in early infancy. This premature boy was born after Cesarean section and was large for gestational age having a birth weight of 5.4 kg. A day after the birth he presented in the neonatal ICU with symptoms of lethargy and grunting. On examination this boy was cyanosed and tachypnoeic. All the other reflexes appeared normal. The laboratory investigations revealed his blood sugar to be 37 mg/dl and insulin level 26 iu/ml.

His condition improved after Intravenous infusion of 13% dextrose water but further 1-2 hourly blood sugar assays reflected persistently low blood sugar levels. A single seizure also occurred on that night.

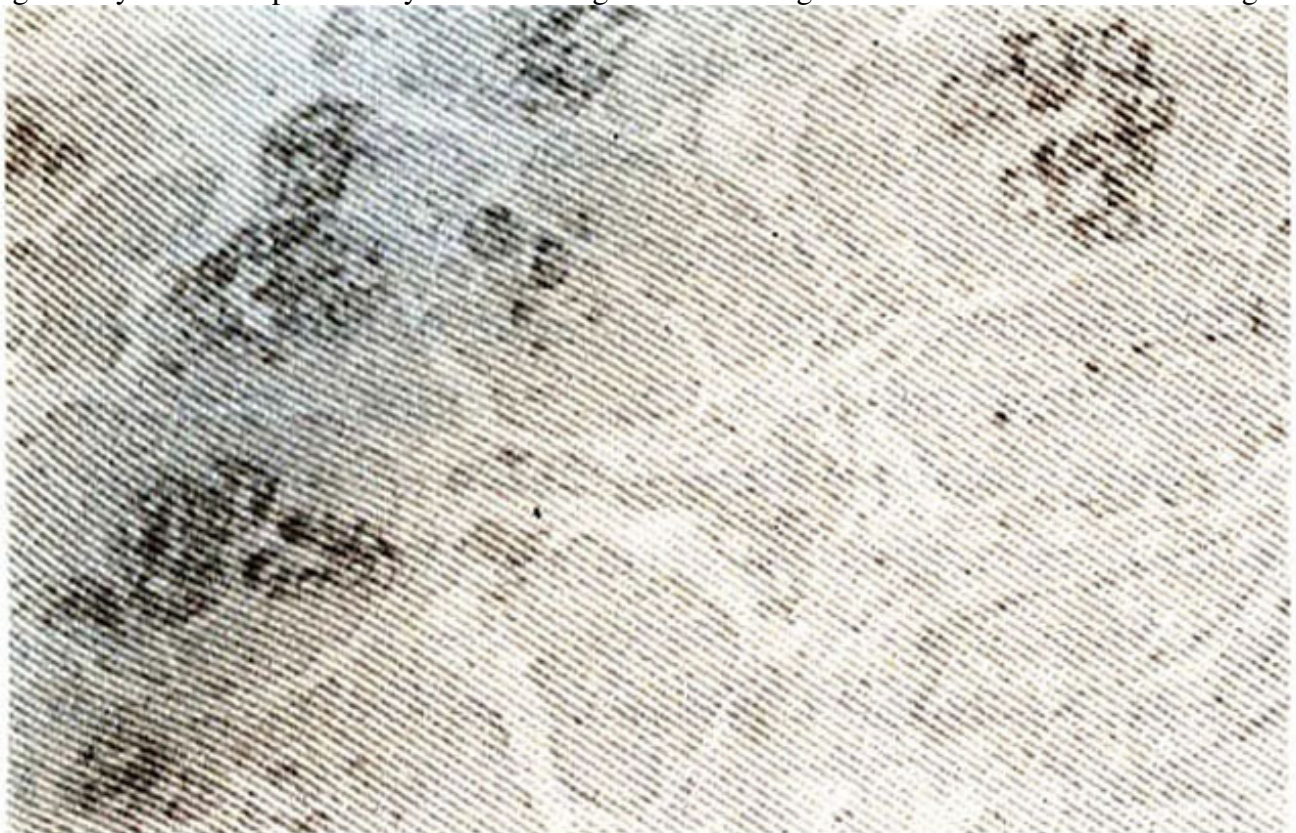


Figure 1. Section of the pancreas immunostained with synaptophysin shows quantitative increase in the endocrine component of cells. (peroxidase antiperoxidase method)

Breast feeding was initiated but still multiple doses of intravenous dextrose water were required to keep the blood sugar levels normal. Other medications were also given, which initially comprised of Intravenous injection of Hydrocortisone 10 mg six hourly and later injections Glucagon and Somatostatin were also started regularly and as the condition did not improve much, Diazoxide was also added to the previous treatment.

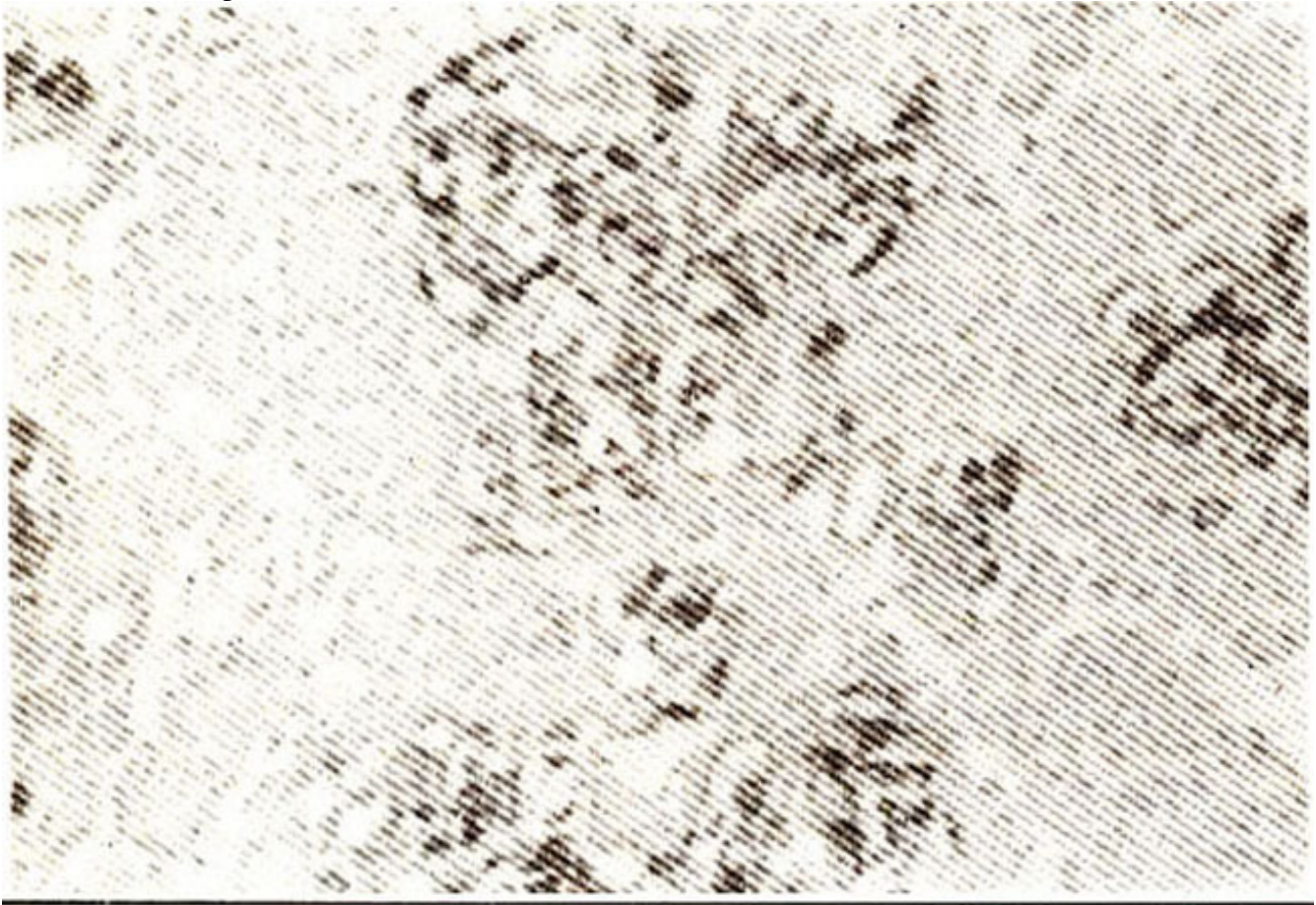


Figure 2. Endocrine cells are arranged in clusters of irregular sizes and shapes

Irrespective of these measures For a period of one and a half—month the blood sugar levels remained very low. mostly in the range of 20-80 mg/dl. The patient was eventually subjected to surgery on October 10th 1998 and 90-95% of the pancreas was removed and sent for histopathology. The paraffin embedded sections examined revealed a quantitative increase of endocrine cells. These were scattered within pancreatic lobules haphazardly, having irregular shapes and sizes, Endocrine nature of these cells was further confirmed by pancreatic markers i.e., Synaptophysin and Chromogranin. Peroxidase antiperoxidase technique was used for antigen and antibody reaction. Specific markers i.e., antibodies for insulin and glucagon are not available in our laboratory. The condition was diagnosed to be benign hyperplasia of beta cells Islets of Langerhans, consistent with the features of Nesidioblastosis,

Post-operatively the blood sugar levels gradually came back to normal and the patient was discharged. He has been doing well since then and the last Follow up 6 months after being discharged revealed normal blood glucose and insulin levels.

Discussion

Nesidioblastosis, a state of persistent hyperinsulinemic hypoglycemia of infancy is actually a Greek

term nesidio (islet) and blastosis (proliferation)^{4,5} This disease must be considered as a medical emergency. Prompt diagnosis and aggressive treatment can only save the life of a neonate, otherwise permanent brain damage can result due to severe hypoglycemia. There can be other diseases resulting in hypoglycemia, but Nesidioblastosis is the only one, which must be treated with surgical resection of Pancreas³.

Clinically, Nesidioblastosis usually manifests within 48 hours of birth, with an instability of blood glucose levels, usually occurring every hour or less after feeding. Other milder forms do occur, which may be seen in the first six months of life. Signs of central nervous system glucopenia dominate the clinical picture. Symptoms may be nonspecific like cyanosis, lethargy, hypotonia, hypothermia, poor feeding, high pitched cry, irritability and convulsions, Other signs like irritability after long fasts, confusion, bizarre behavior, headache, hunger abdominal pain and nausea can occur Signs of excessive catecholamine release like tremors, pallor tachycardia and coldsweats are usually observed in old children. Though the symptoms may be nonspecific, persistent hypoglycemia should be documented and treated with glucose.

Two highly significant findings have also been observed in the infants born with this disorder. Firstly they are large for gestational age at birth and the weight goes on increasing due to high carbohydrate feeding. Secondly they show no progressive hepatomegaly.

In Nesidioblastosis two histopathological forms have been discussed. focal and diffuse both occur at equal frequency⁶ Focal lesions range from solitary adenomas to nodular hyperplasia of islet cell clusters. Which include ductuloinsular complexes and hyperplastic insular cells with giant nuclei⁷. These lesions may be unifocal, multifocal or diffuse. In the diffuse type budding of endocrine cells from pancreatic ducts, ductuloinsular complex, increased total endocrine areas and abnormalities in the distribution of A,B,C,D and PP endocrine pancreatic cells are shown to be present⁸.

Some researchers attribute both focal and diffuse type to increase in the nuclear size and DNA content of the β cell⁹, which reflect metabolic hyperfunction of β cells as a result of basic functional defect.

Another group using long term islet cell cultures on an extracellular matrix, demonstrated maximum insulin secretion in the complete absence of glucose and attributed a defect in the control of insulin secretion to be responsible for this hyperinsulinism.

The protocol for the diagnosis of this disease suggests that nesidioblastosis should be suspected when the glucose requirement to avoid hypoglycemia is more than 15 mg/kg/minute. Multiple blood samples for insulin (three to six) must be obtained at the time of hypoglycemia, as an appropriate insulin level in a single sample does not exclude Nesidioblastosis.

Other tests like measurement of free fatty acids, ketone bodies, urinary or plasma C-peptide may be especially helpful in the diagnosis. Glucagon stimulation test must be done to exclude hepatic or metabolic defect. Imaging techniques like ultrasonography and computed tomography (CT) so far have not been able to detect most of these localized lesions. Percutaneous transhepatic portal and pancreatic vein catheterization with serial insulin measurement have been under investigation in children.

The treatment includes symptomatic measures such as intravenous glucose and dietary interventions, attempts at suppression of insulin (with diazoxide or with long acting somatostatin analog Octreotide), attempts at induction of resistance to insulin effect with glucocorticoids or glucagon and reduction of insulin secreting cells mass with specific cytotoxic drugs, or surgery. The surgical treatment of hyperinsulinism in infancy and childhood is distal extensive (90-95%) subtotal pancreatectomy¹⁰.

The death of two previous siblings with almost similar symptoms, raises a suspicion of hyperinsulinemic hypoglycemia, although this condition could not be documented, In both these infants one could blame the ignorance of treating physician and raise a possibility of saving lives if proper diagnosis was done and prompt treatment was initiated. Though this baby was saved due to prompt diagnosis and efficient and timely management by the paediatric and the surgical team, still awareness about this rare disorder in most primary and secondary care hospitals does not exist.

References

1. Goosens A, Gepts W, Sandubary JM, et al Diffuse and focal nesidioblastosis A clinicopathological study of 24 patients with persistent hyperinsulinemic hypoglycemia *Ant J.Surg Pathol* 989.13 766-75.
2. Bani D, Bani Sacchi T, Billiot G. Nesidioblastosis and intermediate cells in the patients with hyperinsulinemic hypoglycemia *Virchows Arch, (B)* 1985.48:19.
3. Brown R, Madge GE Cystic fibrosis and nesidioblastosis *Arch Pathol* 1979;92:53.
4. Landua H. Schiller M. Persistent hyperinsulinemic hypoglycemia of infancy anti childhood *Pediatric Surg. Liver pancrease. spleen* 1991 13 87-201.
5. Dunger DB. Bunrs C, Ghale GK, et al. Pancreatic exocrine and endocrine functions after subtotal pancreatectomy for nesidioblastosis. *J Pediatr Surg.*,1988;18:112-15.
6. Stanley CA. Baker L. Hyperinsulinism in infants and children *Diagnosis and therapy Adv Paediatr* 1996;23 31 5-55.
7. Witte DR Greider MH. De Sehryver-Kecskemeti K, et al The juvenile endocrine pancreas. Normal and idiopathic hyperinsulinemic hypoglycemia *Semin Diagn Pathol* 1984;130-42.
8. Yakovac WC, Baker L, Hummeter K Beta cell nesidioblastosis in idiopathic hypoglycemia of infancy. *J Pediatr* 1979;79:226-31.
9. Ariel. Kerem E, Schwartz-Arad D. et al Nesidioplasia-a histological entity? *Hum Pathol* , 1988.19 1215-18.
10. Labrune PH, Bonnefont JP, Nihoul-Fekete C. et al, Evaluation of diagnostic and therapeutic methods in hyperinsulinism (neonates amid infants) a report 26 cases *Arch Fr Pediatr*, 1959;46:167-73.