

Thymic Hyperplasia A cause of respiratory distress

F. K. Tareen, S. Hussain, F. Moazam (Department of Surgery, Aga Khan University Hospital, Karachi.)

Introduction

Thyric hyperplasia is the most common anterior mediastinal mass in infants and the patient is usually asymptomatic^{1,2}. True thyric hyperplasia is characterized by massive thymic hypertrophy however, the normal thymic architecture is retained³. Massive thyric hyperplasia (MTH), a rare variant of hyperplasia of the thymus, is known to cause mediastinal compression or acute and recurrent respiratory infections in the pediatric age group. It needs to be distinguished from other commonly seen masses of the anterior mediastinum². We report two such cases and allude to the clinicopathological scenario in which they present and management options in these cases.

Case Report 1

A three month-old baby boy weighing 7.8 kg presented with respiratory distress, being treated for presumed pneumonia for last three weeks. Chest X-ray and CT scan revealed mass in the anterior mediastinum occupying upper half of both hemithoracis (Figure Ia, 1 b).

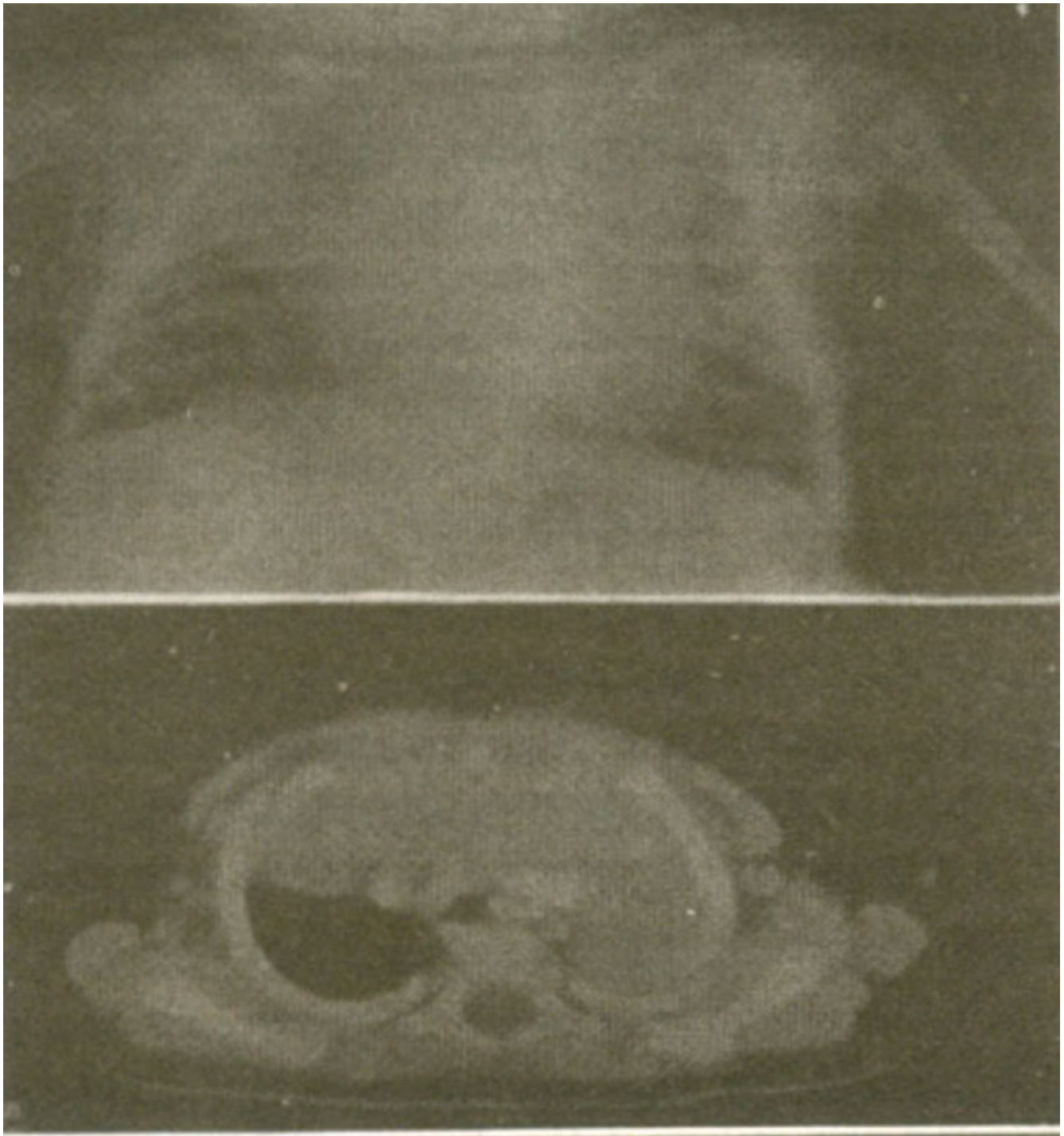


Figure 1a. X ray chest showing large thymic mass occupying upper half of both hemithoracis

Figure 1b. CT scan demonstrating large anterior mediastinal mass involving both side of the thoracic cavity.

Based on clinical and radiological features, provisional diagnosis of thymic hyperplasia was made and the patient was given oral steroids. The child showed marked clinical improvement within a week. Subsequent follow up with ultrasound scan and X-ray chest showed considerable reduction in size. The steroid was tapered off after one week. On subsequent follow up of over six months, there is no

evidence of clinical and al relapse.

Case Report 2

An eight-month-old baby boy weighing 5.6 kg was referred for evaluation of anterior mediastinal mass. The patient had been treated for presumed respiratory infection at referring facility for the last three months. At presentation, examination revealed the child to be tachypnoeic, dyspnoeic, with intercostals recession and stridor. Chest radiograph and CT scan revealed a large anterior mediastinal mass, occupying entire right hemithorax and causing collapse of the right lung (Figure 2 a,2b).

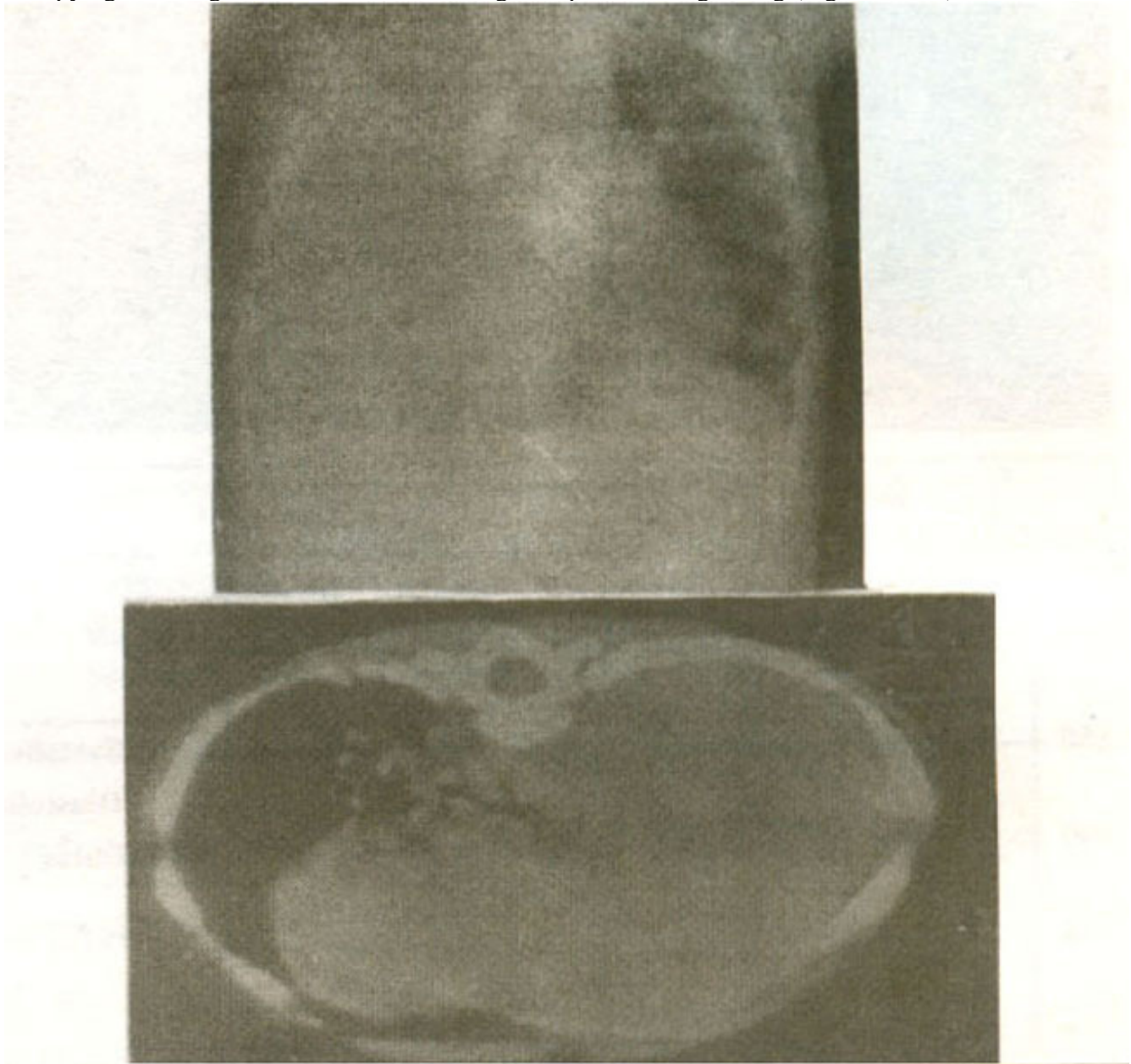


Figure 2a. X ray showing complete white out of the right hemithorax by mediastinal mass.
Figure 2b. CT scan revealing occupation of the right hemithorax by the homogenous mediastinal mass and collapse of the right lung.

Based on clinicoradiological features, diagnosis of thymic hyperplasia was made and on oral steroids started.

After initial remission, symptoms relapsed. CT guided fine needle aspiration biopsy (FNA) showed mature thymic cells with Hassal's corpuscles. Thymus which occupied nearly entire hemithorax was

excised. Postoperative recovery was uneventful and child on follow up over six months is asymptomatic. Histology confirmed the diagnosis of thymic hyperplasia.

Discussion

MTH is a rare condition of abnormal thymic growth³. Thymus can be quite prominent in the newborn but very little to be seen after the age of two years⁴. Confusion arises to differentiate the thymic hyperplasia from both normal and abnormal condition of thymic growth.

MTH is a rare idiopathic variant of true thymic hyperplasia. Literature review showed sporadic case reports of symptomatic thymic hyperplasia. No definite criteria for diagnosis of MTH exists, but the following guidelines have been suggested for the definition of MTH²: (1) It should be greater than the heart shadow on posteroanterior chest radiograph (2) The thymus gland should weigh several times the expected weight for the body mass (3) It should represent more than 2% of the body mass. Diagnosis of an enlarged thymus on a chest radiograph may be problematic as its size, shape, position and growth pattern are variable¹. Other anterior mediastinal masses that present in children are: teratomas, lymphosarcoma, lymphangioma, hemangioma, substernal thyroid, thymic tumor and thymolipomas and must be considered in differential diagnosis. CT scan is helpful in differentiating the thymic lesion from others⁴. The management of large thymic mass is controversial. When the mass is asymptomatic and the patient is less than two years of age, the patient can be followed under close observation, the mass often regresses with or without steroid administration⁵. Thymolytic effects of steroids are well documented, but this test is inconsistent and lacks specificity^{2,3}. In children under 2 years of age, asymptomatic mass can be observed and a trial of steroid given, as in this age group lymphoma is not a major diagnostic consideration⁴. Follow up is required until thymus involutes. In thymic hyperplasia refractory to steroid therapy, FNA biopsy should be done. Thymic mass causing airway obstruction or affecting normal pulmonary development should be excised^{2,4,6}.

References

1. Dimitriou G, Greenough A, Rafferty G. et al. Respiratory Distress in a neonate with an enlarged thymus. *Eur, J. Pediatr.*. 2000;159:237-8.
2. Lee TM, Kohl MT, Omar A. Hyperplasia of thymic gland. *Singapore Med, J.*, 1996;37:288-90.
3. Henry E, Rice A, Alan W, Flake W, Hon T, et al. Massive thymic hyperplasia: characterization of a rare unidiastinal mass. *J. Pediatr. Surg.*. 1994;29:1561-4
4. Parker LA, Gaisie O, Scatliff JH. Computerized and ultrasonographic findings in massive thymic hyperplasia. *Clin. Pediatr.*. 1985;24: 90-4.
5. Altar Z, Muraji T, Matsumoto Y, et al. Malignant mesenchymoma of the mediastinum presented as benign hyperplasia. *Pediatr. Surgical. Int.*, 1988;4:56-8.
6. Malone PS, Fitzgerald RJ. Aberrant thymus: a misleading mediastinal mass. *J. Pediatr. Surg* 1987;22:130-1.