

Case Report

Negative pressure pulmonary oedema: A rare complication following general anaesthesia

Zeeshan Waheed, Javaid Ahmed Khan

Section of Pulmonary & Critical Care Medicine, Department of Medicine, The Aga Khan University, Hospital, Karachi, Pakistan.

Abstract

An important cause of pulmonary oedema is Negative Pressure Pulmonary Oedema (NPPE) which characteristically develops soon after extubation from an endo-tracheal intubation. In this case report we identified a case of previously healthy man who was intubated for General Anaesthesia for extraction of impacted molar tooth. Soon after extubation he developed severe respiratory distress. Immediate diagnosis of NPPE secondary to post extubation laryngospasm was made. He was promptly treated with 100 percent oxygen via CPAP (continuous positive airway pressure) mask and within an hour he markedly improved and subsequently became asymptomatic.

NPPE is an important cause of morbidity and need for ICU admission in a healthy individual.

Keyword: General Anaesthesia, Post-extubation, Negative Pressure Pulmonary Oedema.

Introduction

Pulmonary oedema is a well-known emergency in medicine which needs early detection and prompt treatment. It is typically characterized by rales, jugular vein distention, frothy pink sputum, dyspnoea, with characteristic chest radiographs findings and progressive hypoxaemia.

Pulmonary oedema most commonly occurs due to cardiac insufficiency or heart failure, however the non cardiac cause of pulmonary oedema includes Acute Respiratory Distress Syndrome (ARDS), Neurogenic pulmonary oedema, Pulmonary oedema due to fluid overload /renal failure, Drowning and Transfusion-related pulmonary oedema.¹ One of the important cause of Non-Cardiogenic Pulmonary Oedema is Negative Pressure Pulmonary Oedema which characteristically develops soon after extubation from an endo-tracheal intubation and most likely results from patient's attempt to ventilate while he is obstructed usually due to laryngospasm, and thus generating

a marked increase in lung negative pressure and causing a series of events followed by a fluid shift from the vascular compartment to the alveoli and bronchial tree.²

Described below is a case of a previously healthy male who developed acute pulmonary oedema shortly after extubation following general anaesthesia.

Case Report

A 28 year old electronic engineer, with no past history of any significant illness was admitted in the daycare surgery for extraction of an impacted molar tooth under general anaesthesia. Patient was perfectly well before surgery, haemodynamically stable with no respiratory complaints. Anaesthesia was induced and endotracheal tube 7.5mm was inserted and patient was put on Control mode ventilation and anaesthesia was maintained by isoflurane. A total of 100 ml fluid was given during the procedure which lasted about an uneventful half an hour. Patient recovered from surgery and was extubated successfully. Within five minutes of extubation patient experienced severe respiratory distress. On examination there was frothing from the mouth with blood tinged secretion, respiratory rate was around 32/minute, heart rate 130/min and he was hypoxic with O₂ saturation around 70%. Chest auscultation revealed bilateral generalized coarse crackles. Immediate diagnosis of Negative-pressure pulmonary oedema secondary to post extubation laryngospasm was made. Immediately 100% oxygen was delivered via CPAP (continuous positive airway pressure) mask and at the same time injection furosemide 40 mg IV was given. Chest X-ray at this time showed bilateral alveolar infiltrates consistent with the diagnosis of pulmonary oedema (Figure-1). Patient

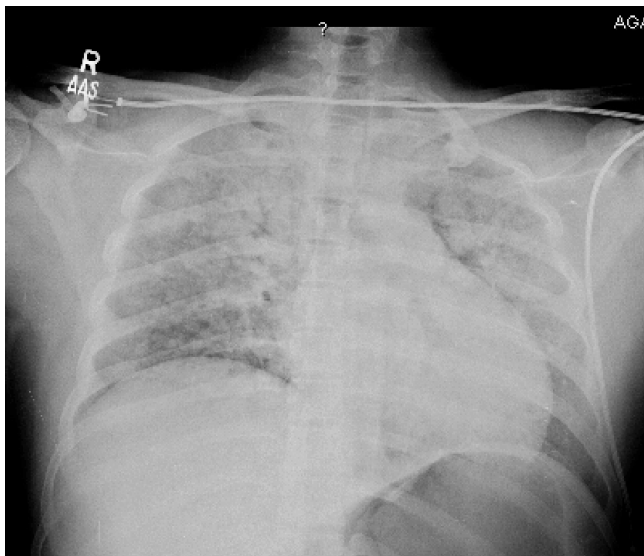


Figure-1: Bilateral alveolar infiltrates consistent with the diagnosis of pulmonary oedema.

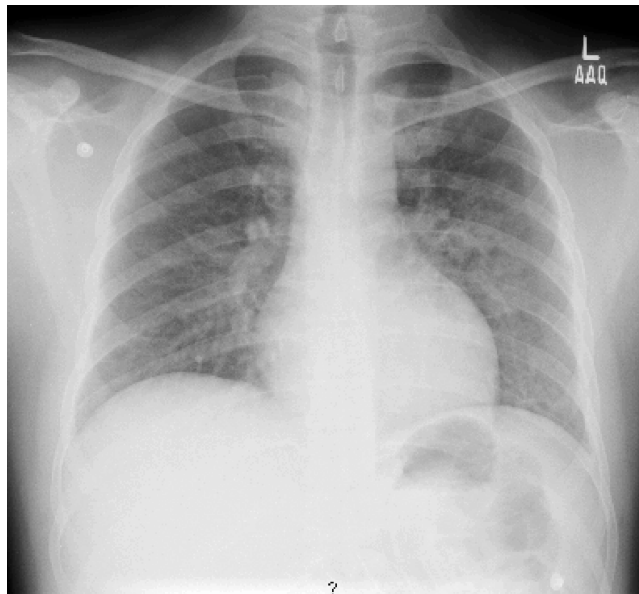


Figure-2: Resolution of infiltrates after twelve hours of event.

gradually started improving, within half hour his breathing settled, his oxygen requirements reduced to 5 litre by face mask maintaining O₂ saturations upto 98% and the crackles on his chest markedly decreased. Patient continued to improve, subsequently during the next 12 hours he was completely asymptomatic on room air, and his chest X-ray showed resolution of the infiltrates (Figure-2). He was discharged from the hospital the next day.

Discussion

Negative pressure pulmonary oedema secondary to upper airway obstruction in adults was first reported in literature in 1977 by Oswalt et al.³ All three patients of Oswalt were secondary to upper airway obstruction (tumour, hanging and strangulation) but none of them were involved in general anaesthesia. Negative pressure pulmonary oedema secondary to post-extubation laryngospasm was first reported in adults by Jackson et al in 1980.⁴ Since then a few case series have been reported.⁵

There is not much data on this rare complication of general anaesthesia from Pakistan, till now only two case reports have been published in the literature.^{6,7} Both of these cases were presented as pulmonary oedema after general anaesthesia because of upper airway obstruction e.g. patient clenched her teeth on the endo-tracheal tube (ETT) which resulted in complete airway obstruction leading to pulmonary oedema. Our case is unique in presentation as he developed this complication after the ETT was removed due to the severe laryngospasm which he developed post-extubation.

The common pattern in these cases is the occurrence

of an episode of airway obstruction at emergence from general anaesthesia, followed by the rapid onset of respiratory distress, and other symptoms pulmonary oedema. Patient had rapid and complete resolution of both clinical and radiological features within 24 hours. The upper airway obstruction usually results from laryngospasm but other reported causes include epiglottitis, bilateral vocal cord palsy, acromegaly, goitre and obstruction of the endotracheal tube.⁸

The mechanism of pulmonary oedema secondary to upper airway obstruction involves multiple factors. Two different mechanisms have been proposed for the development of pulmonary oedema in the setting of upper airway obstruction. One theory is that postobstructive pulmonary oedema is caused by significant fluid shifts due to changes in intrathoracic pressure.³ Negative intrathoracic pressure is generated in the chest when a patient attempts to inspire against a closed glottis or obstructed airway. The short-term drop in intrathoracic pressure increases the venous return to the right side of the heart, which in turn increases pulmonary venous pressure. This increase in pressure in the venous circulation creates a hydrostatic transpulmonary gradient with fluid moving from high pressure (pulmonary venous system) to low pressure (pulmonary interstitium and airspaces).^{3,9}

The second proposed mechanism involves the disruption of the alveolar epithelial and pulmonary microvascular membranes from severe mechanical stress, leading to increased pulmonary capillary permeability and protein-rich pulmonary oedema.^{3,9}

Differential diagnoses of negative-pressure pulmonary oedema secondary to post extubation laryngospasm include aspiration pneumonitis secondary to aspiration of gastric contents, occult cardiac disease leading to cardiogenic pulmonary oedema, fluid overload due to excessive fluid resuscitation and Anaphylaxis secondary to anaesthetic drugs.⁸ Out of these, Aspiration can produce a clinical picture similar to that seen in negative-pressure pulmonary oedema, however rapid onset and resolution of radiological changes is not a feature of aspiration.¹⁰

Regarding the treatment of negative-pressure pulmonary oedema the important principle is early application of positive pressure to the airways. Treatment modalities include Nasal bi-level positive airway pressure (BiPAP), mask continuous positive airway pressure (CPAP) and rarely intubation and mechanical ventilation with PEEP. Diuretics are often administered but their role is uncertain.⁵ Usually all cases of negative-pressure pulmonary oedema respond well to the above mentioned therapies and the condition resolves clinically and radiologically within 24 hours.⁸

In conclusion, post extubation negative-pressure pulmonary oedema secondary to upper airway obstruction is an important cause of morbidity, unexpected intensive care admission and occasionally mortality in young and healthy individuals. It is a well described but probably under-recognized clinical syndrome, the exact mechanism of which is still unclear. Early recognition of the condition is the key point which allows prompt application of positive airway pressure leading to rapid resolution of the condition. It is expected that these case reports and discussion will heighten the awareness of this relatively poorly recognized syndrome.

References

1. Trujillo MH, Fragachan CF, Tortoledo F. Noncardiogenic pulmonary oedema following accidental near-hanging. *Heart Lung* 2007; 36: 364-6.
2. Yanko R, Garfunkel AA, Kaufman E. Pulmonary oedema: a complication following dental treatment under general anaesthesia. *Anesth Prog* 1996; 43: 61-3.
3. Oswalt CE, Gates GA, Holmstrom MG. Pulmonary oedema as a complication of acute airway obstruction. *JAMA* 1977; 238: 1833-5.
4. Jackson FN, Rowland V, Corssen G. Laryngospasm induced pulmonary oedema. *Chest* 1980; 78: 819-21.
5. Deepika K, Kenaan CA, Barrocas AM, Fonseca JJ, Bikazi GB. Negative pressure pulmonary oedema after acute upper airway obstruction. *J Clin Anesth* 1997; 9: 403-8.
6. Abbas S M, Hoda M Q. Negative Pressure Pulmonary Oedema: Case Report. *J Pak Med Assoc* 2004; 54: 396-8.
7. Hussain RM, Mubeen M, Raza N. Negative pressure pulmonary oedema - an unusual potential hazard of ENT surgery. *Pak J Otolaryngol* 2008; 24: 23-4.
8. McConkey PP. Postobstructive pulmonary oedema - a case series and review. *Anaesth Intensive Care* 2000; 28: 72-6.
9. Koh MS, Hsu AA, Eng P. Negative pressure pulmonary oedema in the medical intensive care unit. *Intensive Care Med* 2003; 29: 1601-4.
10. Guinard P. Laryngospasm induced pulmonary oedema. *Int J Pediatr Otorhinolaryngol* 1990; 20: 163-8.