

## **Traumatic hip dislocations in children**

Muhammad Saeed Minhas

Department of Orthopaedics, Jinnah Postgraduate Medical Centre, Karachi.

### **Abstract**

**Objectives:** To evaluate clinical features, treatment and relationship to the time period between dislocation, reduction and early complications of traumatic dislocation of hip in children.

**Methods:** Case series conducted at Jinnah Post Graduate Medical Centre Karachi from July 2005 to August 2009. Children with traumatic hip dislocation up to fifteen years of age who presented in last four years were included in this study. Their clinical information, etiology, associated injuries, duration, method of reduction and early complications are evaluated through emergency room proforma and indoor record. Follow up of patient was updated in outpatient department.

**Results:** We had eight patients, six boys and two girls. Youngest 2.4 years and eldest was 12 years with mean age of  $6.2 \pm 3.8$  years. All presented with posterior hip dislocation. Etiology was road traffic accident in two and history of fall in remaining six patients. Average duration of time between dislocation and reduction was 19 hours range 3-72 hours. Dislocated hips were reduced under General Anaesthesia in two patients and under sedation analgesia in six patients. No complications were noted in eight cases with mean  $18.75 \pm 13.23$  months follows up.

**Conclusion:** Traumatic hip dislocation in children is not rare. Slight trauma causes dislocation in younger age and immediate closed reduction and Immobilization reduces complications (JPMA 60:1019; 2010).

### **Introduction**

The hip is a very stable ball and socket joint that is reinforced by ligaments and large muscles. Hip could dislocate posteriorly, which is the most common; anteriorly; and centrally through the acetabulum in the pelvis. To cause a posterior dislocation of hip a great deal of force is required to hit at flexed knee and hip. Hip dislocation accounts for 2-5% of all joints dislocations. Traumatic hip dislocation in children is rare, can occur after minimal trauma and it is extremely rare below 5 years of age, only 5% of all hip dislocations occur under 14 years of age.<sup>1</sup> The large series of traumatic hip dislocations in adults demonstrates that hip dislocations is 25 times less common in children than adults.<sup>2</sup> Generally younger children require less force to dislocate the joint due to a soft pliable acetabulum and ligamentous laxity. The trauma required to produce a hip dislocation in children can range from trivial injury as tripping or fall from same height to severe high impact injury as in motor vehicle accident.<sup>3</sup> Hip dislocations, regardless of their etiology, are orthopaedic emergencies that require immediate evaluation, diagnosis and treatment in children to minimize complications.<sup>4</sup>

### **Patients and Methods**

This report is based on evaluation of eight consecutive cases of traumatic dislocations of the hip joint from the

medical records at the department of Orthopaedic surgery Jinnah Post Graduate Medical Centre, Karachi from July 2005 to August 2009. All patients dealt in accident and emergency department were registered in a Proforma All patients below 15 years of age who reported to accident and emergency were evaluated. Age, gender, mechanism of injury was grouped as slight, such as fall from same level, moderate such as athletic trauma and severe as motor vehicle trauma. Clinical features were noted and associated injuries were checked. X-rays were performed and hip was reduced under either general anaesthesia or sedation plus analgesia. Time interval between dislocation and reduction was noted. Post reduction methods and duration of immobilization was assessed. Patients were examined for pain, limitation of motion, limb shortening or limp and for radiographic abnormalities. Patients were examined in follow up after every three months up to two years for early complications like myositis ossificans, instability and avascular necrosis. Patients indoor and outpatient department record was also evaluated for follow up.

All patients were examined by residents in Accident and emergency, clinical evaluation, Radiological assessment was done and closed reduction was achieved in six patients by sedation analgesia and general anaesthesia in two. Allis's method was used to reduce hip joint in all cases.<sup>5</sup> All patients were admitted in the ward. Various methods were used for post reduction immobilization like bed rest, skin traction, skeletal traction and hip spica cast for 3- 6 weeks.

## Results

Eight cases of traumatic hip dislocation in children below 15 years of age were recorded in last four years. There were six boys and two girls. Youngest patient was 2 years 4 months and oldest 12 years of age. Mean age was  $6.2 \pm 3.8$  years. Boys were involved three times more often than girls. Mechanism of injury was slight in 4, moderate in 3 and severe in one. They were slight in 50% of cases and in younger age group below 7 years of age. The severity of injury increased with age. Right hip was involved in two and left hip in six, and all were posterior dislocations. There was no case of fracture dislocation. Time duration between dislocation and reduction ranged from three hours to three days (mean  $18.62 \pm 13.23$  hours). Diagnosis was made within first 12 hours in 5 patients, after 24 hours in three. In two cases it was due to delayed consultation. The interval before reduction was less than 24 hours in five cases and in other three cases from 24 to 72 hours. All dislocations were reduced by Allis's method, six patients by sedation/analgesia and two under general anaesthesia (Case 2 and Case 8 Table-1).

Associated injuries were present in two cases etiology was motor vehicle accidents in both cases (Case 1 and Case 8 in Table-1). Case 1 was the youngest case in our series. He had head injury and reported to hospital within two hours of the accident. He was admitted and kept under observation by neurosurgery department. Diagnosis of associated Posterior hip dislocation was made after 24 hours (Figure-1) and hip

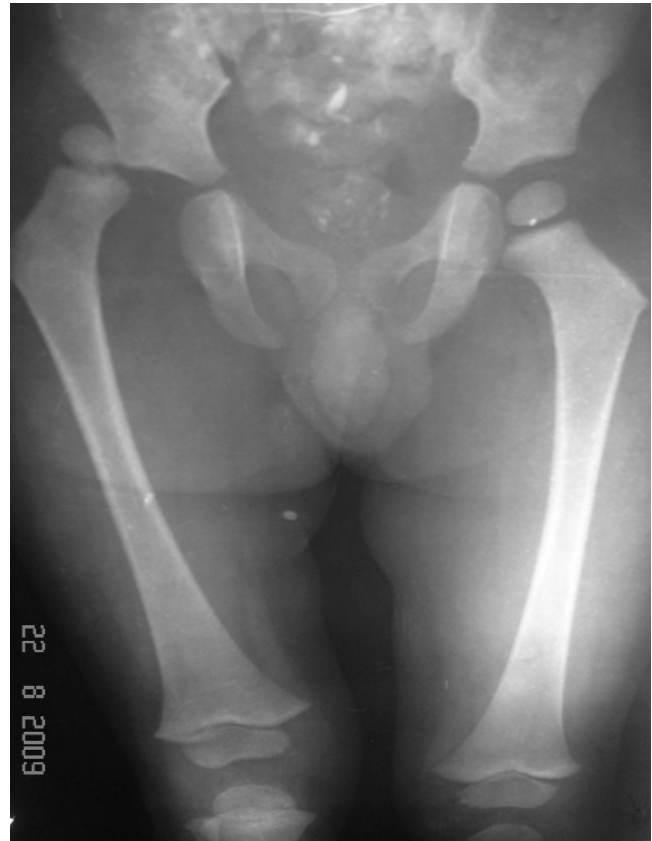

Figure-1: Traumatic dislocation Right Hip in 2 years and 4 months old boy.

Table-1: Characteristics of patients with hip dislocations.

Number	Age in years	Sex	Side	Type	Type of trauma	Time injury to reduction	Associated injury	Treatment	Follow up complications
1	2.4	Boy	Right	Posterior	Hit by car	24 hours	Minor Head injury	Closed reduction, Sedation & analgesia, hip Spica	10 months nil
2	12	Girl	Left	posterior	Fall while playing	5 hours	Nil	Closed Reduction, General Anesthesia, Skin Traction	11 months nil
3	3	Boy	Left	posterior	Fall Playing	4 hours	Nil	Closed reduction, Sedation & analgesia Hip spica	15 months nil
4	12	Boy	Left	Posterior	Fall off bicycle	24 hours	Nil	Closed reduction, Sedation and analgesia Traction, hip spica	18 months nil
5	5	Boy	Left	posterior	Fall from sofa	5 hours	Nil	Closed reduction, Sedation & analgesia Hip Spica	2 years nil
6	3.5	Girl	Left	Posterior	Fall playing	72 hours	Nil	Closed reduction, Sedation & analgesia Hip Spica	2 years nil
7	5	Boy	Right	Posterior	Fall playing	12 hours	Nil	Closed reduction, Sedation & analgesia Hip Spica	3 years nil
8	7	Boy	Left	Posterior	Hit by motor bike	3 hours	Fracture distal tibia fibula	Closed Reduction, General Anaesthesia, skin traction & hip spica	3 years nil

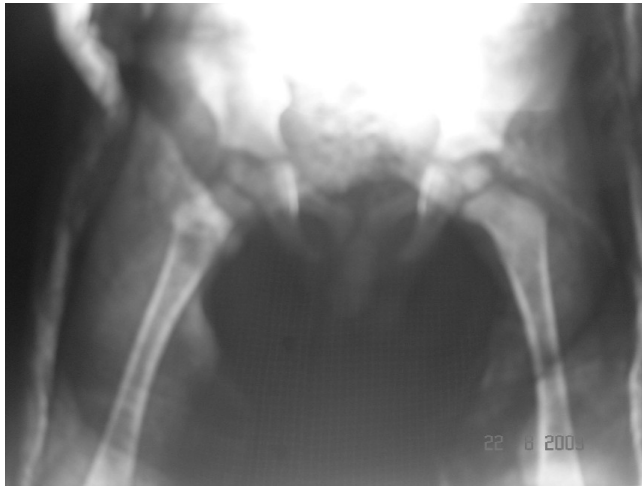


Figure-2: Closed concentric reduction in hip spica cast.

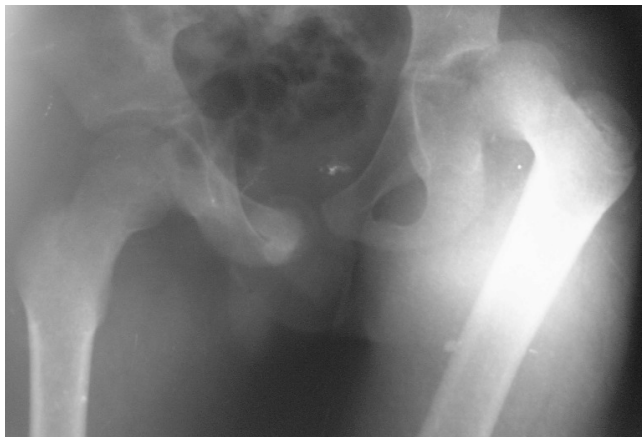


Figure-3: Traumatic dislocation left hip in 12 years old boy.

was reduced under sedation analgesia. Post reduction hip was examined to be congruent and stable. Hip spica was applied for four weeks (Figure-2). Case 8 (Table-1) sustained severe trauma after being hit by a motor bike. He had a posterior hip dislocation associated with closed fracture of distal tibia and fibula. Closed reduction of hip and fracture tibia and fibula was achieved under general anaesthesia and a hip spica cast was applied for six weeks.

Post reduction, patients were kept immobilized in bed for 3-6 weeks, and all were advised non weight bearing of the affected limb for four to six weeks from day of reduction. Case 4 (Table-1) was an active boy, 12 years of age with left posterior dislocation of hip (Figure-3). He was kept on skeletal traction through proximal tibia with 5 kg weight for four weeks and then mobilized. Case 2 was a 12 years old girl (Table-1) who presented with posterior hip dislocation. She was reduced under general anaesthesia and kept on skin traction for four weeks. Hip spica was applied after reduction

for 4 weeks in five patients and for 6 weeks in case 8 (Table-1) with associated same side distal tibia fibula fracture.

Patients were examined on follow up for pain, limp, range of movements and radiologically for incongruence or signs of avascular necrosis. Ficat stages of bone necrosis of femoral head were noted.<sup>6</sup> All patients were pain free with full range of movements and no limp after three months of hip dislocation. Functional results were good in all cases. Plain radiographs were performed in all after every three months and all patients were found with congruent hip joint with no evidence of avascular necrosis. No early complication was seen in any of our patients. Mean follow up of the patients recorded was  $18.75 \pm 13.23$  months (Table-1).

## Discussion

Traumatic hip dislocation is unusual in children.<sup>3</sup> Posterior traumatic hip dislocation occurs in children with minimal trauma and can be reduced without effort under sedation and analgesia and chances of complications are rare. It is usually seen in the pre-adolescent age group between seven and ten years of age.<sup>2</sup> It is rarely seen below five years of age.<sup>1</sup> In this case series five patients age was of five or under, and youngest patient was two year and four months old which is a rare age for traumatic hip dislocation. Dislocation has been associated with road traffic accidents; fall from height or with sports activities.<sup>7</sup> Males are affected four times more than female.<sup>8</sup> Several studies have shown that there is relation between the patient's age and the severity of trauma leading to dislocation. In bigger series patients were divided in two age groups 2-8 years and 8-15 and it was observed that mechanism pattern and complication are different in the two age groups.<sup>9</sup> Nearly same observations were made in our patients regarding gender and mechanism of injury and six patients were 2-8 years age group.

Slight trauma or Low energy trauma in younger age group result in traumatic hip dislocation because of more elastic periarticular structures. Insignificant falls as in our cases in younger age group with mild symptoms may lead to delay in reporting to hospital, delay in diagnosis and reduction of the joint. One case in our series, detained in accident and emergency department for head injury, was diagnosed after 24 hours, due to minimal symptoms and less obvious clinical signs and distracted forehead injury. Children with posterior dislocation of hip joint present with same clinical features as in adults. Referred pain to knee joint in normal looking knee and when associated with other injuries clinical features are missed and diagnosis is delayed. A thorough physical examination is required in a child unable to bear weight to reduce the chance of missing hip injury. Fracture dislocations are exceptional in children due to plasticity of the joints and also not seen in our cases. Early complications that may occur after traumatic dislocation of

hip include neurovascular damage, associated fractures, epiphyseal injuries, inability to reduce and non concentric reduction.<sup>10</sup> Late complications can be myositis ossificans, avascular necrosis, coxa magna, traumatic arthritis, epiphyseal fusion and recurrent dislocation.<sup>1,11</sup> AVN may be diagnosed until 24 months after injury and patients at least should be followed up to that period.<sup>10</sup> Plain radiography is sufficient to make a diagnosis after clinical examination and to confirm joint congruency after reduction. CT scan or MRI is rarely required in non congruent dislocation or recurrent dislocation.<sup>12,13</sup>

Treatment of dislocated hip is immediate relocation of hip joint preferably and especially in adolescent under General anaesthesia, to minimize the complication of AVN which is reported to be around 10% after hip dislocations.<sup>14</sup> Contributing factors for AVN are advance age of the patient, severity of trauma, delayed time to reduction and fracture dislocation. In younger age group joint can be reduced without effort under sedation and analgesia.<sup>15</sup> In our series general anaesthesia was only given to two, one adolescent girl of twelve years, another patient with associated fracture tibia fibula, required closed reduction and immobilization as well.

Reported incidence of the nerve damage mainly sciatic nerve secondary to traumatic hip dislocation in children is around 5%.<sup>12</sup> Neurologic examinations were normal in all cases in our study. Recurrent dislocation is also common in children due to the incomplete healing of the posterior capsule of the hip joint. AVN of the femoral head in children younger than 12 years old secondary to post traumatic hips dislocation produces changes similar to Legg-Calve disease such as sclerosis, coxa plana, coxa magna and coxa brevia. Osteoarthritis and hetrotopic ossification with posterior dislocation of the hip in children are very rare complications.<sup>16</sup>

Rehabilitation after reduction is different in literature. Hamilton et al suggested that resting time was important and rest time had been 3-8 weeks.<sup>3</sup> This is the time for synovial irritation to resolve and soft tissue healing around hip joint. Schlickewi et al suggested that reduction time is more important than post reduction rest time.<sup>17</sup> If reduction achieved earlier avascular necrosis incident is lowered and prognosis is better.<sup>17</sup> Most reports find no benefit from a period of non weight bearing after reduction and the non weight bearing period need not be longer than 4 weeks.<sup>12,18</sup> In our study the patients were not allowed weight bearing before one month.

In our series younger age of the patients, lack of high energy trauma and absence of accompanying hip fracture reduced the occurrence of avascular necrosis. However chances of developing AVN can't be excluded as follow up

time period is short. Irreducibility is rare and open relocation is rarely performed which may be due to interposition of soft tissue.<sup>19</sup> Prognosis following the traumatic hip dislocation is better in children than in adults.<sup>11,20</sup>

## Conclusion

This case series highlights that traumatic dislocation of hip in children is not uncommon. A high index of suspicion is required for early recognition which needs a thorough examination of traumatic child. Every child with hip or knee trauma, with multiple injuries and with femoral shaft fractures should have a routine x-ray pelvis. Immediate closed reduction, preferably by Allis's method and Post reduction immobilization by traction or cast for at least four weeks prevent complications.

## References

1. Reigr H, Pennig D, Klein W, Grunest J Traumatic dislocation of the hip in younger children. Arch Orthop Trauma Surg 1991; 110: 114-7.
2. Schlonsky J, Miller PR. Traumatic hip dislocations in children. J Bone Joint Surg Am 1973; 55: 1057-63.
3. Hamilton PR, Broughton NS. Traumatic hip dislocation in childhood. J Pediatr Orthop 1998; 18: 691-4.
4. Salisbury RD, Eastwood DM. Traumatic dislocation of hip in children. Clin Orthop Relat Res 2000; 377: 106-11.
5. Delee Jc. Fracture and dislocation of hip. In Rockwood C A jr, Green DP, Bucholz RW, et al, (eds). Rockwood and Green's Fracture in adults, 4th ed, Philadelphia: Lippincott-Raven, 1996; pp 3289.
6. Ficat RP, Arlet J. Necrosis of the femoral head. In Hungerford D.S eds. Ischemia and necrosis of bone. Baltimore, Md: Williams and Wilkins, 1980; pp 171-82.
7. Haugeaod K, Thonsen P B. Traumatic hip dislocation in children. Follow up of 13 cases. Orthopaedics 1989; 12: 375-8.
8. Rees D, Thompson S K. Traumatic dislocation of the hip in minirugby. BMJ 1984; 289: 19-20.
9. Loupasis G, Morris EW. Asymetric bilateral traumatic hip dislocation. Arch Orthop Trauma Surg 1998; 118: 179-80.
10. Barquet A. Natural history of avascular necrosis following hip dislocation in children: a review of 145 cases. Acta Orthop Scand 1982; 53: 815-20.
11. Funk FJ Jr. Traumatic dislocation of the hip in children: factors affecting prognosis and treatment. J Bone Joint Surg 1962; 44-A: 1135-45.
12. Cornwall R, Radomishi TE. Nerve injury in traumatic dislocation of the hip. Clinical Orthop 2000; 377: 84-91.
13. Pearson DE, Mann RJ. Traumatic dislocation in children. Clin Orthop Relat Res 1973; 92: 189-94.
14. Gartland JJ, Benner JH. Traumatic dislocations in lower extremities in children. Orthop Clin North Am 1976; 7: 687-700.
15. Freeman GE Jr. Traumatic dislocation of the hip in children: a report of seven cases and review of literature. J Bone Joint Surg (Am) 1961; 43: 401-6.
16. Epstein HC. Traumatic dislocation of the hip. Clin Orthop Relat Res 1973; 92: 116-42.
17. Schlickewi w, Elsassser B, Mullaji AB, Kuner EH. Hip dislocation without fracture: traction or mobilization after reduction? Injury 1993; 24: 27-31.
18. Barquet A. Traumatic hip dislocation in childhood: A report of 26 cases and a review of the literature. Acta orthopaedica 1970; 50: 5 549-53.
19. Villae R, Odent T, Pannier S, Pauthier F, Laumour F, Glorion C. Traumatic hip dislocation in childhood. J Pediatr Orthop 2005; 25: 138-44.
20. Gurkan V, Dursun M, Orhun H, Sever GB, Kilickap C, Berkel T. Evaluation of pediatric patients with traumatic hip dislocation. Acta Ortho Tramadol Turc 2006; 40: 392-5.