

Faecal Empyema

R. Layeeque, S. Hussain, M. Arshad, F. Moazam (Department of Surgery, Aga Khan University Hospital, Karachi.)

Introduction

Faecal contamination of the pleural cavity is an uncommon event. Few cases^{1,2} of faecal collection in pleural cavity have been described in the past. In majority of such reports anatomical explanation of faeces found in pleural cavity was evident. We report a case of faecal empyema secondary to retroperitoneal abscess which appeared to have occurred in the absence of an anatomical communication between the two cavities, The possible routes of communication between the retroperitoneum and the pleural cavities have been discussed which may explain such an occurrence.

Case Report

A ten years old boy was admitted to a local hospital with mild abdominal pain and a mass in the right iliac fossa for three days. On the day of admission while playing soccer, the child gave a history of being kicked in the right flank. He was treated conservatively with a provisional diagnosis of appendicular mass. His chest and abdominal Xrays were normal. Three days later he developed respiratory distress associated with fever and rigors. A repeat chest Xray revealed a right sided pleural effusion. A tube thoracostomy was performed through 5th ICS and drained faecal fluid. The tube continued to drain 350-400cc of faecal fluid daily and the child became progressively septic over the next five days. At this point he was referred to the Aga Khan University Hospital (AKUH) for further management.

At the time of presentation to AKUH the patient was found to be septicaemic with a right sided chest tube draining faecal fluid which on analysis, revealed bile and undigested organic fibers. The abdomen was soft and non-tender to palpation with no signs of peritonitis. An intravenous contrast enhanced computerized tomographic scan revealed a right retroperitoneal abscess containing air. The oral contrast appeared to be leaking from the caecum, extending upwards towards the right pleural cavity (Figure 1).

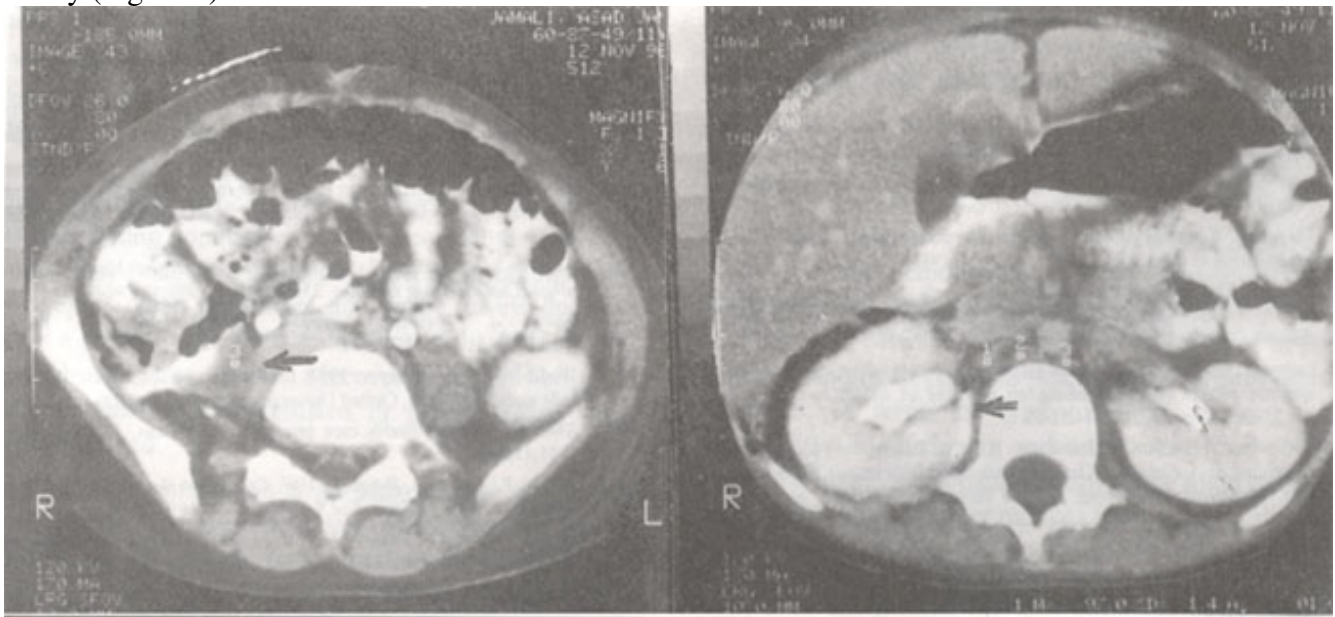


Figure 1. CT scan showing (A) retroperitoneal collection of pus (arrow) and (B) extravasated contrast medial to right kidney (arrow), note the air fluid level in the retroperitoneum.

As there were no signs of peritonitis, the retroperitoneum was explored first through a flank incision to avoid peritoneal contamination. This revealed a retroperitoneal abscess with a perforation in the posterior wall of an otherwise healthy caecum. The appendix was found to be normal (Figure 2).

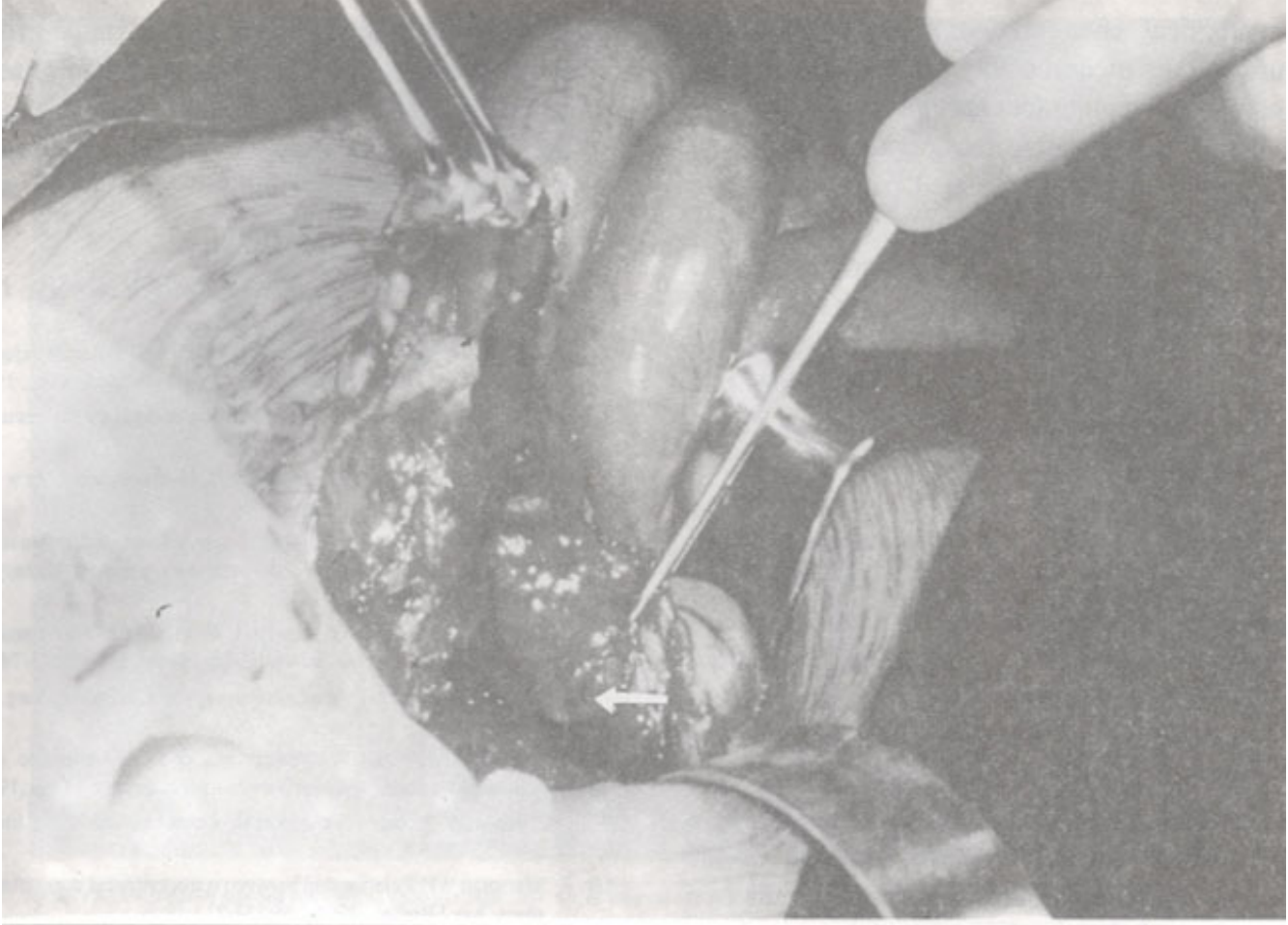


Figure 2. Peroperative photograph showing normal appendix away from the perforation in the posterior wall of the caecum (arrow)

The abscess was tracking up around the right kidney. Drains were left in this case. Furthermore, the patient described here had a normal, non-inflamed appendix.

The incision was extended anteriorly for a diverting ileostomy. The abdominal cavity was found to be clean with no contamination and the diaphragm was intact with no evidence of the chest drain penetrating to diaphragm. A divided ileostomy was performed approximately 10cms from the ileocecal junction. The right pleural cavity was explored through a minithoracotomy to break all pleural loculi and allow better drainage of the faecal empyema. His immediate postoperative period was satisfactory and the faecal discharge through the drains diminished over the next 3 to 4 days. As the child remained febrile, a repeat CT scan was performed. This revealed a residual collection in the right hemithorax which resolved after a thoracotomy and drainage. He was discharged home 10 days later on enteral feed. Four months later he was admitted for elective reversal of the stoma. He is doing well 6 months following his last procedure.

Discussion

Faecal contamination of the pleural cavity is an uncommon event. It was first reported in 1976 by Kisler et al² who described three prisoners who developed empyema thoraces following self injection of faecal contaminated solutions into their pleural cavities. In 1983, Fareelly et al¹ reported a patient who

developed a faecal collection in the pleural cavity following rupture of the transverse colon which had herniated through a right sided Bochdaleck defect. In both reports, an anatomical explanation of faeces found in the pleural cavity was evident.

The possibility of a communication between the pleural and the peritoneal cavity has often been postulated. A number of cases have been reported in which a retroperitoneal urinoma has resulted in accumulation of urine in the pleural cavity^{3,4}. Leakage of air from the pleural cavity into the retroperitoneum^{5,6} and a flow of pancreatic fluid in the opposite direction⁷ have also been described raising the possibility of unrecognized anatomical communications between the two cavities. Currently there are only two types of communication recognized between the pleural and peritoneal cavities. These include lymphatic drainage and communication along vascular foramina with subsequent rupture into the pleural cavity. Although a direct communication has also been postulated, attempts to demonstrate this have been unsuccessful. Imaging studies of the retroperitoneum have failed to demonstrate a spill of contrast material from the retroperitoneum into the pleural space^{2,8}. In a review of 22 patients, Salcedo⁹ has suggested that a true anatomical channel does exist between the retroperitoneum and the pleural cavity. He based this on his observation that most urinothoraces accumulate ipsilaterally in the chest, occur rapidly after retroperitoneal urinoma formation, reaccumulate after repeated paracentesis and resolve soon after urinary diversion. However, Marsmen¹⁰ offers another explanation for this phenomenon. He emphasized the importance of the pleural sinus which may extend more caudally than suspected. His report described a patient who developed a pneumothorax following fine needle aspiration of the pancreas through the left pararenal space. He emphasized to the interventional radiologists the risk of rupture of this unsuspected sinus during retroperitoneal procedures. In 15 out of 22 patients reported by Salcedo, urinothoraces followed invasive procedures and may have resulted from a puncture of the pleural sinus. It can be postulated that in the patient reported here, the initial trauma may have caused perforation of the posterior caecal wall with collection of the retroperitoneum after a thorough washout and closure of the caecal perforation.

However, the faecal empyema secondary to a retroperitoneal abscess appears to have occurred in the absence of an anatomical communication between the two cavities. To our knowledge, such an event has not been reported previously. Empyema due to gut organism in association with appendicitis has been described^{7,11} but without containing faecal particulate material as present in contents in the retroperitoneum. Subsequent enzymatic lysis of the pleural sinus may have allowed passage of the faeculent retroperitoneal fluid into the pleural cavity.

References

1. Farrelly G, Fitzgerald R, Mathews T Meconium thorax. *J. Pediatr. Surg.*, 1983;18:623-24.
2. Kissler F, Marsoner F, Stefenelli N, et al. Self inflicted injuries by injecting contaminated solutions through the chest wall. *Med. Klin.*, 1976;71:1200-3.
3. Belis JA, Milam DF. Pleural effusion secondary to ureteral obstruction. *Urology*, 1979; 14:27-29.
4. Comere JJ Jr., Miller WT, Murphy JJ. Hydronephrosis as a cause of pleural effusion. *Radiology*, 1968;90:79-84.
5. Altman AR, Johnson TH. Pneumoperitoncum and pnemoretroperitoneum. Consequences of positive end-expiratory pressure therapy. *Arch. Surg.*, 1979;1 14:208-11.
6. Powner DJ, Snyder Jv, Morris CW, et al. Retroperitoneal air dissection associated with mechanical ventilation. *Chest*, 1976;69:73-74.
7. Herline A, Burton H. Appendicitis: empyema. *J. Pediatr. Surg.*, 1994;29:1623-25.
8. Redman JF, Arnold WC, Smith PL, et al. Hypertension and urinothorax following an attempted

percutaneous nephrostomy. J.Urol., 1982;128:1307-9.

9.Salcedo JR. Urinothorax: report of 4 cases review of the literature. J. Urol., 1986;135:805-8.

10.Marsman WP. Relationship between retroperitoneal compartments and pleural sinus. Am.J.Radiol., 1996;166:722-23.

11.Law DK, Murr P, Bailey WC. Empyema: a rare presentation of perforated appendicitis. J.Am.Med.Assoc., 1978;240:2566-67.