

Endophthalmitis in paediatric penetrating ocular injuries in Hyderabad

Sameen Afzal Junejo, Munawar Ahmed, Mehtab Alam

Department of Ophthalmology, Liaquat University of Medical and Health Sciences, Jamshoro, Hyderabad, Pakistan.

Abstract

Objective: To determine the frequency, risk factors, and visual outcome of post traumatic endophthalmitis in children.

Methods: The study was conducted on patients less than fifteen years age, presenting with penetrating ocular injuries and associated with endophthalmitis. Anterior segment slit lamp examination and if possible posterior segment slit lamp examination with 90 D fundoscopes was performed. After completing necessary investigations, urgent surgical intervention was carried out.

Results: There were 43 registered patients with 29 (67.4%) males and 14 (32.6%) females. Twenty three (53.4%) children presented on the day of injury. Remaining 20 (46.6%) reported after first 24 hours. Twenty seven (62.7%) children presented with corneal wound, 11 (25.6%) had scleral entrance, and 5 (11.7%) patients had corneo scleral extension. Nineteen (44.1%) patients developed clinical evidence of endophthalmitis. Fifteen subjects with endophthalmitis completed six weeks follow up. Two (13.3%) subjects achieved final visual acuity (FVA) of 3/60. Four (26.7%) had only hand movements, 5 (33.4%) subjects were restricted to perception of light, and 2 (13.3%) patients developed phthisis bulbi.

Conclusion: Delayed arrival of patients in eye hospital with open globe injury may result in endophthalmitis (JPMA 60:532; 2010).

Introduction

Penetrating ocular trauma is one of the main causes of severe loss of vision in young adults and children leading to blindness.¹ According to WHO declaration, out of 55 million ocular injuries occurring each year worldwide, about 1.6 million patients become blind.²

Endophthalmitis is defined as inflammation of ocular cavities and it's adjacent structures accompanied by hypopyon, loss of retinal red reflex and vitritis.³

Infectious endophthalmitis after penetrating eye injury is among the most serious complications. It usually occurs due to invasion of infectious agents in the eye during trauma, following intraocular surgery, and some times due to endogenous spread of bacteria.⁴ Endophthalmitis following retention of intraocular foreign body for prolonged time is extremely serious, and may lead to severe loss of vision.⁵

Due to increased frequency of ocular trauma in our country, the incidence of infective endophthalmitis is relatively higher.⁶ In one local survey, among all admitted patients of different ages during the study of two years, the prevalence of traumatic infective endophthalmitis was about 4.5%.⁷ Other studies show the incidence declining from 17%⁸ to 6, 8%.⁹ More studies looking at endophthalmitis in children in the developing countries following ocular trauma are needed.

Methodology

A retrospective clinical analysis was conducted on

children suffering from penetrating eye injuries presenting to unit-III of Liaquat University eye hospital Hyderabad Pakistan, from January 2005 to June 2007 (thirty months).

The children of both sexes presenting for the first time during the study period were included. All the subjects with non-penetrating ocular injury, previous ocular trauma coming for follow up, and above fifteen years were excluded.

The initial examination was performed in outpatient emergency section by two senior ophthalmologists and four medical officers. After getting informed consent, the subjects were interviewed and assessed:

General history was taken which included, age, sex, residency, financial status, eye affected, exact time, location, extent and cause of trauma.

Use of corrective lenses was noted to rule out spectacle injury.

Physical examination of the eye was performed and the best corrected initial visual acuity (IVA) was documented for normal and injured eye, using Snellen's chart and E-chart for illiterate children.

Anterior segment Slit lamp examination, if possible, was performed to localize the site of injury. Posterior segment slit lamp examination with 90D and 78D fundoscopes was done on selected cases. Red fundus reflex through pupil was observed.

The intraocular pressure was measured by

applanation tonometer in selected cases to exclude ocular hypotony.

The associated endophthalmitis was confirmed with the evidence of hypopion, vitritis, vitreous exudates and retinal periphlebitis.

X-ray orbit antero-posterior and lateral view was done in all cases to rule out radio opaque intraocular foreign body. B-Scan ultrasonography was used in selected cases where opaque media obstructed posterior segment evaluation.

Type of Management:

After admission the injured eye was covered with plastic shield for protection. Emergency medications such as analgesics (paracetamol) and antiemetics (promethazine) were given. Antibiotic eye drops such as ofloxacin, chloramphenicol without preservative in minims were administered half hourly. Tetanus antitoxin injection was given at the dose of 700 to 1500 international units depending on the age of the child.

Urgent primary surgical repair for anterior segment was performed by either of two senior ophthalmic surgeons. All subjects with evidence of endophthalmitis were administered intra vitreal injection of vancomycin 1mg in 0.1 ml and ceftazidime 2.25 mg in 0.1 ml (through 27 gauge needle) after withdrawing 0.2 cc of vitreous if possible (through 23 gauge needle) 4 mm behind limbus at the conclusion of primary repair. Finally Gentamicin sulfate 20 mg, and betamethasone 4 mg was injected sub-conjunctivally. Secondary repair was done in selected cases. Topical ciprofloxacin 0.3%, dexamethasone 0.1% and atropine 1% eye drops were used after repair surgery. Systemic antibiotics were not used. 0.2 cc of undiluted vitreous aspirate already collected was sent for microbiological investigations.

The subjects with penetrating eye injury involving posterior segment with or without endophthalmitis were immediately referred to vitreoretinal surgeon for further management.

All patients were requested to complete postoperative follow up. The final visual acuity (FVA) was documented on sixth week post treatment out patient visit.

Result

A total of seventy eight (78) subjects with ocular trauma presented within the study period. Out of these forty three (55.1%) eyes received penetrating eye injuries. Boys were 29 (67.4%), and girls 14 (32.6%). Nine (21.0%) patients were within five years of age, 23 (53.4%) between 6 to 10 years, whereas 11 (25.5%) subjects were between 11 and 15 years. Twenty six (60.4%) children belonged to rural areas, and seventeen

(39.6%) were of urban residency. Nine (21.0%) subjects were using corrective spectacles. Two (4.6%) patients presented with diplopia after injury. Four (9.3%) subjects belonged to upper class, 11 (25.5%) to middle class and 28 (65.1%) had a lower socioeconomic status. All of the

Table 1: Source of Ocular Trauma: n=43.

Source %	Different Age Group in Years			Total with Percentage
	0-5	6-10	11-15	
Pencil	0	5	3	08 (18.6)
Stick	0	6	4	10 (23.2)
Glass	0	3	0	03 (06.9)
Scissor	2	1	0	03 (06.9)
Kitchen Knife	2	2	0	04 (09.4)
Screw Driver	0	0	2	02 (04.5)
Stone	0	0	4	04 (09.4)
Fall	2	2	1	05 (11.7)
Unknown	0	4	0	04 (09.4)

Table 2: Ocular Sites of Insult with associated findings: n=43.

Site of Entry	N/O Eyes	Percentage %
Cornea	27	62.7
Corneo scleral-Junction	11	25.6
Sclera	05	11.7
Associated Findings: n=43		
Endophthalmitis	19	44.1
Lid chymosis	33	76.7
Lid cut	06	13.9
Trauma to lower lacrimal system	02	04.6
Sub-conjunctival Haemorrhage	21	48.8
Iris prolapse	23	53.4
Uveal prolapse	18	41.8
Traumatic cataract	12	27.9
Hyphaema	17	39.5
Vitreous Haemorrhage	14	32.5
Retinal detachment	09	20.9
Peri orbital swelling	07	16.2

**Table 3: Visual Acuity Assessment
IVA (Patients with Penetrating Eye Injury n=43).**

Reading	No. of eyes	Percentage %
6/12	01	02.3
6/24	04	09.3
6/60 and above	09	20.9
Hand movement at 1 meter	13	30.3
Light perception	09	20.9
No light perception or did not co-operate	07	16.3
FVA -Pts with Endophthalmitis n = 15		
3/60 and above	02	13.3
Hand Movements	04	26.7
Light Perception	05	33.4
No Light Perception	02	13.3
Phthisis Bulbi	02	13.3

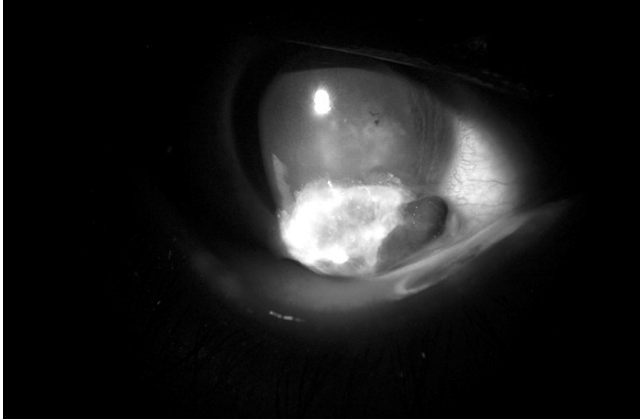


Figure: 1-A: Right eye penetrating eye injury associated with endophthalmitis.

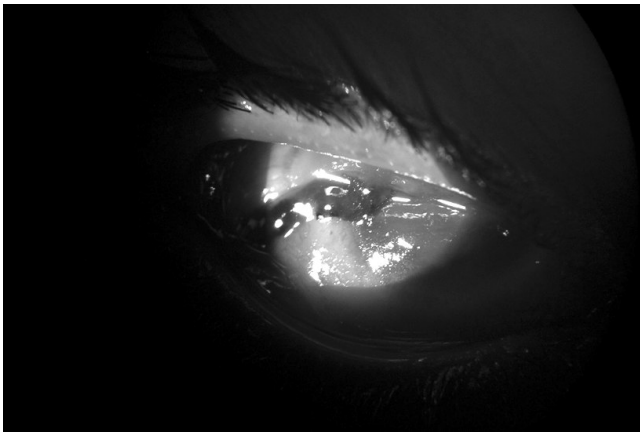


Figure: 2-B: Right eye corneo scleral penetration with endophthalmitis.

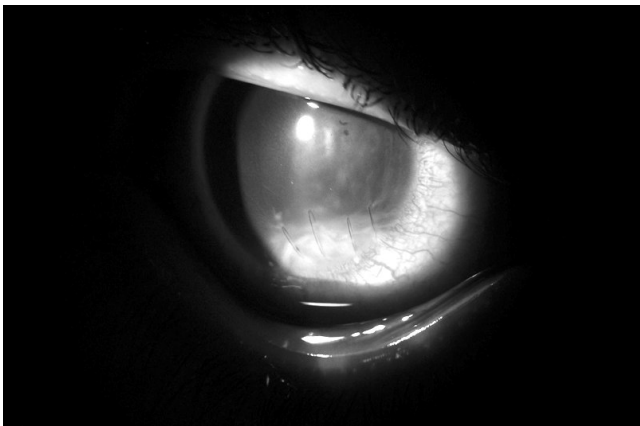


Figure: 2-B: Right eye corneo scleral penetration with endophthalmitis.

patients had unilateral eye injury. The most commonly affected age group was between 6 and 10 years (23 cases). The causative agents of ocular trauma in different age group are shown in Table-1.

Different ocular sites of injury with associated findings are summarized in Table-2. (Figure 1-A and 2-B).

Out of 43 registered patients, 23 (53.4%) children presented on the day of injury. Remaining 20 (46.6%) reported after first 24 hours. Only 15 patients out of 19 with Endophthalmitis completed post treatment follow up of six weeks (Figure 3-A). The presenting initial visual acuity (IVA) at admission and final visual acuity (FVA) at sixth week post operative follow-up is shown in Table-3.

The vitreous culture sensitivity examination revealed staphylococcus aureus in 9 (47.3%) subjects, staphylococcus epidermidis in 5 (26.3%), and fungus in 2 (10.5%) patients. The vitreous biopsy culture record of three children could not be retrieved.

Discussion

Penetrating eye injury is the common cause of endophthalmitis in children, perhaps due to increased immunogenic response to injury and delayed diagnosis. Children due to limited common sense and poor motor skills frequently suffer from severe eye injuries.¹⁰ They usually cannot explain their problem to their elders. Such a delayed response of a child after severe ocular trauma leads to the development of endophthalmitis.

According to different local studies, the incidence of traumatic endophthalmitis was 5.1%,¹¹ and 7.5%.¹² In a global survey the reported incidence of endophthalmitis after penetrating ocular trauma was 13.5%.¹³ According to one study from India, 54.1% eyes developed endophthalmitis following open globe injury.¹⁴ Another Indian author reported the incidence of post-traumatic endophthalmitis as 20.5%.¹⁵ In the present series 44.1% subjects developed endophthalmitis following penetrating eye injury which correlates with the study of Narang S from India.¹⁴

The microbial existence favours gram positive organisms (staphylococcus aureus and streptococcus) in traumatic endophthalmitis.^{16,17} In this study the vitreous biopsy examination revealed staphylococcus aureus as a causative organism in 44.4% subjects, and staphylococcus epidermidis in 22.2% children with endophthalmitis.

The incidence of post-traumatic endophthalmitis is higher in the subjects living in rural areas.¹⁸ In this study 60.4% patients with traumatic ocular penetration had rural residency, which is lower than one study from India where rural victims were 84.29%.¹⁹

Delayed repair of penetrating ocular trauma is among the major risk factors for development of infective endophthalmitis.^{14,20} In this series 46.6% subjects reported after first 24 hours of injury, which is quite consistent with the study from India where 48.62% victims reported after first 24 hours and had delayed primary repair.¹⁴

The other risk factors causing traumatic endophthalmitis are posterior location of wound, lens disruption, vitreous prolapse,¹⁸ and eyes with retained intraocular foreign body.²¹ In our study 25.6% children with corneo scleral injury, and 27.9% subjects having traumatic lenticular changes, were at high risk for development of endophthalmitis.

According to one study conducted in 2002, the final ambulatory vision was achieved in 52.86% subjects.²² In one local study,¹³ the final ambulatory visual outcome was 9.09% which is lower than the results of the present study where 13.3% subjects regained final visual acuity of 3/60 and above.

The urgent referral of a case to vitreo retinal surgeon is mandatory if penetrating eye injury is associated with signs of endophthalmitis. Intravitreal antibiotics alone have limited approach to control post traumatic endophthalmitis. Aggressive management in the form of vitrectomy along with intravitreal antibiotics in Paediatric post traumatic endophthalmitis cases is associated with a better clinical outcome.¹⁴

Conclusion

Paediatric post-traumatic endophthalmitis often shows poor response to treatment. This can be prevented by early referral and urgent therapeutic management.

References

1. Babar TF, Jan S, Gul L, Tariq M, Khan MY, Zaman MD. Pattern of paediatric ocular trauma in Hayatabad Medical Complex, Peshawar. *Pak J Med Res* 2006; 45:6-9.
2. Programme for the Prevention of Blindness and Deafness, World Health Organization (WHO). (Online) 2010 (Cited 2005 May) Available from URL: <http://www.who.int/pbd/en/>.
3. Reynold DS, Flynn HW Jr. Endophthalmitis after penetrating ocular trauma. *Curr Opin Ophthalmol* 1997; 8: 32-8.
4. Callegan MC, Gilmore MS, Gregory M, Ramadan RT, Wiskur BJ, Moyer AL, et al. Bacterial endophthalmitis: therapeutic challenges and host-pathogen interactions. *Prog Retin Eye Res* 2007; 26: 189-203.
5. Azad RV, Kumar N, Sharma YR, Vohra R. Role of prophylactic scleral buckling in the management of retained intraocular foreign bodies. *Clin Experiment Ophthalmol* 2004; 32: 58-61.
6. Jan S, Khan S, Mohammad S. Profile of Ocular emergencies requiring admission. *Pak J Ophthalmol* 2002; 18: 72-6.
7. Hussain I, Kundi NK. Visual outcome in infective Endophthalmitis. *J Med Sci* 2005; 13: 151-3.
8. Jonas J. B, Knorr HL, Budde WM. Prognostic factors in ocular injuries caused by intraocular or retrobulbar foreign bodies. *Ophthalmol* 2000; 107: 823-8.
9. Essex RW, YI Q, Charles PG, Allen PJ. Post-traumatic endophthalmitis. *Ophthalmol* 2004; 111: 2015-22.
10. Strahlman E, Elman M, Daub E, Baker S. Causes of Paediatric eye injuries. A population-based study. *Arch Ophthalmol* 1990; 108: 603-6.
11. Khan MD, Kundi M, Mohammed Z, Nazeer AF. A 6-year survey of intraocular and intraorbital foreign bodies in the North-west Frontier Province, Pakistan. *Br J Ophthalmol* 1987; 71: 716-9.
12. Chaudhry IA, Shamsi FA, Al-Harhi E, Al-Theeb A, Elzaridi E, Riley FC. Incidence and visual outcome of endophthalmitis associated with intraocular foreign bodies. *Graefes Arch Clin Exp Ophthalmol* 2008; 246: 181-6.
13. El-Asrar AM, Al-Amro SA, Khan NM, Kangave D. Visual outcome and prognostic factors after vitrectomy for posterior segment foreign bodies. *Eur J Ophthalmol* 2000; 10: 304-11.
14. Narang S, Gupta V, Simalandhi P, Gupta A, Raj S, Dogra MR. Paediatric open globe injuries. Visual outcome and risk factors for endophthalmitis. *Indian J Ophthalmol* 2004; 52: 29-34.
15. Singh DV, Sharma YR, Azad RV, RAjpat DT. Profile of Ocular Trauma at Tertiary Eye Centre. *JK Science* 2005; 7: 16-21.
16. Kunimoto DY, Das T, Sharma S, Jalali S, Majji AB, Gopinathan U, et al. Microbiologic spectrum and susceptibility of isolates: part II. Post traumatic endophthalmitis. Endophthalmitis Research Group. *Am J Ophthalmol* 1999; 128: 242-4.
17. Babar TF, Masud Z, Saeed N, Wazir I, Khan MD. A two years audit of admitted patients with the diagnosis of endophthalmitis. *Pak J Med Res* 2003; 42: 105-11.
18. Schmideder E, Mino de Kaspar, Klauss V, Kampik A. Post traumatic endophthalmitis after penetrating eye injuries. Risk factors microbiological diagnosis and functional outcome. *Ophthalmologie* 1998; 95: 153-7.
19. Narang S, Gupta V, Gupta A, Dogra MR, Pandav SS, Das S. Role of prophylactic intravitreal antibiotics in open globe injuries. *Indian J Ophthalmol* 2003; 51: 39-44.
20. Farr AK, Hairston RJ, Humayun MU, Mash MJ, Pieramici DJ, MacCumber MW, et al. Open globe injuries in children: a retrospective analysis. *J Pediatr Ophthalmol Strabismus* 2001; 38: 72-7.
21. Reynolds DS, Flynn HW Jr. Endophthalmitis after penetrating ocular trauma. *Curr Opin Ophthalmol* 1997; 8: 32-8.
22. Vasnaik A, Vasu U, Battu RR, Kurian M, George S et al. Mechanical eye (globe) injuries in children. *J Paediatr Ophthalmol Strabismus* 2002; 39: 5-10.