

# Radiologic Feeding Gastrostomy Placement: Experience in 23 Patients

T.U. Haq, S. M. F. Mosharraf, B. Ahmad, K. Munir, J. Yaqoob, U. Usman ( Department of Radiology, Aga Khan University Hospital, Karachi. )

## Abstract

**Objective:** To evaluate the safety, efficacy and complications of percutaneous gastrostomy catheter placement under fluoroscopic guidance for long term enteral feeding.

**Materials and Methods:** Between April 1998 to May 2002, 23 patients who had percutaneous gastrostomy catheter placement were retrospectively reviewed. Clinical indications for catheter placement included patients with neurologic disease, head and neck malignancy, and pulmonary disease patients. Placement of 12 - 14 Fr gastrostomy catheter was then accomplished with the Seldinger technique. The technical success, procedural complications were recorded.

**Results:** Twenty seven procedures, including revisions, were performed. The success rate for catheter placement was 100%. Revision was necessary in 7 (30%) instances in 7 patients. There was one (3.8%) major and 4 (14.8%) minor complications.

**Conclusion:** Fluoroscopically directed percutaneous placement of gastrostomy catheters is a safe and effective procedure (JPMA 53:62 ;2003).

## Introduction

Gastrostomy catheters are a well-accepted means of providing enteric access for patients with inadequate oral intake secondary to neurologic or gastrointestinal disorders.<sup>1-4</sup>

Different placement techniques have been described and include surgical, percutaneous endoscopic<sup>5,6</sup> and percutaneous radiologic techniques<sup>7</sup> with varying combinations of all three.<sup>8</sup> Percutaneous radiologic placement of gastrostomy and gastrojejunostomy catheters has continued to gain acceptance since their initial descriptions in 1981<sup>7</sup> and 1983<sup>9</sup> respectively.

This study evaluates the short and long term safety, efficacy and complications of fluoroscopically directed percutaneous placement of gastrostomy catheters.

## Materials and Methods

From April 16, 1998 to May 16, 2002, 23 patients (7 female and 16 male patients; age range 34-90 years) were referred to the radiology department for percutaneous placement of gastrostomy catheters under fluoroscopic guidance.

Clinical indications for catheter placement included 11 (47.8%) patients with neurologic disorders, 11 (47.8%) with head and neck malignancy, and 1 (4.7%) with pulmonary disease.

Routine preprocedural evaluation of all patients included chart review, directed physical examination, and fluoroscopic assessment of the abdomen. Coagulation profile was checked and corrected if deranged. Interventional radiologist performed catheter

placement under local anesthesia alone in most cases or with the addition of conscious sedation if necessary. None of the patients required general anesthesia. Prophylactic antibiotics were administered before the procedure.

**Technique**

After placement of a nasogastric tube (when possible) air insufflation was carried out. Appropriate site of puncture was marked with the help of fluoroscopy. A 16-gauge, 10-cm Seldinger needle was then used for gastric puncture. Gastropexy T sutures were applied (Figure 1).

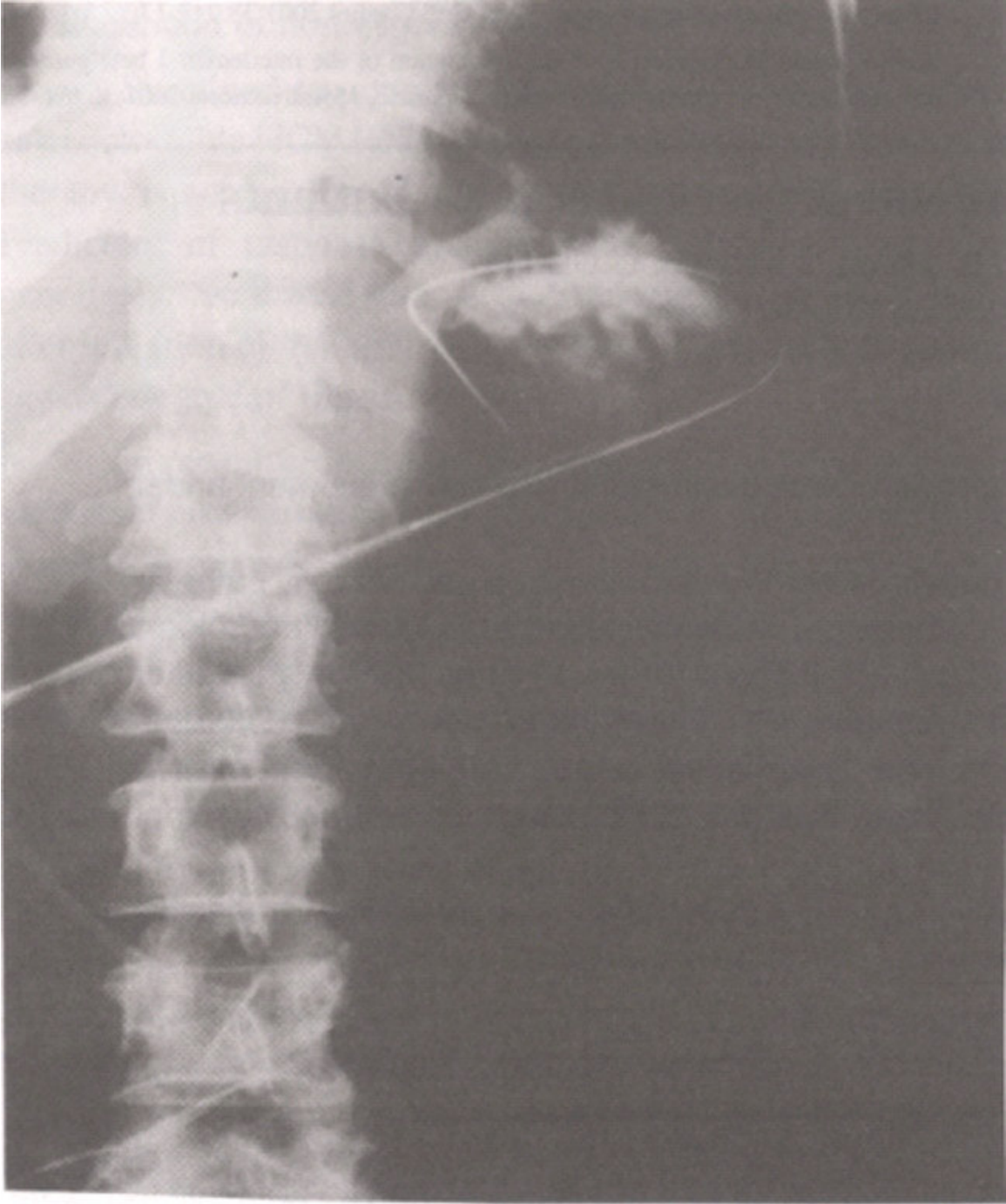


Figure 1. After initial puncture and Gastropexy with T suture, a wire advanced in the stomach.

Serial dilation of the percutaneous gastric tract to 12-14 Fr was performed, followed by placement of a 2-14 Fr gastrostomy catheter (Figure 2).

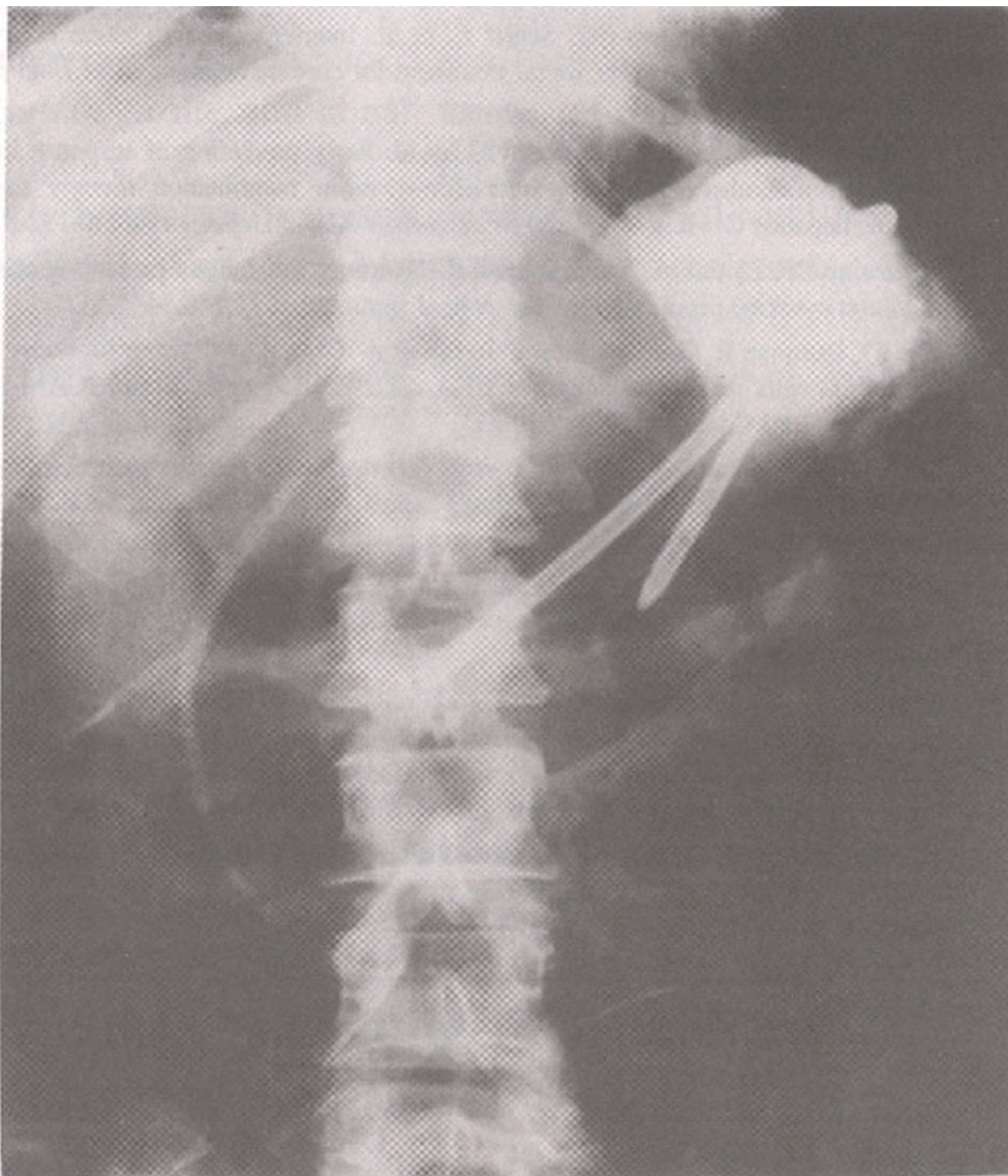


Figure 2. Gastrostomy catheter in position. Contrast injected via catheter to confirm its position in the stomach.

In patients where nasogastric intubation was not possible ( $n = 6$ ) due to obstruction, gastric insufflation was carried out with thin needle puncture of stomach under ultrasound guidance.

A retrospectively review of the radiology reports, the procedure sheet for the procedure in question, and the patients chart was done. This included evaluation of outpatient records of the hospital and the associated clinics. Patients seen for follow-up were questioned regarding tube function and care, and all patients (or their caregivers) were instructed on

tube usage and asked to contact the radiology department regarding any problems or questions.

Data collection criteria were defined at the study onset and included indications, initial placement success rate, for tube revision, and time for initiation of feedings. Major complications, follow-up interval, number of and indications and minor complications were defined at study onset and were taken as a representative composite of those noted in the literature, with a bias toward the clinical beliefs of radiologists and referring clinicians. Major complications were defined as peritonitis, hemorrhage requiring transfusion, surgical intervention or any other complication necessitating catheter removal (i.e. severe infection, ruptured viscus, or repeated aspirations). Minor complications were defined as peritonism, superficial stomal infection, external leak and tube malfunction requiring the change of catheter, pneumonia, and onset of aspiration or worsening of aspiration not requiring tube removal. Initial pain was not included in complications.

## **Results**

Overall, 27 procedures, including revisions, were performed in 23 patients. The success rate for gastrostomy catheter placement was 100%. Major complications arose in one (3.7%) patient who developed severe pain and peritonitis. Surgical intervention was carried out which revealed suture dislodgement in to the peritoneal cavity.

Minor complications were seen in 4 (14.8%) instances. In two cases there was pericatheter leakage, one had tube blockage and in one patient revision of procedure was carried out due to tube dislodgement. Three month follow-up data was available for 5 (21.7%) patients, 30 day follow up data for 2 (8.7%) and 14-days for 11(47.8%) patients. Overall, there were 7 total revisions in 7 patients .Two were due to pericatheter leakage, one due to blockage of tube and in 4 cases only tube readjustment was required. All were replaced without difficulty.

## **Discussion**

Surgical method of placement of a feeding gastrostomy tube, is no more practiced these days, due to requirement of general anesthesia and high morbidity and mortality rates. Endoscopic guided gastrostomy is another alternative method, which requires much more technical skills, is very uncomfortable to the patient and more expensive than fluoroscopic guided method. There is also a risk of aspiration during the procedure and traversing transverse colon, which usually does not happen with fluoroscopic guided method. The procedure under fluoroscopic guidance is still possible when there is upper airway or esophageal obstruction. In this study 6 patients had direct stomach puncture under ultrasound guidance in which NG insertion was not possible. The gastrostomy can also be converted into gastrojejunostomy under fluoroscopy.

Wollman et al<sup>10</sup> compared the complication rates of percutaneous endoscopic gastrostomy and fluoroscopically guided gastrostomy using meta-analysis, which demonstrated that fluoroscopically guided gastrostomy produced significantly fewer major complications than did percutaneous endoscopic gastrostomy (5.9% vs. 9.4%); no statistically significant difference was demonstrated for minor complications. The rate of

tube-related complications was higher for percutaneous endoscopic gastrostomy.<sup>6</sup> The theoretical advantages Of percutaneous endoscopic gastrostomy are that it can be performed at the bedside and that endoscopic diagnosis is possible during the procedure. However, two operators are needed for percutaneous endoscopic gastrostomy, and seeding of the tract with cells from head and neck cancer, although unusual, has been reported.<sup>11</sup> The major disadvantage of percutaneous endoscopic gastrostomy is that repeat endoscopy is required when tubes are exchanged, a frequent situation because tube disturbances are common.<sup>6</sup>

The problems defining major and minor complications and the variations noted in the literature were comprehensively addressed by Ryan et al.<sup>12</sup> Although the definitions of both major and minor complications in this study vary slightly from those reported in the literature but the overall comparison is possible.<sup>12,13</sup> No early complications were excluded from the data. This provides an important minimum time period of follow-up to ascertain that a fair complication rate has been reported.

**Our categorization was otherwise designed to follow**

that of Bell et al<sup>13</sup> closely and added only one additional criterion to their major complication list - that of any other complication requiring catheter removal aside from peritonitis, hemorrhage requiring transfusion, or external catheter leak requiring catheter removal The minor complication criteria similarly followed those of Bell et al<sup>13</sup> and Ryan et al<sup>12</sup>. with the following exceptions: Pneumonia or aspiration pneumonia responding well to a single course of antibiotics without repeat episodes requiring catheter removal was designated as a minor complication. Only if the pulmonary infection required catheter removal, it was considered a major complication. Also, inadvertent catheter removal by the patient or a caregiver was not considered a complication by itself. If any tube malfunction was noted otherwise in this category, appropriate placement into a complication category was made. Eleven (47.8%) patients were followed up for at least 2 weeks. Approximately two-thirds of our major and minor complications were found within 30 days of initial catheter insertion. Overall, the rate of complications after 30 days seems to be low, which supports the finding of Bell et al.<sup>13</sup>

## **Conclusion**

In conclusion, fluoroscopically directed percutaneous placement of gastrostomy catheters is a safe procedure and effectively provides a route of enteric access for feeding or upper gastrointestinal tract decompression. Major complication rates are low.

## **References**

- 1.Saini S, Mueller PR, Gaa J. et al. Percutaneous gastrostomy with gastropexy: experience in 125 patients. *Am J Roentgenol* 1990;154:1003-6.
- 2.O'Keefe FN, Carrasco CH, Charnsangavej C. et al. Percutaneous drainage and feeding gastrostomies in 100 patients. *Radiology* 1989; 72:341-3.
- 3.Halkier BK, Ho CS, Yee ACN. Percutaneous feeding with the Seldinger technique: review of 252 patients. *Radiology* 1989;171:359-62.
- 4.van Sonnenberg E, Wittich GR, Cabrera GR, et al. Percutaneous gastrostomy and gastroenterostomy II. Clinical experience. *Am J Roentgenol* 1986;146:581-6.

5. Gauderer M, Ponsky J, Izant R. Gastrostomy without laparotomy: a percutaneous endoscopic technique. *Nutrition* 1980;14:736-8.
6. Larson D, Burton D, Schroeder K, et al. Percutaneous endoscopic gastrostomy indications, success, complications and mortality in 314 consecutive patients. *Gastroenterology* 1987;93:48-52.
7. Preshaw RM. A percutaneous method for inserting a feeding gastrostomy tube. *Surg Gynecol Obstet* 1981;152:659-60.
8. Rosenzweig TB, Palestrant AM, Esplin CA, et al. A method for radiologic-assisted gastrostomy when percutaneous endoscopic gastrostomy is contraindicated. *Am J Surg* 1994; 168:587-590.
9. Ho CS. Percutaneous gastrostomy for jejunal feeding. *Radiology* 1983; 149:595-6.
10. Wollman B, D'Agostino HB, Walus-Wigle JR, et al. Radiologic, endoscopic and surgical gastrostomy: an institutional evaluation and meta-analysis of the literature. *Radiology* 1995;197:699-704.
11. Huang D, Thomas G, Wilson W. Stomal seeding by percutaneous endoscopic gastrostomy in patients with head and neck cancer. *Arch Otolaryngol Head Neck Surg* 1992; 118:658-59.
12. Ryan JM, Hahn PF, Boland GW, et al. Percutaneous gastrostomy with 1-fastener gastropexy: results of 316 consecutive procedures. *Radiology* 1997; 203:496-500.
13. Bell SD, Carmody EA, Yeung EY, et al. Percutaneous gastrostomy and gastrojejunostomy: additional experience in 519 procedures. *Radiology* 1995; 194:817-20.