

Case Series

Classic Virilizing Congenital Adrenal Hyperplasia Presenting Late: Case Series from Pakistan

Aysha Habib Khan,¹ Muniba Aban,² Rameez-ul-Hassan,³ Naeem-ul-Haq,⁴ Jamal Raza,⁵ Abdul Jabbar,⁶ Tariq Moatter⁷
Departments of Pathology,^{1,2,3,7} Departments of Medicine,^{4,6} Aga Khan University, National Institute of Child Health,⁵ Karachi Pakistan.

Abstract

Deficiency of 21 hydroxylase enzyme deficiency (21OH) activity accounts for 90% cases of congenital adrenal hyperplasia (CAH). This results in deficient cortisol, increased ACTH, adrenal hyperplasia and increased adrenal androgen secretion. There is marked virilization in genetic females which is the hallmark of this disorder. Genetic heterogeneity in 21 OHD is well recognized, and both severe and mild forms occur. We present three cases of adult females with the disease from a larger study to establish genotype, phenotype correlation of Pakistani patients with congenital adrenal hyperplasia (CAH) and to highlight issues such as diagnostic delay, inappropriate gender assignment at birth, and high degree of consanguinity among parents, psychosexual outcome of 21 OHD females and the need to develop expertise for early case detection. The analysis was done using Amplification Refractory Mutation System (ARMS) PCR. These cases show that CAH frequently remains undiagnosed during the newborn period in our population due to lack of awareness in the society and lack of proper diagnosis by the primary physician. There is a need to develop expertise for early case detection.

Introduction

Congenital adrenal hyperplasia (CAH) is an inborn error of metabolism in steroid hormone synthesis in the adrenal cortex. It is also the most common cause of ambiguous genitalia in newborn. In 90-95% of the cases, it occurs due to deficiency of Steroid 21-hydroxylase enzyme (21OH). This deficiency results in decreased synthesis of cortisol and aldosterone and overproduction of adrenal androgens.¹

Depending upon the degree of enzyme deficiency the synthesis of aldosterone and androgens is affected in different ways thus producing a wide range of presentations. In its severe form the newborn males and females present with salt wasting crises (SW-CAH) or females present with features of prenatal virilization (SV-CAH), often giving uncertainty in sex assignment and requiring cumbersome genital surgery. Mild forms, also known as late onset, non-classical (NC-CAH) can present with menstrual disturbances, infertility, hirsutism in adult females; infertility and acne in adult males.^{1,2}

Clinical variation is due to different mutations in the gene, CYP21 encoding the enzyme 21 OH. Specific mutations produce a given degree of enzymatic

compromise and give rise to various clinical forms of 21OH deficiency. Patients deficient in 21OH activity are divided according to their predicted enzyme activity in relation to the genotype found into; null, A, B and C mutations. In Null group, there is complete enzyme inactivation and patients manifest with severe salt wasting. Mutations in type A produces low but measurable enzyme activity and patients can present with neonatal virilization both with and without SW. Type B mutations are less severe and are associated with neonatal virilization without salt wasting. Group C mutations are associated with late onset disease. Therefore, genotyping is used to predict the clinical outcome in patients with 21-OHD and is a useful way to grade the severity of the disease and predict the therapeutic interventions with cortisol and aldosterone.^{2,3} Prenatal diagnosis can be made so that affected females are treated in utero, to reduce the virilizing genital malformation while the treatment of unaffected can be avoided.^{4,5}

Previously we reported paediatric cases of congenital adrenal hyperplasia due to 21OH deficiency from our hospital. Some of the key features identified included diagnostic delay, inappropriate gender assignment at birth, increased number of infant deaths, and high rate of consanguinity.^{6,7} We present three cases of adult females with the disease from a larger study to establish genotype: phenotype correlation of congenital adrenal hyperplasia (CAH) patients to highlight issues and emphasize the role of genotyping for evaluation of such cases.

Case-1:

An unmarried female presented to us at 47 years of age with ambiguous genitalia since birth. However, no medical consultation was sought and she was raised as a female. She belonged to a well to-do Punjabi family and a product of consanguineous marriage. At puberty, she developed hoarseness of voice and never developed menarche until the age of 47 when she had bleeding per vaginum and was taken for medical consultation and investigated for congenital adrenal hyperplasia (CAH). Clinical examination revealed pigmentation of the skin and hirsutism, male distribution of body hair and breast were in prader score Bo. Examination of genitalia showed clitoral enlargement, ventral binding, scrotalization of the skin, presence of urogenital sinus, fusion of the labioscrotal folds, clitoral index was above 3.5 cm. Investigations performed revealed high 17 OH Progesterone (60.8 ng/ml; reference range: 0.22 to 4.69 ng/ml) and testosterone (741 ng/dl; reference range: 6 to 82 ng/dl). Karyotyping was XX. She never had a salt-wasting crisis and therefore was diagnosed as simple virilizing congenital adrenal hyperplasia.

Case-2:

The other married Pathan woman from Peshawar residing in Karachi presented at the age of 24 years. Her symptoms started at the age of 16 years when she developed hoarseness of voice and hirsutism. Her menarche was delayed. Initially she had menstrual irregularities with scanty flow but later the cycles became regular. She was married at 17 years of age. She remained infertile and her husband had a second marriage after some years, as he wanted to have children. His second wife was pregnant and this lady came to the clinic for treatment. On examination, she had male distribution of body hair with temporal recession. There was no breast development (prader stage Bo). Her genitalia were unambiguously female with posterior labial fusion and with a clitoral index of 3.5 cm. Her 17 OH Progesterone levels were raised at 185 ng/ml. Ultrasound showed normal internal female genitalia. She was started with 7.5 mg of prednisolone daily Follow-up after 3 months showed breast development (prader stage B2). A decrease in the hair growth was also observed. She also started having normal menstrual cycles and became pregnant.

Case-3:

An unmarried female of Indian origin presented at 20 years of age with primary amenorrhea and hirsutism. Her parents were first cousins. On examination her breasts were not developed (Bo), there was clitoromegaly (CI 92 mm) and posterior labial fusion. She was diagnosed to have Non classical form of congenital adrenal hyperplasia (NC-CAH) with a 17-hydroxyprogesterone (17 OHP) level of 720 ng/ml. She started menstruating after initiation of therapy. She took daltacortil for 8 years and then left the treatment on her own and was lost to follow-up. At 30 years of age she once again presented with extreme stress due to her disease. She was advised to start the treatment and counseled about the disease prospects.

Molecular Analysis:

Genomic DNA was extracted from leukocytes using genomic DNA purification kit (Promega, USA). Purified DNA was screened for mutations in CYP21 gene using allele specific Polymerase Chain Reaction. In the initial round of amplification, two overlapping fragments; labeled A&B of CYP21 gene were amplified using high fidelity PCR master mix kit according to manufacturer' instructions (Roche Diagnostic, Mannheim Germany). Briefly, 250ng of genomic DNA in 50 µl volume along with 30 ng of specific primers P1 and P48 for fragment A, primers P4 and P55 were used for fragment B in PCR mixture containing high fidelity master was recycled at 94°C for 30 seconds, 56°C for 30 seconds and 72°C for 1

minute for 35 cycles with 5 second increments in each cycle. Amplified fragments were separated on 1% agarose gel and submitted to second round of PCR to detect mutation Pro311leu at nucleotide position 92 and interon2 splice at nucleotide position 659 in fragment A. Ile173Asn, Arg357Trp, Gln319stop, Leu308insT, Val282Leu, Val238Glu, nucleotide position 1004, 2113, 1999, 1768, 1688, and 1388 in fragment B respectively. Amplified products were separated on 3% agarose gel stained with ethidium bromide and visualized under Ultra-Violet light for photography.

Results

Figure-1 shows results of the molecular analysis. Mutations Ile173Asn causing a substitution of A for T at nucleotide position 1004 in case 1 and 3. These

mutation and additional rare mutations.

In our patients, the results of genotyping showed Simple virilization form of CAH (SV-CAH) without SW. However, symptoms of androgen excess were not noted at birth or in early childhood and, due to late presentation, cases 2 and 3 were labeled as Non-classical congenital adrenal hyperplasia (NC-CAH). Non-classical congenital adrenal hyperplasia of 21 OHD presents in later childhood, at puberty or in adult life with signs of androgen excess and hence its name as late onset or acquired form of congenital adrenal hyperplasia (CAH). In case 1, despite having virilizing features; medical consultation was not sought.

Early diagnosis in congenital adrenal hyperplasia (CAH) is essential to avoid adrenal crises and to ensure

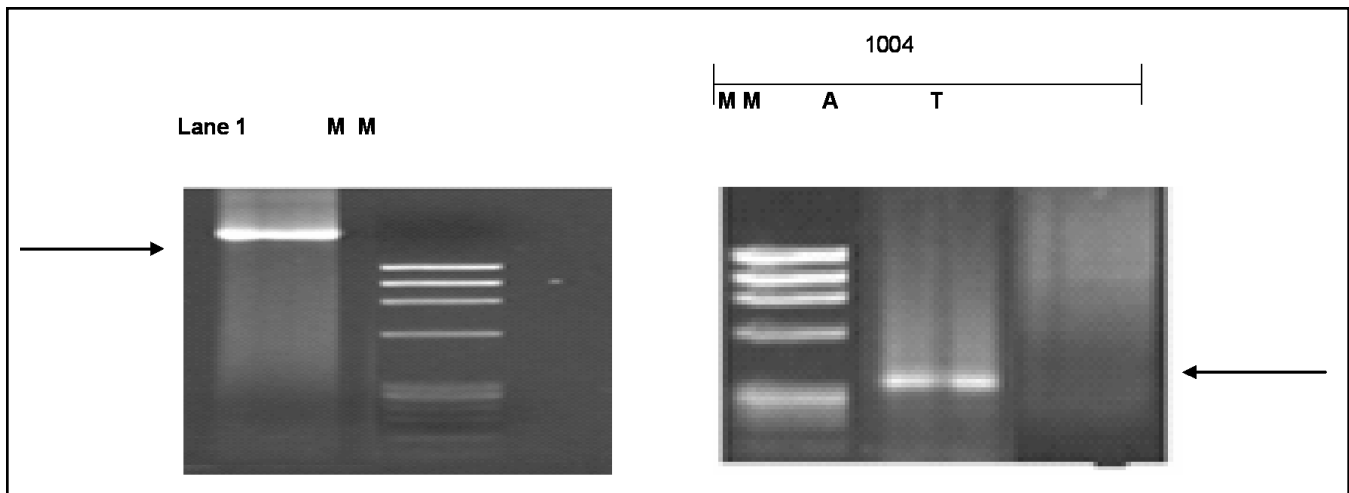


Figure1: Detection of Ile173Asn mutation at nucleotide position 1004 by ARMS PCR. Figure shows detection of Ile173Asn Mutation for case 1 and 2 at nucleotide position 1004 by ARMS PCR lane 1 shows amplification of fragment B at position 1004 case 2. MM = Molecular marker FX174 (72-1353 bp).

mutations are associated with Simple virilization form of congenital adrenal hyperplasia (SV-CAH). PCR failure was noted in case 2, which may be due to new mutations. For such samples DNA sequencing is required for verification.

Discussion

Two patients had Ile173Asn mutation which causes protein change from ATC>AAC at nucleotide position 1004 in Exon 4. Ile173Asn mutation is classified as type B since it is considered slightly less severe and is usually associated with neonatal virilization without salt wasting and was also identified in salt wasting congenital adrenal hyperplasia (SW-CAH) patients. The mutation reduced enzyme activity to 10% in vitro. Case 2 may have new mutation and in this case direct sequencing is valuable as a complement to mutation screening for the characterization of the novel

normal physical, psychosocial development and fertility.^{8,9} Frequent diagnostic delay has been reported in literature, however after 1970, the diagnostic rate improved in many countries due to better diagnostic tests and improvement in clinical awareness of this disorder. Later in some countries screening for congenital adrenal hyperplasia was also introduced. Our data shows that congenital adrenal hyperplasia frequently remains undiagnosed during the newborn period in our population primarily due to lack of awareness, non availability of proper diagnosis, false social beliefs, and religious dogmas. In Pakistan, there is ethnic diversity; the prevalence of congenital adrenal hyperplasia may vary in different ethnic groups. Our three cases are from three different ethnic backgrounds. This shows that congenital adrenal hyperplasia (CAH) cases are prevalent in people from different ethnic backgrounds in Pakistan.

Reproductive abnormalities such as increased risk of developing polycystic ovarian syndrome; developmental anomalies like labial fusion may leave the vaginal introitus inadequate for successful intercourse, are seen in our cases and have been reported in literature. An enlarged clitoris also, often requires surgical correction. Surgical correction may be necessary depending on the degree of virilization. Issues of female fertility and optimal management for pregnant females are equally important.⁹⁻¹¹ Many women in our set-up do not routinely see a gynecologist at any stage as an adult, despite having undergone reconstructive surgery of clitoris and vagina as a child. It is important to maintain glucocorticoids replacement at pre pregnancy doses, and to monitor testosterone and 17 α -hydroxyprogesterone. Early exposure of brain to hyperandrogenism is responsible for many of the psychological outcomes noted. Social and emotional well being is also lower than the general population.

Conclusion

Congenital adrenal hyperplasia (CAH) frequently remains undiagnosed during the newborn period in our population due to lack of awareness in the society and lack of proper diagnosis by the primary physician. There is a need to develop expertise for early case detection. Being an autosomal recessive disease, children are born to parents unaware of the risk and with no family history. To minimize the degree of virilization in females, prenatal diagnosis should be available to high risk families so that the treatment can be started in genetically affected females during the

antenatal period.

Acknowledgement

This work was funded by a Research Grant from University Research Council of Aga Khan University. The authors would like to acknowledge the support provided by Dr Anwar Siddiqui, Associate Dean Research at Aga Khan University throughout the study.

References

1. New MI. Extensive clinical experience: non-classical 21-hydroxylase deficiency. *J Clin Endocrinol Metab* 2006; 91: 4205-14.
2. Wedell A, Thillen A, Stengler B, Ritzen M, Luthman H. Mutational Spectrum of the Steroid 21-Hydroxylase Gene in Sweden: Implications for genetic diagnosis and association with disease manifestation. *J Clin Endocrinol Metab* 1994; 78: 1145-52.
3. Azziz R, Dewailly D, Owerbach D. Nonclassic adrenal hyperplasia: current concepts. *J Clin Endocrinol Metab* 1994; 78: 810-5.
4. Lajic S, Nordenstrom A, Ritzen EM, Wedell A. Prenatal treatment of congenital adrenal hyperplasia. *Eur J Endocrinol* 2004; 151 (Suppl 3): U63-9.
5. Nimkarn S, New MI. Prenatal Diagnosis and Treatment of Congenital Adrenal Hyperplasia. *Horm Res* 2006; 67: 53-60.
6. Khan AH, Nasir MI and Moatter T. Characterization of Pathogenic Mutations in 21-hydroxylase Gene of Pakistani Patients with Congenital Adrenal Hyperplasia -A Preliminary Report. *J Pak Med Assoc* 2002; 52: 287-91.
7. Bhingji R, Khan AH, Lashari I, Sabir S, Nazir Z, Billoo G. Profile of Children with Congenital Adrenal Hyperplasia-A Hospital Study. *J Pak Med Assoc* 2004; 54: 509-12.
8. Ogilvie CM, Crouch NS, Rumsby G et al. Congenital adrenal hyperplasia in adults: a review of medical, surgical and psychological issues. *Clin Endocrinol* 2006; 64: 2-11.
9. Claahsen-van der Grinten HL, Stikkelbroeck NM, Sweep CG, Hermus AR, Otten BJ. Fertility in patients with congenital adrenal hyperplasia. *J Pediatr Endocrinol Metab* 2006; 19: 677-85.
10. Moran C, Azziz R, Weintrob N, Witchel SF et al. Reproductive outcome of women with 21-hydroxylase-deficient non-classic adrenal hyperplasia. *J Clin Endocrinol Metab* 2006; 91: 3451-6.
11. Hoepffner W, Rothke K, Bennek J. Feminizing reconstructive surgery for ambiguous genitalia: the Leipzig experience. *J Urol* 2006; 175: 981-4.