

Follicular Thyroid Carcinoma Presenting as Solitary Skull Metastasis: Report of Two Cases

Muhammad Shahzad Shamim, Faraz Khursheed, Muhammad Ehsan Bari, Khalid Naseem Chisti, Syed Ather Enam
Department of Neurosurgery, Aga Khan University Hospital, Karachi, Pakistan.

Abstract

We report two otherwise healthy patients with no prior history of thyroid cancer, who presented to us with a solitary scalp lump. Neuroimaging of both patients showed osteolytic lesions involving the cranium which were subjected to complete excision biopsy and cranioplasty. Histopathological examination revealed metastases from well differentiated follicular thyroid carcinoma (FTC). Subsequent workup confirmed occult primary carcinoma of the thyroid gland in both patients.

Introduction

Follicular thyroid carcinomas (FTC) are subtypes of thyroid cancers which show high propensity for blood borne metastases. These are slow growing tumours and are associated with a favourable prognosis except when they present with metastasis, which is usually to lungs or

bones.^{1,2} Metastatic tumours to the skull are most often from lung, breast and prostate malignancies and rarely from thyroid cancers. In a series of 473 patients with thyroid cancers, Nagamine et al reported skull metastases in only 2.5 to 5.8% of cases.³ In almost all the reported cases of follicular thyroid carcinoma metastasizing to the skull, metastases occurred long after the diagnosis and institution of treatment for primary cancer, and there have been only a handful of cases in the literature in which solitary skull metastasis was the presenting feature of an occult FTC.⁴⁻⁶ We report 2 such patients treated at our institution within the last 2 years.

Case 1

A 62 years old female presented to the neurosurgical outpatient clinic with complaints of enlarging swelling of the vertex with mild diffuse headache since one year. About

two years ago, the patient was diagnosed of having hyperthyroidism secondary to toxic goiter with no clinical or ultrasonographic evidence of nodularity. The Technitium-99m scintigraphy done at that time showed diffuse radiouptake by the gland. She was prescribed anti-thyroid medication, Carbimazole, on which her thyroid status remained well controlled. On presentation, she was clinically euthyroid with mild diffusely enlarged thyroid gland. Examination revealed a firm, well circumscribed lump at the vertex involving bilateral frontal and parietal bones and intact overlying skin. Neurological examination was unremarkable. Routine blood tests and thyroid function tests were also within normal limits. Skull X-ray and contrast enhanced computerized tomography (CT) demonstrated a 4 x 4 x 3 cm lytic lesion of the vertex destroying the outer and inner table of the bilateral frontal and parietal bones, extending extradurally under the scalp.

Patient was planned for excision biopsy of the lesion. Intra-operatively, we found a firm, vascular lesion involving the skull and the underlying dura. Tumour was also invading the superior sagittal sinus. The entire tumour along with the involved dura was removed, and the portion overlying the sinus was gently peeled away. Artificial dura was used to cover the dural defect and acrylic was used for the bony defect. Patient made an uneventful recovery. Histopathology revealed metastasis from well differentiated follicular carcinoma of the thyroid. H&E stained sections showed cuboidal thyroid follicular tumour cells having pleomorphic nuclei, arranged in closely packed follicles with evidence of invasion into blood vessels and dura mater. Cells showed positive staining for thyroglobulin and epithelial membrane antigen. Later workup included thyroid ultrasonography which revealed a 1.3 x 1.1 cm nodule in left lobe that was cold on Technitium-99m scintigraphy with no uptake elsewhere in the body. The patient underwent a total thyroidectomy 30 days later and was started on thyroxine replacement. A postoperative MRI was done after three months that showed no residual or recurrent tumour and she is symptom free at 22 months follow up.

Case 2

A 65 years old female from rural part of Northern Pakistan, with no known co-morbid, presented to our outpatient clinic with a right frontal lump which she incidentally noticed five years back. The lump had been painless and was slowly but gradually increasing in size, thus the delay in presentation. She was otherwise healthy with no significant past medical or surgical history. On presentation, she was clinically euthyroid with normal general physical, systemic and neurological examination.

Local examination revealed a 6 x 7 x 2 cm right fronto-parietal soft, fluctuant lump with well-defined margins. Routine blood tests and thyroid function tests were normal. Skull X-ray showed a large right fronto-parietal lytic lesion with some focal calcifications in the soft component of the lesion. Contrast enhanced computed tomography (CT) demonstrated a 6.0 x 2.5 cm right frontal bone mass completely destroying the outer table and involving the inner table of the bone, with a subgaleal soft tissue

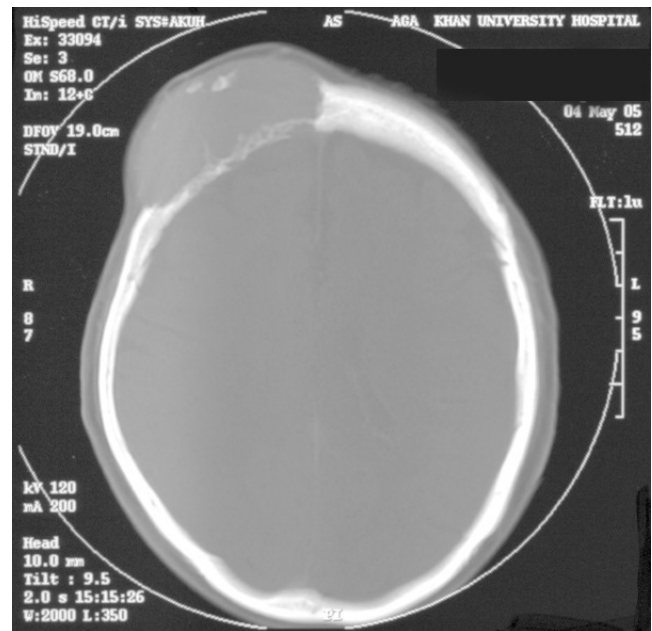


Fig 1: Preoperative CT scan, bone window showing an osteolytic lesion in the right frontoparietal region with overlying enhancing soft tissue component.

component showing intense contrast uptake. (Fig 1)

Patient was planned for excision biopsy and a right frontal craniotomy was performed. Intra-operatively, we found a firm, vascular tumour which was totally resected along with surrounding bone and the skull was subsequently reconstructed with acrylic. (Fig 2) H&E stained sections of the lesion demonstrated a neoplastic lesion comprising of follicles of varying sizes, filled with colloid and surrounded by cuboidal cells with pleomorphic nuclei and low grade mitotic activity. The cells showed positive immunohistochemical staining for thyroglobulin, cytokeratin 7 and cytokeratin CAM. The patient recovered well after surgery and post-operative CT showed no residual tumour. Her subsequent work up revealed an occult primary in the right lobe of thyroid for which she was advised further investigations which she refused and has since been lost to follow up.

Discussion

Thyroid cancers account for about 0.5 % of all

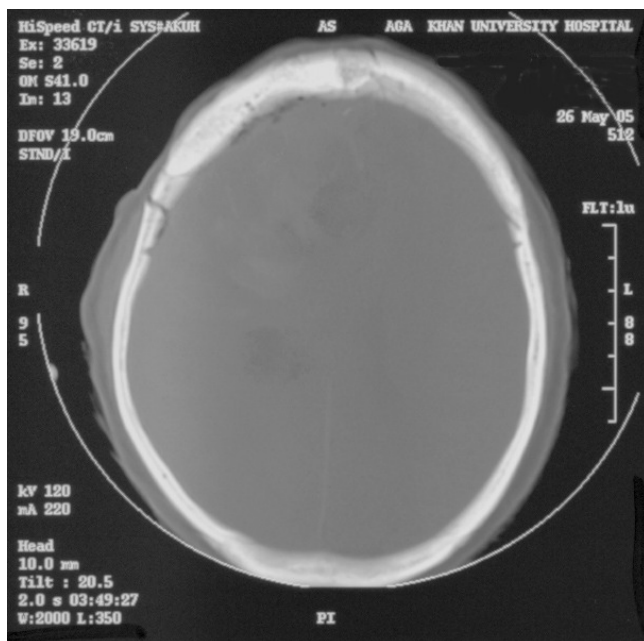


Fig 2: Post-cranioplasty CT scan, bone window showing no evidence of residual tumor.

cancers in men and 1.5 % of all cancers in women.⁷ In Pakistan, thyroid cancer is responsible for about 1.2 % cases of all malignant tumours, with patients usually presenting with neck mass.^{8,9} Follicular thyroid carcinomas (FTC) are subtypes of thyroid cancers which are slow growing tumours and are associated with a favourable prognosis except when they present with distant metastasis.¹ Lung and bone are the two most favoured sites of metastases.² Bone metastases from FTC tend to be multiple and more often to the ribs, vertebrae and sternum.¹⁰ Skull is a rare site for metastases which when occur, are most commonly located in the occipital region presenting as a soft, painless lump.^{3,6} These lesions are osteolytic on skull X-ray and CT scan and highly vascular on angiographic assessment.^{3,4} The largest case series of skull metastases from all types of thyroid cancers consists of 12 cases reported by Negamine et al.³ In this series, mean time from the diagnosis of thyroid tumour until discovery of skull metastasis was 23.3 years. Prognosis in case of metastasis is generally poor and the 10 year survival with bone metastases from differentiated thyroid cancers is reported to be 27%.² However, the reported mean survival in patients who present with skull metastases in the case series by Negamine et al is just 4.5

years suggesting that these subset of patients tend to do even worse.³

Both our patients were female in their sixties and presented with a solitary skull lump that turned out to be metastatic follicular thyroid carcinoma on excision biopsy and only then were they worked up to find the occult primary lesion. Although the first patient was a known case of toxic goiter and was being treated medically, the other had no symptoms and signs of thyroid disease. Neither of the two patients had palpable thyroid nodules or cervical lymph nodes as might be expected in patients with advanced follicular thyroid cancers. The sole complaint of a disfiguring scalp lump makes these two cases very unusual. Interestingly, the first patient also had mild to moderate pain around the swelling that could be due to meningeal invasion by the tumor, although she did not have meningism, signifying lack of inflammation around the tumor that was also confirmed later on histopathology. The first case also requires special mentioning as there is no report to date, of a FTC presenting as a solitary metastasis to the skull which is locally advanced showing frank invasion of the dura and underlying superior sagittal sinus.

References

1. Thyroid carcinoma task force. AACE/AAES medical/surgical guidelines for clinical practice: Management of Thyroid Carcinoma. American Association of Clinical Endocrinologists. American College of Endocrinology. *Endocr Pract* 2001; 7:202-20
2. Schlumberger M, Tubiana M, De Vathaire F, Hill C, Gardet P, Travagli JP, et al. Long term results of treatment of 283 patients with lung and bone metastases from differentiated thyroid carcinoma. *J Clin Endocrinol Metab* 1986; 63: 960-7
3. Nagamine Y, Suzuki J, Katakura R, Yoshimoto T, Matoba N, Takaya K. Skull metastasis of thyroid carcinoma. Study of 12 cases. *J Neurosurg* 1985; 63: 526-31.
4. Akdemir I, Erol FS, Akpolat N, Ozveren MF, Akfirat M, Yahsi S. Skull metastasis from thyroid follicular carcinoma with difficult diagnosis of the primary lesion. *Neurol Med Chir (Tokyo)* 2005; 45: 205-8.
5. Ozdemir N, Senoglu M, Acar UD, Canda MS. Skull metastasis of follicular thyroid carcinoma. *Acta Neurochir (Wien)* 2004; 146: 1155-8.
6. Inci S, Akbay A, Bertan V, Gedikoglu G, Onol B. Solitary skull metastasis from occult thyroid carcinoma. *J Neurosurg Sci* 1994; 38: 63-6.
7. Sherman SI. Thyroid carcinoma. *Lancet* 2003; 361: 501-1.
8. Zuberi L M, Yawar A, Islam N, Jabbar A. Clinical presentation of thyroid cancer patients in Pakistan — AKUH experience. *J Pak Med Assoc* 2004; 54: 526-8.
9. Shah SH, Muzaffar S, Soomro IN, Hasan SH. Morphological pattern and frequency of thyroid tumors. *J Pak Med Assoc* 1999; 49: 131-3.
10. Zettinig G, Fueger BJ, Passler C, Kaserer K, Pirich C, Dudevak R, et al. Long term follow-up of patients with bone metastases from differentiated thyroid carcinoma—surgery or conventional therapy? *Clin Endocrinol (Oxf)* 2002; 56: 377-82.