

# Torsion of Fallopian Tube, Fimbrial Cyst

Imrana Masroor, Nadir Khan,

Radiology Department, Aga Khan University Hospital, Karachi.

## Abstract

A case of fallopian tube fimbrial cyst torsion with haemorrhage is presented, occurring in a 37 year old female who had tubal ligation 6 years back. She presented in emergency with acute abdomen. Initial assessment of ovarian cyst haemorrhage or torsion was made. Ultrasound showed cystic structures in left adnexa and complex cyst in right adnexa with suspicion of torsion. Laparoscopy was performed and bilateral fimbrial cysts in fallopian tubes were identified with torsion on right side, and a left ovarian haemorrhagic cyst, which was subsequently confirmed on histopathology. Although fallopian tube torsion of fimbrial cyst is rare, it should be considered in patients who had history of bilateral tubal ligation. Again it should also be considered in the differential diagnosis of acute abdomen in females.

## Introduction

Isolated twisting of fallopian tubes is an uncommon event<sup>1</sup>. The frequency is 1/1,500,000 women<sup>2</sup>. Right fallopian tube is most commonly affected. The condition is frequently misdiagnosed with acute appendicitis or ovarian torsion. The torsion of fallopian tube and para-ovarian cyst is usually seen in reproductive age group. The age range is from 21-40 years<sup>3</sup>. It is also rare in pregnancy, with only one case in 120,000 pregnancies being reported over a period of 10 years<sup>4</sup>. The exact cause of fallopian tube torsion is unknown; however several etiologies have been postulated.

The signs and symptoms and physical findings mimic common diseases as mentioned above, therefore the diagnosis is never established before an invasive procedure like laparoscopy. Accurate and immediate diagnosis can lead to early intervention, avoid complications and may even save the organ.

## Case Report

A 37 year old female presented in emergency department complaining of diffuse abdominal pain for 3 days, with maximum intensity in right iliac fossa. Pain was sudden in onset, initially mild to moderate which progressively became severe. It was associated with nausea, but no vomiting, bowel or urinary symptoms. Patient did not complain of any history of vaginal bleeding.

Patient's obstetric and gynaecological history included four live births and one miscarriage. Last delivery resulted in a lower segment caesarian section six years back during which patient had bilateral tubal ligation. Patient also suffered from menorrhagia and anaemia and was treated with blood transfusions and intravenous iron injections. Ultrasound examination for an episode of pelvic inflammatory disease 2 years back showed tubular structure in right adnexa about 5.1 x 2.3 cm consistent with hydrosalpinx. It was treated conservatively. Repeat ultrasound six months back was normal.

During this admission, vitals were within normal

limits with pulse 88 beats per minute, blood pressure 110/70 mmHg and temperature 36.8°C. Tenderness on abdominal examination; however no rebound tenderness and gut sounds were audible. Uterus felt bulky but was difficult to assess due to abdominal tenderness, however bilateral adnexal fullness and tenderness was noted. Vaginal examination showed posterior cervical lip which was hypertrophied and spotting was present. Laboratory investigations were unremarkable.

Abdominal and transvaginal ultrasound was carried out which showed bulky anteverted uterus measuring 8.9 x 4.5 x 6.4 cms with endometrial thickness of 1 cm. A small hypo echoic lesion measuring 1.1 x 1.3 cms was seen in myometrium of fundus representing an intramural fibroid. A multicystic structure, measuring 3.5 x 2.7 cms, seen in left adnexa was not separately visualized from left ovary. A complex cyst, measuring 3.9 x 2.9 cms, was identified in right adnexa (Figure 1)

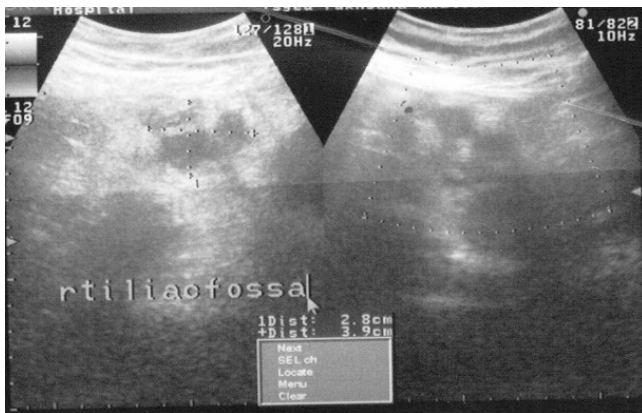


Figure 1: Right ovary (right image). Complex cyst, (3.9 x 2.9 cms) in right adnexa continuous with right ovary (left image).

continuous with right ovary; suspicion was raised for torsion of ovarian cyst as it was slightly higher up; however other differential diagnosis in the report were appendicitis, embryological remnant or a paraovarian cyst. Minimal streak of fluid was seen around this structure. Right ovary measured 2.6 x 1.9 cms (Figure 2). A diagnosis of haemorrhagic ovarian cyst or torsion was made and laparoscopy was performed. Laparoscopic findings were consistent with a multiloculated fimbrial cyst approximately 4 x 4 cms and a 1 x 1 cm haemorrhagic cyst in left ovary. Approximately, a 3 x 4 cms haemorrhagic cyst found at fimbrial end and 2 x 2 cms haemorrhagic cyst in right ovary. The right sided fimbrial cyst was twisted 3-4 times. Laparoscopic bilateral fimbrial cyst excision and right haemorrhagic ovarian cystectomy was done. Patient remained stable postoperatively and was discharged same day.

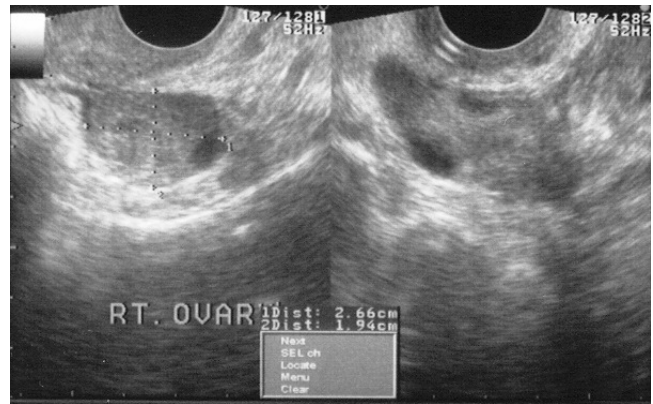


Figure 2: Right ovary measuring approximately 2.6 x 1.9 cms (left image). Hemorrhagic cysts seen in right ovary (visualized in both images).

Histopathology confirmed a right sided fimbrial cyst with features of haemato-salpinx, and a left sided haemorrhagic ovarian cyst. Left fimbrial cyst features were suggestive of salpingitis isthmica nodosa. No malignant change was reported. Patient was doing well at the follow up visit.

## Discussion

Isolated torsion of fallopian tube or fimbrial cyst torsion is rare, therefore the diagnosis is often difficult and delayed because of its rarity and its presentation as an acute abdomen<sup>1</sup>. Various theories have been postulated to explain the cause of Fallopian tube torsion. A survey of 201 cases of fallopian tube torsion by Regad<sup>5</sup> found a normal appearance in only 24%. Causes of fallopian tube torsion include anatomic abnormalities including long mesosalpinx, tubal abnormalities, hydrosalpinx and hydatids of morgagni. Physiologic abnormalities include peristalsis or hyper mobility of the tube and tubal spasm from drugs. Haemodynamic abnormalities include venous congestion in the mesosalpinx, trauma.<sup>6</sup> Previous surgery as tubal ligation, specially the use of Pomeroy technique, can predispose to fallopian tube torsion.<sup>7</sup>

The torsion of accessory fallopian tubes and isolated torsion of the fimbriae can also occur in children and adolescents.<sup>8</sup> The differential diagnosis of Fallopian tube torsion includes acute appendicitis, ectopic pregnancy, pelvic inflammatory disease, twisted ovarian cyst and degenerative leiomyoma.<sup>9</sup> Despite published case reports, there is often delay in making a preoperative diagnosis, as isolated tubal torsion is a rare event, even in adult women.<sup>10</sup> The interval between tubal sterilization and occurrence of tubal cyst is about 10 years, ranging from 4 to 21 years. The Hydatids of Morgagni are another infrequent cause of adnexal torsion.<sup>11</sup> The most common

presenting symptom is pain which begins in the affected lower abdomen or pelvis but may radiate to the flank or thigh. The onset of pain is sudden and cramp like and there may be complaints of scant uterine bleeding. The body temperature, white blood cell count and erythrocyte sedimentation rate may be normal or slightly elevated. Many reports indicate that torsion of the Fallopian tube is more common on the right side than on the left.<sup>12</sup> Pelvic examination may reveal tender, tense adnexa associated with cervical tenderness. For diagnostic purposes ultrasound can help in detecting adnexa mass with torsion or haemorrhage, but the diagnosis is never established before operation.

Ultrasound may show an elongated, convoluted cystic mass, tapering as it nears the uterine cornu and demonstrates the ipsilateral ovary separate from the mass. Doppler evaluation can further help by showing findings of high impedance or absence of flow in a tubular structure.<sup>13</sup>

The management of this condition consists of early surgery. Laparotomy is often performed but laparoscopic surgery is a better option for twisted fallopian tube. In this case laparoscopy was suitable as patient was haemodynamically stable and the size of cysts was such that could be managed laparoscopically<sup>9</sup>. Although fallopian tube torsion of fimbrial cyst is rare, it should be considered in patients who have history of bilateral tubal ligation and should be included in differential diagnosis of female patients

presenting with acute abdomen.

## References

1. Adekanmi OA, Barrington JW, Edwaeds G, Farrell D. Isolated torsion and hemorrhagic infarction of normal fallopian tube in an eleven year old girl. *BJOG* 2000; 107: 1047-8.
2. Hansen OH. Isolated torsion of the Fallopian tube. *Acta Obstet Gynecol Scand* 1970; 49:3-6.
3. Phupong V, Intharasakda P. Twisted fallopian tube in pregnancy: A case report. *BMC Pregnancy and childbirth* 2001; 1:5.
4. Yalcin OT, Hassa H, Zeytinoglu S, Isiksoy S. Isolated torsion of fallopian tube during pregnancy: Report of two cases. *Eur J Obstet Gynecol Reprod Biol* 1997; 74:179-82.
5. Regad J. Etude anatomo-pathologique de la torsion des trompettes uterines. *Gynaecol Obstet* 1933; 27:519-3.
6. Shukula R. Isolated torsion of the hydrosalpinx: a rare presentation. *Br J Radiol* 2004; 77:784-6.
7. Bishop EA, Nelms WF. A simple method of tubal sterilization. *NY State J Med* 1930; 30:214.
8. Lau HY, Huang LW, Chan CC, Lin CL, Chen CP. Isolated torsion of the fallopian tube in a 14-year-old adolescent. *Taiwan J Obstet Gynecol* 2006; 45:363-5
9. Krissi H, Shalev J, Bar-Hava I, Langer R, Herman A, Kaplan B. Fallopian tube torsion: laparoscopic evaluation and treatment of a rare gynecological entity. *J Am Board Fam Pract* 2001; 14:274-7.
10. Terada Y, Murakami T, Nakamura S, Sato Y, Niikura H, Ito K, Yaegashi N, Okamura K. Isolated torsion of the distal part of the fallopian tube in a premenarcheal 12 year old girl: a case report. *Tohoku J Exp Med* 2004; 202:239-43
11. Pansky M, Smorgick N, Lotan G, Herman A, Schneider D, Halperin R. Adnexal torsion involving hydatids of Morgagni: a rare cause of acute abdominal pain in adolescents. *Obstet Gynecol* 2006; 108:100-2.
12. Milki A, Jacobson DH. Isolated torsion of the fallopian tube. A case report. *J Reprod Med* 1998; 43:836-8.
13. Elchalal U, Caspi B, Schachter M, Borenstein R. Isolated tubal torsion: clinical and ultrasonographic correlation. *J Ultrasound Med* 1993; 12:115-7.