

Clinical and radiological features of intracerebral haemorrhage in hypertensive patients

Azra Zafar, Farrukh Shohab Khan
Department of Neurology, Liaquat National Hospital, Karachi.

Abstract

Objective: To describe clinical and radiological features of intracerebral haemorrhage in hypertensive patients.

Methods: This is a descriptive case series, carried out prospectively over a period of 6 months at, department of neurology, Liaquat National Hospital, Karachi. Hypertensive patients > 25 years of age, presenting with features of stroke and verified by either CT scan or MRI brain as having intracerebral haemorrhage, were included. Clinical and radiological features were identified. A total of 100 patients were included in the study. Data was analyzed by SPSS version 10.0.

Results: There were 62% males and 38% females. Mean age was 56 ± 12 years. Diabetes mellitus was present in 30% and ischaemic heart disease in 26% patients. Of all, 28% were smokers. Hemiparesis or hemiplegia (78%) was the commonest presenting feature followed by speech dysfunction (60%). Headache and vomiting were present in 20% and seizures in 9% cases. Basal ganglia (55%) was the commonest site of bleed followed by thalamus (26%), cerebral hemispheres (11%), brain stem (8%) and cerebellum (7%).

Conclusion: Hypertensive intracerebral haemorrhage was more common in males as compared to females in our study. Hemiparesis and speech disturbances were frequent presenting features. The commonest site of bleeding was basal ganglia followed by thalamus and cerebral hemispheres (JPMA 58:356;2008).

Introduction

Intracerebral haemorrhage accounts for 10-23% of strokes,¹ with hypertension being the single most important risk factor in middle aged and elderly persons.^{2,3} Intracerebral haemorrhage is associated with higher mortality rate with only 38% of affected persons surviving in the first year.³ Reported frequency of intracerebral haemorrhage in our country is even higher, ranging from 24 to 46%.⁴ Depending upon the underlying cause of bleeding, intracerebral haemorrhage is classified as either primary or secondary. Primary intracerebral haemorrhage accounts for 78 to 88% of cases, originating from the spontaneous rupture of small vessels damaged by chronic hypertension or amyloid angiopathy.⁵ Primary intracerebral haemorrhage occurs more frequently in men than women,⁶ particularly those older than 55 years of age,⁷ and in certain populations as blacks and Japanese.⁸ Secondary intracerebral haemorrhage is encountered in a minority of patients in conditions with vascular abnormalities (such as arteriovenous malformation, aneurysm), tumours, recreational drug abuse or impaired coagulation.⁹ Cerebral bleeding may be attributed to acute hypertension or rupture of arteries damaged by chronic hypertension.¹⁰ Chronic hypertension induces degeneration of the small arteries (lipohyalinosis), which may then be prone to rupture.¹¹ The increased risk of intracerebral haemorrhage is substantially greater among those who have ceased their antihypertensive medication, are relatively young or are current smokers.² Young people differ in their clinical characteristics and have a different prognosis when compared to their older counterparts.¹² Patients with large a haemorrhage exhibit a sudden onset of focal neurologic deficit.¹³ Headache¹⁴, vomiting¹⁵ and depressed conscious state^{14,15} are common with focal signs dependent on the site of haemorrhage.¹⁶ The most common site of bleeding is in the deep region of the brain involving putamen, thalamus and caudate nucleus, where it results from rupture of the vessels near the base of the brain.¹⁷ In one study, sudden headache followed by loss of consciousness, loss of speech, hemiplegia or hemiparesis were the most frequent presenting complaints. Common sites of bleed were basal ganglia, internal capsule and thalamus (75%) followed by cerebellum (9%).¹⁸

Patients and Methods

This is a descriptive case series, carried out prospectively over the period of 6 months (from October to March 2008) at the department of neurology, Liaquat National Hospital, Karachi. Spontaneous intracerebral haemorrhage was defined as a sudden onset of an acute neurological deficit with confirmation of intraparenchymal haemorrhage either by CT scan or MRI brain. Patients more than 25 years of age, with hypertension (defined as those with history of blood

pressure more than or equal to 140/90 mmHg, whether treated or not) and spontaneous intracerebral haemorrhage as defined above were included in the study. Patients with secondary causes of haemorrhage were excluded. Total of 100 patients were enrolled. Informed consent was taken, a detailed history obtained and examination was performed. Presenting clinical features which included, hemiparesis or hemiplegia, speech dysfunction, altered sensorium, headache, vomiting and seizures were noted.

Fasting lipid profile was checked in all patients. Location was sited as basal ganglia, thalamus, lobar, brain stem, cerebellum and intraventricular according to CT Scan or MRI. Associated radiological features as oedema and hydrocephalus were also described.

Data was analyzed by SPSS version 10.0. Descriptive statistics were applied to calculate frequencies and percentages of qualitative variables, like findings on CT scan or MRI as location. Mean values with standard deviation were computed for quantitative variables as age.

Results

Among 100 patients, 62 % were males and 38% were females. Age range was 28 to 90 years with mean age of 56+12 years. Hemiparesis or hemiplegia was the

Table:1 Percentages of different presenting complaints.

Presenting complaints	Percentages of patients
Hemiparesis or hemiplegia	78%
Language dysfunction	60%
Altered sensorium	35%
Headache	20%
Vomiting	20%
Seizures	9%
Hemianaesthesia	9%
Vertigo	8%
Imbalance or fall	7%

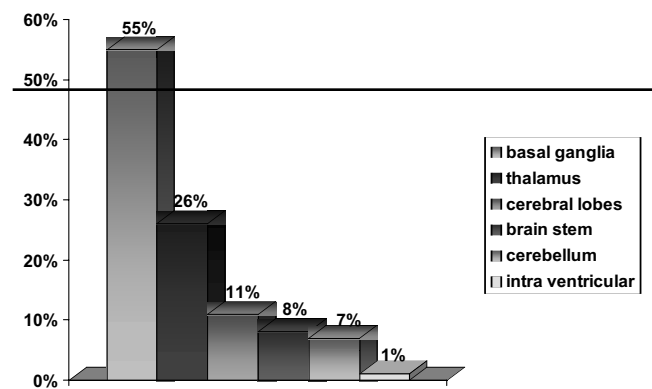


Figure. Location of intracerebral haemorrhage.

commonest presenting complaint followed by speech dysfunction. Headache and vomiting were found in 20 % patients and seizures in 9%. Less common complaints were vertigo, imbalance, and hemianaesthesia. (Table: 1)

Diabetes mellitus was present in 30%, ischaemic heart disease in 26% and 28% patients were smokers. Previous history of ischaemic infarct was present in 13 patients, however only 4 had history of intracerebral haemorrhage in the past. Basal ganglia were the commonest site of bleed followed by thalamus, cerebral lobes, brain stem and cerebellum. (Figure) Primary intraventricular haemorrhage was found in one patient only. Surrounding oedema was seen in 20% cases and hydrocephalus in 6% patients. Intraventricular seepage secondary to parenchymal haemorrhage was observed in 8% patients.

Discussion

Hypertensive haemorrhage is more common in males than females as also reported in other studies. 6, 7 Headache and vomiting are frequent non specific symptoms which occur due to increased intracranial pressure and meningismus which results from blood in the ventricles.¹⁹ In our study, headache and vomiting were present in 20% of cases, while headache followed by loss of consciousness was the commonest complaints as in the study by Arshad et. al.¹⁸ Altered level of sensorium was seen in 35% of patients. Decreased level of consciousness is more commonly seen when a large haematoma develops and intracranial pressure rises. This directly compresses or distorts the thalamic and brain stem reticular activating system.¹⁹ Reported frequency of seizures is 10 to 15%, usually associated with haemorrhage in the cerebral hemisphere.²⁰ We found seizures in 9% of our cases, with almost all occurring within 24-48 hours. It has been previously observed that most seizures occur at the onset of intracerebral haemorrhage or within the first 24 hours.²¹ The higher percentage of focal neurological symptoms as hemiparesis or hemiplegia and speech disturbances can be explained by more frequent involvement of deeper regions of brain as basal ganglia and thalamus (80%), which has been reported earlier.¹⁸ Lobar haemorrhage was found in 11% cases, parietal lobe being commonly involved (9/11) while intraventricular haemorrhage was least common, seen in only 1 patient. Apart from hypertension, smoking, low HDL cholesterol and possibly diabetes mellitus are associated with increased risk of intracerebral haemorrhage.²²

Conclusion

In the presented study, hypertensive intracerebral haemorrhage was more common in males as compared to

females. Hemiparesis or hemiplegia and speech dysfunction were the most frequent presenting complaints. Deeper regions of the brain as basal ganglia and thalamus were more involved than other areas of the brain.

References

1. Lavados PM, Sacks C, Prina L, Escobar A, Tossi C, Araya F, et al. Incidence, 30-day case-fatality rates, and prognosis of stroke in Iquique, Chile: a 2-year community based prospective study (PISCIS project). *Lancet* 2005; 365: 2206-15.
2. Thrift AJ, McNeil JJ, Forbes A, Donnan GA. Three important subgroups of hypertensive persons at greater risk of intracerebral hemorrhage. *Hypertension* 1998; 31: 1223-29.
3. Dennis MS, Burns P, Sandercock PA, Bamford JM, Wade D, Warlow CP. Long-term survival after first-ever stroke: the Oxfordshire Community Stroke Project. *Stroke* 1993; 24: 796-800.
4. Syed NA, Khealani BA, Ali S, Hasan A, Akhtar N, Brohi H, et al. Ischemic stroke subtypes in Pakistan: The Aga Khan University Data Bank. *J Pak Med Assoc* 2003; 53: 584-8.
5. Foulkes MA, Wolf PA, Price TR, Mohr JP, Hier DB. The Stroke Data Bank: design, method, and baseline characteristics. *Stroke* 1988; 19: 547-54.
6. Khan NZ, Iqbal Z. Cerebrovascular disease, increasing incidence of primary intracerebral hemorrhage-A preliminary report of 100 cases. *Pakistan J Neuro* 1999; 5: 45-9.
7. Sacco RL, Mayer SA. Epidemiology of intracerebral hemorrhage. IN: Feldmann E, ed. *Intracerebral hemorrhage*. Armonk, N.Y: Futura Publishing, 1994 pp. 3-23.
8. Borderick JP, Brott T, Tamsick T, Huster G, Miller R. The risk of subarachnoid hemorrhage and intracerebral hemorrhage in blacks as compared to whites. *N Engl J Med* 1992; 326: 733-6.
9. O' Donnell HC, Rosand J, Knudsen K, et al. Apolipoprotein E genotype and the risk of recurrent lobar intracerebral hemorrhage. *N Engl J Med* 2000; 342: 240-5.
10. Caplan LR. Intracerebral hemorrhage. *Lancet* 1992; 339: 656-8.
11. Fisher CM. Pathological observation in hypertensive cerebral hemorrhage. *J Neuropathol Exp Neurol* 1971; 30: 536-50.
12. Ruiz-Sandoval JL, Romero-Vargas S, Chiquete E, Padilla-Martinez JJ, Villareal-Careaga J, Cantu C, et al. Hypertensive intracerebral hemorrhage in young people. *Stroke* 2006; 37: 2946-50.
13. Dollberg S, Rosin AJ, Fisher D. A new look at the natural history and clinical features of intracerebral hemorrhage: a clinical CT scan correlation. *Gerontology* 1986; 32: 211-6.
14. Feldmann E. Intracerebral hemorrhage. *Stroke* 1991; 22: 684-91.
15. Aring CD, Merritt HH. Differential diagnosis between cerebral hemorrhage and cerebral thrombosis: a clinical and pathologic study of 245 cases. *Arch Intern Med* 1935; 54: 435-56.
16. Kase CS. Diagnosis and management of intracerebral hemorrhage in elderly patients. *Clin Geriatr Med* 1991; 7: 549-67.
17. Ojemann RG, Mohr JP. Hypertensive brain hemorrhage. *Clin Neurosurg* 1976; 23: 220-44.
18. Arshad M, Iqbal MZ, Yasin M. Spontaneous intracerebral hemorrhage; outcome of surgical treatment. *Professional Med J* 2002; 9: 13-8.
19. Andrew BT, Chiles BW, Olsen WL, Pitts LH. The effect of intracerebral hematoma location on the risk of brain stem compression and on clinical outcome. *J Neurosurg* 1988; 69: 518-22.
20. Faught E, Peters D, Bartolucci A, et al. Seizures after primary intracerebral hemorrhage. *Neurology* 1989; 39: 1089-93.
21. Berger AR, Lipton RB, Lesser ML, Lantos G, Portenoy RK. Early seizures following intracerebral hemorrhage: implication for therapy. *Neurology* 1988; 38: 1363-5.
22. Woodward M, Huxley H, Lam TH, Barzi F, Lawes CM, Ueshima H. A comparison of the associations between risk factors and cerebrovascular disease in Asia and Australia. *Eur J Cardiovasc Prev Rehabil* 2005; 12: 484-91.