

Short Report

Magnetic Resonance Imaging (MRI) findings in White Matter Disease of Brain

Humera Ahsan, Muhammad Zafar Rafique, Fozia Ajmal, Mohsin Wahid, Muhammad Azeemuddin, Farah Iqbal

Department of Radiology, Aga Khan University Hospital, Karachi.

Abstract

Demyelinating and dysmyelinating white matter diseases are important components of neurological problems. Recently, Magnetic Resonance Imaging (MRI) has played a key role in diagnoses of white matter diseases. Therefore, the purpose of the current study is to evaluate the usefulness of MRI in determining the type and frequency of white matter disease.

We studied 35 patients who visited the Radiology Department of the Aga Khan University Hospital (AKUH) for MRI with suspected demyelinating/dysmyelinating disorder from January 2003 to December 2005. Multiple Sclerosis (MS) (17; 48%) and leukodystrophies (10; 29%) were the most common diseases.

The MRI helped identify the sites and types of the lesion precisely and thereby, helped made clearer distinction between various types of white matter diseases. The current study demonstrated the effective use of the imaging and clinical presentation for arriving at the correct diagnosis.

Introduction

Demyelinating and dysmyelinating white matter diseases are important components of neurological problems. White matter diseases include Multiple Sclerosis (MS), Leukodystrophies, Central Pontine Myelinolysis, Acute Disseminated Encephalomyelitis and Progressive Multifocal Leukoencephalopathy. MS is the commonest of all the white matter diseases.¹ Leukodystrophies, which include Disseminated Encephalomyelitis (ADEM)², Central Pontine Myelinolysis^{3,4} and Progressive Multifocal Leukoencephalopathy, are ranked second.^{5,6}

With the ever rising burden of the white matter disease, it is imperative to better understand pathophysiological, clinical and imaging findings for proper management of patients. The advent of Magnetic Resonance Imaging (MRI) has revolutionized the concept of diagnosing and understanding of white matter diseases.¹

Many of the white matter diseases, if detected early, can be cured and MRI plays a vital role in its early diagnosis.⁷ MRI is considered far superior to Computed Tomography (CT) and the imaging modality of choice in

white matter diseases. CT does not detect subtle lesions especially in stages of clinical inactivity and is not ideal in posterior fossa imaging due to the beam hardening artifacts.⁸ The multiplanar imaging capability and very high sensitivity for demyelinating foci due to its excellent gray-white matter resolution make MRI imaging the modality of choice.⁹ Through MRI, simultaneous imaging of spinal cord and orbits can also be done. Moreover, with the advent of multi-echo sequences of MR, even subtle lesions of demyelination can be detected.¹⁰

The purpose of the current study is to evaluate the frequency of white matter disease among suspected cases of demyelinating disorders in our setting. Further the study will also look into use of MR imaging features in diagnosis of white matter disease and relate it with clinical findings.

Patients, Methods and Results

We conducted a descriptive study of the patients who had their MRI brain done with clinical suspicion of demyelinating disorder at the Radiology Department of The Aga Khan University Hospital (AKUH) from January 2003 to December 2005.

Forty eight patients visited the department during the study period. However, thirteen were excluded due to prior diagnosis of white matter disease and/or incomplete medical records. Thirty five patients were finally included in the study. The MRI examination features of these patients were highly suggestive of demyelinating or dysmyelinating diseases.

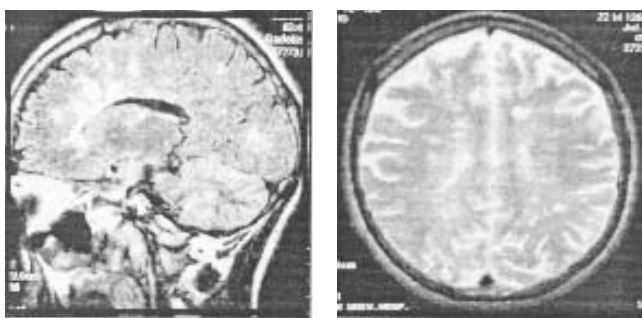
All the patients were examined with 1.5 Tesla systems (Toshiba Medical System). Head coil was used in all the patients. A combination of T1 and T2 weighted and FLAIR sequences and post gadolinium T1 weighted was obtained in each patient.

Each MR image was interpreted by two Radiologists proficient in reporting brain MRI. In case of difference of opinion, consensus was developed through discussion between the two radiologists.

The diagnosis was confirmed by laboratory findings of CSF oligoclonal band in patients with MS. Among cases of acute disseminated encephalomyelitis and leukodystrophies, the diagnosis was established through typical imaging findings and clinical course without any relapse. MRI

Table 1. MR Imaging findings of various white matter diseases.

S.No	Disease	MR Imaging Findings
1.	Multiple Sclerosis	T2 and FLAIR hyperintensity in pericallosal area white matter, cervical spinal cord, pons and posterior part optic nerve.
2.1	Metachromatic Leukodystrophy	T2 and FLAIR hyperintense signal in periventricular white matter in frontal and peritrigonal area.
2.2	Leigh disease	T2 and FLAIR hyperintensity in deep grey matter nuclei, tegmentum, thalami, periventricular white matter, periequiductal region and dentate nuclei
2.3	Adrenoleukodystrophy	T2 and FLAIR hyperintensity in deep peritrigonal white matter, Ventriculomegaly
2.4	Alexander's disease	Periventricular hyperintensity in the frontal lobe with post contrast enhancement and a cyst in the third ventricle
2.5	Niemans Pick disease	Subcortical Gliosis in the frontal and Temporal lobe, brain atrophy.
3.	Central Pontine Myelinolysis	Hyperintense signal in the pons in all cases and in the peripheral portion of left putamen and in head of caudate nucleus in one case
4.	Acute Disseminated Encephalomyelitis	Asymmetrical hyperintense signals in the subcortical white matter of frontal, parietal and occipital lobe and cerebellum with enhancement on post contrast scans.
5.	Progressive Multifocal Leukoencephalopathy	Abnormal signal in deep white matter in frontal regions parietooccipital regions, putamen and midbrain



1a.

1b.

Figure 1: MRI of the brain, (a) Sagittal Flair and (b) Axial T2 weighted images, in a case of Multiple Sclerosis showing typical periventricular and pericallosal location of the lesions.

features of all the patients are shown in Table.

Our study included 35 patients of white matter diseases: 14 (40%) males and 21 (60%) females. The majority of patients suffered from MS 17 (48%): 10 (58.8%) females and 7 (41.2%) males with average ages of

32 and 31 years respectively. MRI revealed multiple lesions confined to the white matter appearing hypo-intense on T1W and hyper-intense on T2W images. In all the patients at least three or more lesions were seen. The majority of the lesions were less than one cm. in size. The commonest sites of involvement were the periventricular and pericallosal area (Figures 1a and b). The other sites were centrum semi-ovale, deep white matter and sub cortical white matter of left frontal lobe, parietal lobe, parieto-occipital region, left temporal lobe, cervical spinal cord, right pons and posterior part of left optic nerve.

Leukodystrophies, which include Metachromatic Leukodystrophy and Adrenoleukodystrophy, Alexander's and Niemen Pick Diseases, were the other most common group of white matter diseases. The results showed that 10 (28.6%) patients, 7 (70%) males and 3 (30%) females, suffered form leukodystrophies. Each type of leukodystrophy presented with different frequencies and MRI findings.

Three patients, all males with an average age of 4 years, suffered from metachromatic leukodystrophy. The commonest site was periventricular white matter. On the other hand, adrenoleukodystrophy was seen in three patients. The average age was three years. The abnormal signals of deep periventricular white matter specifically in trigonal area with ventriculomegaly were observed in two out of three patients.

Leigh disease was diagnosed in two cases. The MR showed hyperintense signal on T2 weighted images in deep grey matter nuclei, tegmentum thalami, periventricular white matter, periequiductal region and dentate nuclei.

One patient showed signs of Alexander's disease. The MRI showed periventricular hyperintensity in the frontal white matter with a cyst in the third ventricle and post contrast periventricular enhancement. Similarly, one patient had Niemen Pick Disease. MRI showed Gliosis in the frontal and temporal lobes

The Central Pontine Myelinosis was ranked third among the white matter diseases identified. Three (8.5%) patients, two males and one female, had the disease. T2 signal changes were seen in the pons in all cases on MRI.

One male patient suffered from Progressive Multifocal Leukoencephalopathy. He was 30 years old and tested positive for Human Immunodeficiency Virus (HIV). MRI showed abnormal signal intensity in deep white matter of brain in right frontal regions, parietooccipital regions, putamen and midbrain. The signals were isointense on T1 and hyperintense on T2 weighed images.

Acute Disseminated Encephalomyelitis was identified in four patients. T2 weighted and FLAIR images

showed asymmetrical hyperintense signals in the subcortical white matter of frontal, parietal and occipital lobe and cerebellum.

Conclusion

The current study presents the proportion of patients suffering from each type of white matter disease. It also demonstrates the effective use of the imaging and clinical presentation in making the right diagnosis.

White matter diseases are a heterogeneous group of disorders, where the main imaging finding is the abnormal white matter. Although a clinical diagnosis is usually present in these disorders, imaging reinforces the diagnosis in many cases. Thereby, MRI imaging could play a pivotal role in prompt treatment of patients with white matter disease.

References

1. BN Lakhkar, M Aggarwal, JR John. MRI in White Matter Diseases - Clinico Radiological Correlation. *Ind J Radiol Imag* 2002 12:1:43-50.
 2. Honkaniemi J, Dastidar P, Kahara V, Haapasalo H. Delayed MR imaging changes in acute disseminated encephalomyelitis. *Am J Neuroradiol* 2001; 22:1117-24.
 3. Miller GM, Baker HL Jr, Okazaki H, Whisnant JP. Central pontine myelinolysis and its imitators: MR findings. *Radiology*1988; 168:795 -802.
 4. Rippe DJ, Edwards MK, D'Amour PG, Holden RW, Roos KL. MR imaging of central pontine myelinolysis. *J Comput Assist Tomogr*1987; 11:724 -6.
 5. Whiteman ML, Post MJ, Berger JR, Tate LG, Bell MD, Limonte LP. Progressive multifocal leukoencephalopathy in 47 HIV-seropositive patients: neuroimaging with clinical and pathologic correlation. *Radiology* 1993;187:233-40.
 6. Post MJ, Yiannoutsos C, Simpson D, Booss J, Clifford DB, Cohen B, et al. Progressive multifocal leukoencephalopathy in AIDS: are there any MR findings useful to patient management and predictive of patient survival? AIDS Clinical Trials Group, 243 Team. *AJNR Am J Neuroradiol* 1999; 20:1896-906
 7. Runge VM, Price AC, Kirshner HS, Allen JH, Partain CL, James AE Jr. Magnetic resonance imaging of multiple sclerosis: a study of pulse technique efficacy. *Am J Roentgenol* 1984; 143: 1015-26.
 8. Francis GS, Evans AC, Arnold DL. Neuroimaging in multiple sclerosis. *Neurol Clin* 1995; 13 147-71.
 9. Chopra JS, Radhakrishnan K, Sawhney BB, Pal SR, Banerjee AK. Multiple sclerosis in North West India. *Acta Neurol Scand* 1980; 62: 312-21.
 10. Paty DW, Oger JJ, Kastrukoff LF, Hashimoto SA, Hooge JP, Eisen AA et al. MRI in the diagnosis of MS: a prospective study with comparison of clinical evaluation, evoked potentials, oligoclonal banding, and CT. *Neurology* 1988; 38: 180-5.
-