

## Mammary analogue secretory carcinoma of the parotid gland: A rare tumour entity

Syeda Tehmina Junaid<sup>1</sup>, Soima Ali Muhammad<sup>2</sup>, Zeba Ahmed<sup>3</sup>, Khubeb<sup>4</sup>, Rajesh Kumar Vasandani<sup>5</sup>, Jawad Ahmed<sup>6</sup>

### Abstract

Mammary analogue secretory carcinoma (MASC) is a salivary gland tumour with low-grade potential and specific FTV6 derangement having translocation of chromosomes t (12;15) (p13;q25). It shares a similar morphological as well as an immunohistochemical profile with secretory carcinoma (SC) of the breast making it a diagnostic enigma.

In this report, we discuss the case of a 65-year-old male patient, who presented with a complaint of right-sided facial swelling. To rule out the differential, he underwent various diagnostic modalities, including magnetic resonance imaging, fine-needle aspiration and its the tumour's microscopic and immunohistochemical properties were also reviewed. Parotidectomy along with concurrent chemo-radiotherapy was performed to eradicate the growing mass.

**Keywords:** Mammary analogue secretory carcinoma, immunohistochemical, Parotidectomy.

**DOI:** <https://doi.org/10.47391/JPMA.5472>

**Submission completion date:** 07-12-2021

**Acceptance date:** 07-07-2022

### Introduction

Mammary analogue secretory carcinoma (MASC) of the salivary gland was first described by Skálová et al<sup>1</sup> and recognised as a separate tumour in the fourth edition of the head and neck WHO classification in 2017.<sup>2</sup> MASC is a rare entity and the exact number of cases is not known. It is estimated that it accounts for less than 0.3 % of all salivary gland tumours around the world.<sup>3</sup> MASC is a secretory carcinoma of the salivary gland that resembles secretory carcinoma of the breast in terms of morphology and immunohistochemically with a specific derangement of ETV6-NTRK3 gene fusion with translocation t (12;15) (p13; q25).<sup>1</sup>

<sup>1,3,5</sup>Department of ENT, Head and Neck Surgery, Dow Medical College, Dow University of Health Sciences and Civil Hospital, Karachi, Pakistan; <sup>2</sup>4th Year MBBS Student, Dow University of Health Sciences, Karachi, Pakistan; <sup>4</sup>Department of ENT, Civil Hospital, Karachi, Pakistan; <sup>6</sup>Department of Internal Medicine, Dow University of Health Sciences, Karachi, Pakistan.

**Correspondence:** Soima Ali Muhammad.

e-mail: [soimaalimuhammad@gmail.com](mailto:soimaalimuhammad@gmail.com)

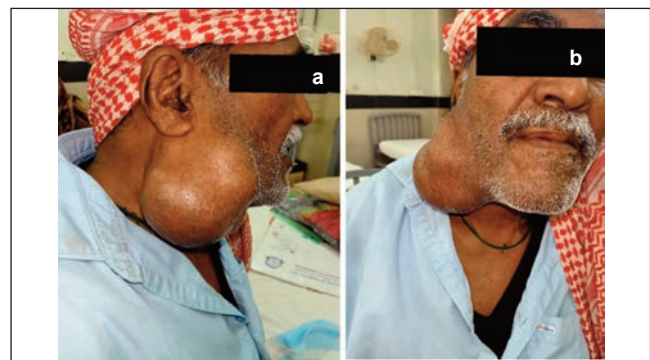
ORCID ID. 0000-0002-5197-8338

MASC is a rare type of tumour, with low aggressiveness; however, it may show locally advanced disease in some cases along with lymph node involvement.<sup>4</sup> It is reported equally in both genders, though a slight male predominance has been shown in some studies.<sup>5</sup> The most common predisposing factors for the salivary gland are age, radiation exposure, smoking, and family history.<sup>6</sup>

Cases of MASC have rarely been reported in Pakistan, with none in public-sector hospitals so far with diagnosis and surgical management taken into account. Here, we present a case with a prolonged history of tumour growth, i.e. around nine years. The case has been reported after taking informed consent.

### Case Presentation

A 65-year-old male, a known case of hypertension, presented in the out-patient department (OPD) of the ear, nose, and throat (ENT) Unit-II on April 22, 2021, at Dr Ruth K. M. Pfau Civil Hospital, Karachi, with right-sided facial swelling for nine years. The swelling was gradual in onset and progressive in nature. It was painless throughout the course, except for the last four months before the surgery. The pain was gradual in onset, mild in intensity and dull in character. Blood-stained discharge with no odour was exhibited for the past two months. He lost a few pounds weight during this period. The patient had no family history of the disease. On examination, the swelling was 10 cm x 10 cm in size, extending from the Temporomandibular Junction to the angle of mandible, with the overlying skin intact but slightly discoloured, ill-defined margins, and immobile (Figure 1).

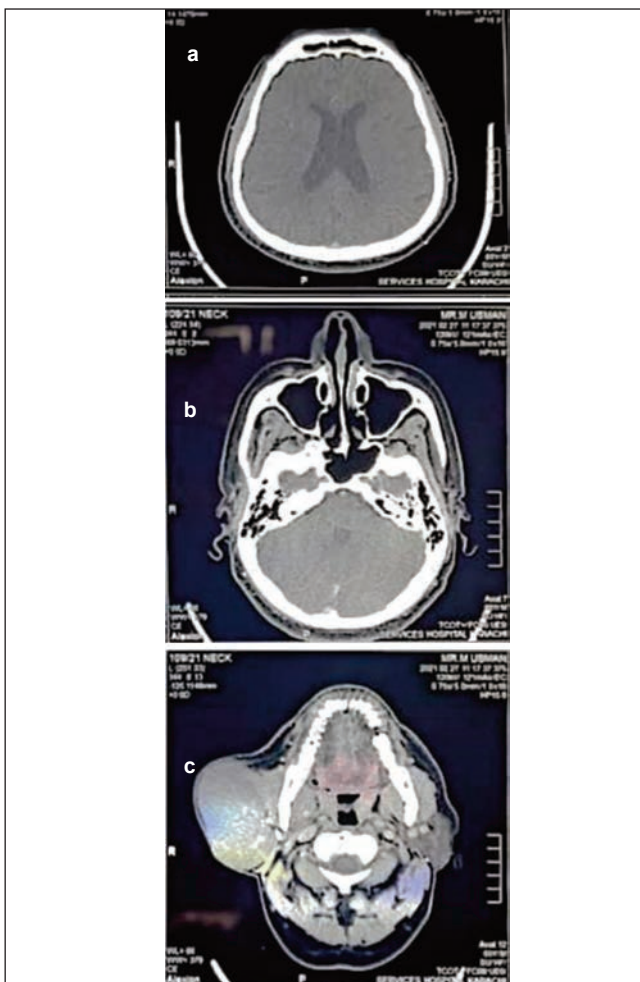


**Figure-1:** Patient identity hidden for ethical reasons. Pre-operative images of the patient showing right lateral facial swelling. (a) lateral view. (b) Anterior view.

**Table:** Routine investigations.

Investigations	Patient values	Reference values
Haemoglobin level	11.2 mg/dl	13.3-16.6 mg/dl
Mean corpuscular volume (MCV)	92.1fl	78.2-97.9 fl
Mean corpuscular haematocrit (MCH)	30 pg	27-32 pg
Total leukocyte counts (TLC)	8.9 billion cells/L	3.9-9.6 billion cells/L
Platelets count	163 billion/L	135-317 billion/L
Prothrombin time (PT)	10.3 secs	11-13.5 secs
International normalised ratio (INR)	0.98	0.8-1.1
Glycated Haemoglobin (HbA1c)	5.4%	4%-5.6%
Blood urea nitrogen (BUN)	9 mg/dL	8-20 mg/dL
Creatinine	0.8 mg/dL	0.74-1.35 mg/dL
Sodium (Na)	138 mEq/L	135-145 mEq/L
Potassium (K)	4.1 mmol/L	3.5-5 mmol/L
Chloride (Cl)	103 mEq/L	96-105 mEq/L
Bilirubin	0.7 mmol/L	0.1-1.2 mmol/L
Serum glutamic-pyruvic transaminase (SGPT)	16 units/L	7-56 units/L
Alkaline phosphatase (ALP)	122 IU/L	44-147 IU/L

mg/dL: milligram per decilitre; fl: femtolitre; mEq/L: mill equivalent per litre; mmol/L: millimoles/litres; IU/L: international unit per litre

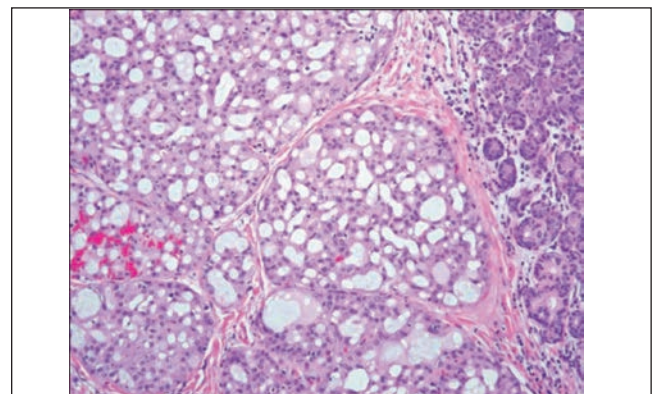


**Figure-2:** The magnetic resonance imaging (MRI) scan: (a) axial 2 (b) axial 7 (c) axial 12.

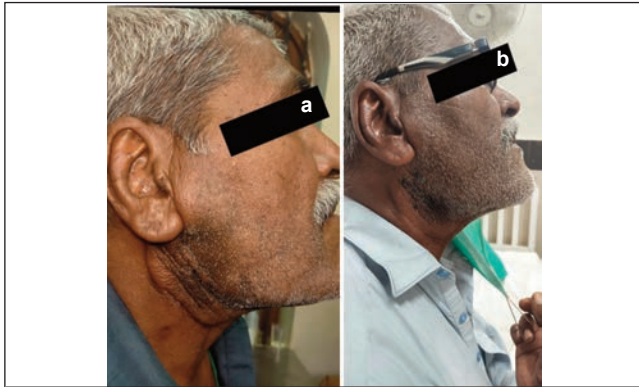The swelling was non-tender, soft, firm, compressible, non-reducible, and non-pulsatile. It could not be trans-illuminated and had a normal temperature. No enlarged lymph nodes were noted. The routine lab investigations are shown in table.

The magnetic resonance imaging (MRI) (Figure 2) indicated a large multicystic lipomatous lesion of 9.0x8.5x5.6 LS x AP x TS dimensions involving the superficial and deep lobes of the right parotid gland. It was grossly exophytic and laterally produced bulges over the skin. Multiple septations were present with suggestions of haemorrhage inside. Overall there was a diffuse hyper intense imaging with complete suppression of STIR imaging, representing fat elements.

However, on the medial side, there was particular hyperintensity on T1 and hypo-intensity on T2, indicating haemorrhage. No bony erosion or cervical lymphadenopathy was noted. The findings represent a lipomatous lesion. Superiorly, it ended just below the level of the right temporomandibular joint against the ramus of the right hemi-mandible without any bony erosion or abnormal signs in it. It was causing compression over the right masseter muscle. Medially, it was closely abutting the pterygoid muscle. Posteriorly, it was causing compression over the right sternocleidomastoid muscle. Inferiorly, it extended up to the root of the extended neck and ended at the level of the thyroid gland. No intraoral extension and evidence of bilateral cervical lymphadenopathy were seen. The Fine Needle Aspiration Cytology (FNAC) showed lymphocytosis and benign-looking cells with a haemorrhagic background. The cyst identified with the tail of the parotid gland was excised and the sample was sent for biopsy.



**Figure-3:** Microscopic examination of the MASC showed fibro collagenous tissues with an infiltrating neoplastic lesion with variable cystic papillary, glandular, and focal solid architecture. The marginal portion showed a moderate amount of cytoplasm in the cells with an enlarged nucleus and prominent nucleoli, and few scattered mitoses. The cystic glandular substance is filled cystic and glandular eosinophilic substance.



**Figure-4:** Post-operative images after Parotidectomy showing scar marks. (a) One week after the surgery. (b) One month after the surgery.

Microscopic examination of the sample revealed fibrocollagenous tissues with an infiltrating neoplastic lesion with variable cystic papillary, glandular, and focal solid architecture. The marginal portion showed a moderate amount of cytoplasm in the cells with an enlarged nucleus and prominent nucleoli, and a few scattered mitoses. Perineural invasion was also present. The cystic and glandular spaces were filled with eosinophilic and basophilic substances. Immunohistochemistry showed positive immunoreactivity for S100 and mammaglobin stains and negative for PAX-8 and TTF-1. The tumour cells also showed positivity for Cytoskeleton AE1/AE3. (Figure 3)

Surgical excision of the parotid cyst under general anaesthesia was planned. The operation procedure included an abdominal aorta aneurysm (AAA) measured with the patient lying supine with head towards the left and local anaesthesia was infiltrated. The patient was placed in the supine position with head towards the left side. He was planned to undergo superficial lobe parotidectomy i.e. removal of portion of parotid gland superior to facial nerve. A modified S-shaped Blair incision was made extending from the preauricular region moving around the ear lobe toward the mastoid process and then downward to meet the fold of the neck, below the angle of the mandible. The skin incision was through the subcutaneous tissue and platysma muscle along with greater auricular nerve. Then, an anterior flap was elevated superficial to the greater auricular nerve and parotid fascia and posterior-inferior flap exposing the tail of the parotid gland. The tail of the parotid gland was dissected off of the sternocleidomastoid muscle by dissecting deep to the posterior branch of the greater auricular nerve. Next, the posterior belly of the digastric muscle was exposed with further elevation of the tail of the parotid gland. The posterior belly of the digastric muscle served as a landmark for the facial nerve.

During elevation of the tail of the parotid, the integrity of

the posterior facial vein was also preserved if possible. Once the facial nerve was identified, the parotid gland superficial to the facial nerve was divided carefully, preserving the integrity of the nerve. Finally, the desired portion of the gland was dissected from the facial nerve branches. The superficial lobe parotidectomy was performed under the supervision of senior doctors and consultant. Now, the wound was carefully inspected and bleeding sites were controlled with bipolar electro cautery or ligatures. It was irrigated, realigned and closed in layers over a closed suction drain. A Redivac drain 14Fr was placed and removed on the post-operative day. On discharge, the patient was advised analgesia for pain relief with daily dressing with antiseptic till the next follow-up. The next follow-up after one week included removal of skin sutures and further evaluation of the operative side for any complication. (Figure 4)

The case was further discussed at the tumour board meeting at Civil hospital, Karachi, and concurrent chemoradiotherapy (CCRT) at Jinnah Postgraduate Medical Centre (JPMC) was recommended. The patient was counselled and consented for chemoradiotherapy but was lost to extended follow-up due to poor socio-economic background and old age.

## Discussion

Mammary gland analogue secretory carcinoma (MASC) is a low-grade benign tumour with a rare malignant course. It has a slightly male predominance in adults with an average age of 45 years. MASC often shares similar microscopic features with other tumours, such as acinic cell carcinoma (AciCC), adenocarcinoma not otherwise specified (NOS), etc. Skálová et al,<sup>1</sup> in his study, discussed that MASC shares similar chromosomal translocation of t (12;15) (p13; q25) as the secretory carcinoma (SC) of the breast and is different from AciCC. It possesses a recurrent balanced chromosomal translocation t (12;15) which results in a fusion gene among the ETV6 gene on chromosome 12 and the NTRK3 gene on chromosome 15.<sup>1</sup>

Mammary analogue secretory carcinoma commonly presents in the parotid gland in about 70% of cases, the submandibular gland in 7% of cases, and, rarely, different sites, which include the soft palate, buccal mucosa, tongue base, and lips.<sup>7</sup> MASC is an indolent tumour, with the course of a slow, painless mass of about 2cm and a time period ranging from two months to several years.<sup>4</sup> Histologically, the MASC tumour shows a lobulated appearance in an eosinophilic background with an excessive extracellular secretory material. Different types of morphologies have been presented by MASC, including microcystic, macro cystic, papillary, tubular, and solid



structures. The tumour is well-circumscribed with the cystic and papillary patterns of septae, and is often characterised by a proliferation of small to medium-sized cells with eosinophilic and vacuolated cytoplasm and small nuclei.<sup>8</sup> Lymphovascular and perineural invasion is an uncommon occurrence in MASC. In the present case, MRI indicated a multicystic mass of 9.0x8.5x5.6 cm, involving the superficial and deep lobes of the right parotid gland. It exhibited variable cystic papillary, glandular, and focal solid architecture, histologically. The cystic and glandular spaces were filled with eosinophilic and basophilic substances and the marginal portion showed cells with an adequate amount of cytoplasm, enlarged nucleus, and marked prominent nucleoli and few scattered mitoses. Perineural invasion was also present.

MASC is immunoreactive for mammaglobin, vimentin, S-100, and epithelial membrane antigen. These tumours are "triple-negative" i.e. non-immunoreactive for progesterone/estrogen receptors and negative for Her2/Neu mutation. It demonstrates diffuse and strong expression of epithelial membrane antigen (EMA), CK7, CK8, CK18, CK19, and pan-cytokeratin (AE1-AE3 and CAM 5.2).<sup>7</sup> Immunohistochemistry of our case showed positive immunoreactivity for S100 and Mammaglobin stains and negative for PAX-8 and TTF-1. The tumour cells also showed positivity for Cytoskeleton AE1/AE3.

Despite the fact that morphologic and immunohistochemical properties form the basis of the MASC diagnosis, recent advances in cellular immunisation offer new possibilities in the investigation for both diagnosis and reduction of disease in salivary gland oncology. Molecular genetic testing confirming the presence of ETV6-NTRK3 fusion is considered the definitive diagnosis.<sup>5</sup> Thus far, the presence of the ETV6-NTRK3 fusion gene has not been demonstrated in any other salivary gland tumour. Genetic testing was done in this case due to financial constraints. Sethi et al<sup>9</sup> reported 91 cases of MASC documented in his paper, with mortality of only four cases. Survival data was variable and follow-up was minimal.<sup>9</sup> MASC currently follows the same treatment options as for low-grade neoplasm of salivary gland, i.e. surgical excision/neck dissection for the benign course and adjuvant excision with chemo and radiotherapy reserved for malignant metastatic disease.<sup>10</sup> In the present case, the patient underwent surgical excision i.e. parotidectomy followed by radiotherapy adjuvant with chemotherapy.

## Conclusion

A rare case of mammary analogue secretory carcinoma in Civil Hospital, Karachi, was diagnosed by different morphologic and immunohistochemical modalities with total parotidectomy performed, which was followed by radiotherapy adjuvant with chemotherapy as a choice of treatment. The aim of this report is to enhance the knowledge about this rare entity for ear, nose, and throat care providers.

**Disclaimer:** None.

**Conflict of interest:** The co-authors of this manuscript belong to the same department i.e. ENT Unit-II.

**Funding disclosure:** None.

## References

1. Skalova A. Mammary analogue secretory carcinoma of salivary gland origin: an update and expanded morphologic and immunohistochemical spectrum of recently described entity. *Head Neck Pathol* 2013;7(Suppl 1):s30-6. doi: 10.1007/s12105-013-0455-y.
2. Seethala RR, Stenman G. Update from the 4th Edition of the World Health Organization Classification of Head and Neck Tumours: Tumors of the Salivary Gland. *Head Neck Pathol* 2017;11:55-67. doi: 10.1007/s12105-017-0795-0.
3. Boliere C, Murphy J, Qaisi M, Manosca F, Fung H. Mammary Analogue Secretory Carcinoma of the Palate: Case Report and Review of the Literature. *Case Rep Dent* 2019;2019:e7416302. doi: 10.1155/2019/7416302.
4. Suzuki K, Yagi M, Kanda A, Kobayashi Y, Konishi M, Miyasaka C, et al. Mammary Analogue Secretory Carcinoma Presenting as a Cervical Lymph Node Metastasis of Unknown Primary Site: A Case Report. *Case Rep Oncol* 2017;10:192-8. doi: 10.1159/000457949.
5. Nisar Z, Pol JN, Jagdale RV, Phadke MD, Kadkol GA. Mammary analogue secretory carcinoma: An Indian experience of a novel entity. *Indian J Pathol Microbiol* 2020;63(Suppl 1):s134-40. doi: 10.4103/IJPM.IJPM\_757\_18.
6. Pan SY, de Groh M, Morrison H. A Case-Control Study of Risk Factors for Salivary Gland Cancer in Canada. *J Cancer Epidemiol* 2017;2017:4909214. doi: 10.1155/2017/4909214.
7. Boon E, Valstar MH, van der Graaf WTA, Bloemena E, Willems SM, Meeuwis CA, et al. Clinicopathological characteristics and outcome of 31 patients with ETV6-NTRK3 fusion gene confirmed (mammary analogue) secretory carcinoma of salivary glands. *Oral Oncol* 2018;82:29-33. doi: 10.1016/j.oraloncology.2018.04.022.
8. Sethi R, Kozin E, Remenschneider A, Meier J, VanderLaan P, Faquin W, et al. Mammary analogue secretory carcinoma: update on a new diagnosis of salivary gland malignancy. *Laryngoscope* 2014;124:188-95. doi: 10.1002/lary.24254
9. Khalele BA. Systematic review of mammary analog secretory carcinoma of salivary glands at 7 years after description. *Head Neck* 2017;39:1243-48. doi: 10.1002/hed.24755.