

Modified hepaticocholecystoenterostomy technique for certain hepatobiliary and pancreatic diseases: Case series report by a single surgeon

Tran Hieu Hoc, Tran Que Son

Abstract

Prior to this research, very few reports of hepaticocholecystoenterostomy (HCE) and its modification have been published. Two anastomoses were used to establish a biliary bypass using the gallbladder as a conduit by a senior hepato-biliary surgeon.

Between 2013 and 2019, 11 patients (five men and six women) with a mean age of 61.7 ± 15.7 (range, 31–85) years were seen. Disease indications included periampullary malignant tumours of Vater (7 cases), chronic pancreatitis (1 patient), cystic pancreatic head tumours (2 patients), and choledochal cysts (1 patient). Pancreaticoduodenectomy, bypass, cholangiocarcinoma, and choledochal cystectomy were performed on 4, 4, 2, and 1 patients, respectively. Followup showed no jaundice at all with no recurrent biliary obstruction.

HCE is both safe and effective in a subgroup of patients. This is a treatment of choice in some instances, such as a small common bile duct, a limited surgical field in the hilar area, or a difficult hepaticojejunostomy.

Keywords: case report, hepaticocholecystoenterostomy, hepaticojejunostomy, modified, HCE anastomosis, Vietnam.

DOI: <https://doi.org/10.47391/JPMA.5343>

Submission completion date: 09-12-2021

Acceptance date: 18-06-2022

Introduction

Despite increased awareness of the illness and recent improvements in imaging and diagnostic procedures, the majority of patients with periampullary adenocarcinoma are unresectable at the time of diagnosis. Therefore, palliation of symptoms remains an important component in managing this disease.^{1,2} Indeed, biliary-enteric anastomosis is indicated not only for relief of symptoms of biliary obstruction caused by an unresectable periampullary tumour of Ampulla of Vater,^{2,3} but also following radical surgery such as pancreaticoduodenectomy,⁴ choledochal resection⁵ or

Department of Cardiology, Istanbul Atlas University, School of Medicine, Medicine Hospital, Turkiye.

Correspondence: Zeki Dogan. e-mail: drzeki@yahoo.com

ORCID ID. 0000-0001-6473-0350

treatment of recurrent intrahepatic lithiasis.⁶ Biliary-enteric anastomosis, which mainly includes choledochoduodenostomy (CD) and Roux-en-Y hepaticojejunostomy (RYHJ), is one of the most common procedures. Due to “sump syndrome” (range, 0–5.4%), risk of cholangitis (range, 6.4–10.3%), and high risk of contrast reflux into the biliary tree following CD,⁵ many authors prefer HJ to CD as the standard procedure for benign biliary diseases.^{7–9} Although the patients with stents had a shorter hospital stay, the cost of therapy was higher than that in the open surgery group for biliary-enteric anastomosis.^{10–12} In some situations, the assessment of the actual stage of the disease is limited, and radical surgery is impossible. Therefore, the method of biliary-enteric anastomosis is a suitable choice.

Hepatico-enteric anastomosis is frequently more challenging than choledoenterostomy but leads to better bile flow. This anastomosis can be technically challenging and potentially difficult, especially with large periampullary tumours, a short fatty jejunal mesentery, and intra-abdominal obesity, all of which contribute to poor vision and access difficulties. This is especially true in people with an abnormally high body mass index. Other procedures, such as simple cholecystoenterostomy, have been reported. Furthermore, this anastomosis fails when the tumour invades the cystic duct or when the cystic duct is not dilated. Due to these limitations, the approach has been largely abandoned in clinical practice. Hepaticocholecystostomy and cholecystojejunostomy are indicated as palliative procedures in patients with malignancy of the common duct or the head of the pancreas, causing complete obstruction of the bile flow.¹³ According to Shah et al, tumour spread may impede the gallbladder–intestinal junction.¹⁴ Therefore, numerous surgeons have improved the technique of hepaticocholecystoenterostomy (HCE).^{13–16}

A few papers analysing the outcomes of HCE anastomosis were identified after searching PubMed and Google Scholar for relevant material. The subjects were patients with advanced-stage cancer in the area of the ampulla of Vater, with a median survival of approximately 8–12 months. The surgical procedure was targeted only to relieve obstructive biliary symptoms.^{3,4,17–19}

However, even with benign lesions, the lower bile duct might develop a “sump syndrome”, become infected, or accumulate lithiasis.⁵ As a result, some minor adjustments were done during the HCE anastomosis.

Case Series

From July 2013 to December 2019, pancreaticoduodenectomy were performed on 438 patients, which included 55 cases of choledochectomy and 89 cases of bypass due to periampullary tumours of Vater at the Bachmai Hospital—one of the largest surgical centres in Vietnam. HCE anastomosis was conducted on 11 of the patients. These patients were operated upon by a surgical team led by a gastroenterologist and hepatobiliary surgeon.

Intervention and considerations: At our hospital, blood tests of all patients with surgical indications were done to determine their peripheral blood cells, prothrombin, fibrinogen, liver and kidney functions, blood albumin, and blood type (ABO, Rh), and urinalysis. Simultaneously, the patient underwent echocardiography, electrocardiography, computed tomography, or magnetic resonance biliary reconstruction; gastroduodenal endoscopy was performed to visualise the duodenal mucosa and ampulla of Vater. Patients with total bilirubin levels of more than 250 mmol/L underwent gastroduodenal endoscopic surgery for percutaneous biliary drainage or plastic stenting.

Operative technique: In the event of bypass procedures (as in chronic pancreatitis or advanced periampullary malignancy), the hepatic duct-gallbladder triangle must be dissected and resected (Figure 1). After that, either end-to-end or end-to-side hepaticocholedocal anastomosis was performed (Figures 2b, 2c).

If the tumour was suitable for resection (cholangiocarcinoma or pancreaticoduodenectomy), the following steps should be taken: preserving the gallbladder and performing an anastomosis of the HCE (Figure 2c, 2d).

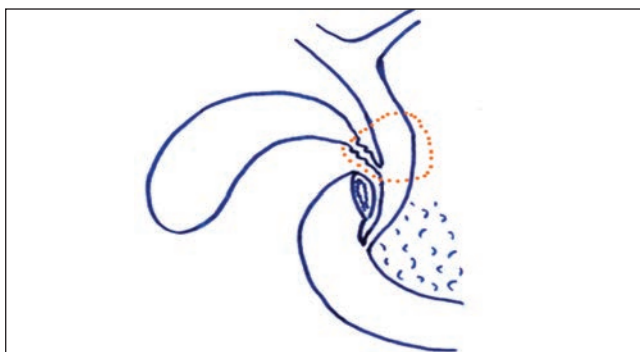


Figure-1: Modified hepaticocholecystoenterostomy technique. Resection of the cystic duct junction and the lower part of the common bile duct (orange dots).

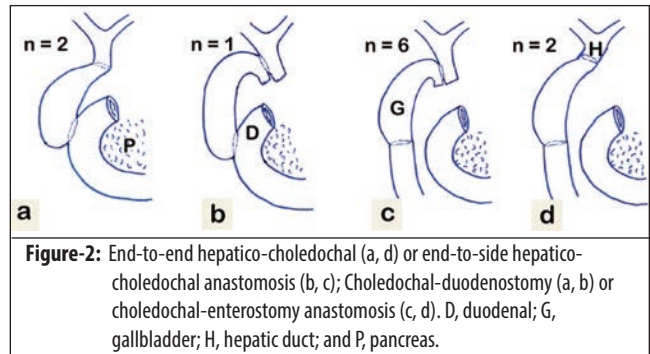


Figure-2: End-to-end hepaticocholedocal (a, d) or end-to-side hepaticocholedocal anastomosis (b, c); Choledochal-duodenostomy (a, b) or choledochal-enterostomy anastomosis (c, d). D, duodenal; G, gallbladder; H, hepatic duct; and P, pancreas.

Outcomes: Patients’ demographics, comorbidities, surgical parameters, and postoperative course, including complications, return to oral food intake, length of stay, and long-term results, were extracted retrospectively from the patients’ files. Postoperative mortality was defined as death within 30 days of surgery or mortality within the same hospital stay. Postoperative morbidity was graded according to the Clavien-Dindo classification²⁰ and Cholangitis according to the Tokyo 2018 classification.²¹ “Palliation failure” was defined as either the inability to regain oral intake or 60-day postoperative mortality. Clinical examination and computed tomography were used to determine metastatic status.

Statistics: SPSS 20.0 (SPSS Inc., Chicago, IL) was used for all statistical analyses.

All patients were informed about the procedure, including its risks and advantages. Written informed consent was obtained from all patients included in our study, approved by the Ministry of Health Ethical Review Board, Vietnam (Decision no. 4230/QĐ-BYT on September 2, 2021).

Private information of all enrolled patients was carefully protected. The study was conducted according to the Declaration of Helsinki guidelines.

This study is being reported in line with the PROCESS 2020 criteria.²²

Results

HCE anastomosis was performed following various surgical procedures, including end-to-end and end-to-side anastomoses in four and seven patients, respectively. During the follow-up period, there were no episodes of obstructive jaundice. Four patients died in the first year after surgery due to advanced cancer.

A total of 11 participants, including five males and six females, underwent surgery. The average age of the patients was 61.7 ± 15.7 years (range, 31–85). Three patients had hepaticocholedocal-duodenostomy (HCD) anastomosis, while eight had hepaticocholedocal-

Table-1: Demographics of study patients.

Case	Sex	Age	Diagnosis*	Management	Technique	Combined method	Follow-up (months)	Recurrent jaundice	Cholangitis	Current status	Alive/Dead
1	F	31	Choledochal cyst (6 mm*)	Cystectomy	HC ₁ J	-	94	No	Yes	Good	Alive
2	M	82	Cholangioma (8 mm*)	Bile duct resection	HC ₁ D	-	12	No	-	-	Dead
3	F	64	PDAC (11 mm*)	Biliary and gastric bypass	HC ₂ D	GE	8	No	No	-	Dead
4	F	85	Cholangioma (12 mm*)	Bile duct resection	HC ₂ D	-	13	No	No	Peritoneal s metastasi	Dead
5	M	64	Early AoV cancer (13 mm*)	PD	HC ₁ J	-	62	No	-	Good	Alive
6	F	54	PDAC (6 mm*)	Biliary and gastric bypass	HC ₂ J	GE	12	No	No	-	Dead
7	F	50	PDAC (4 mm*)	PD	HC ₁ J	-	42	No	Y	Good	Alive
8	M	72	Advantage AoV cancer (12 mm*)	Biliary and gastric bypass	HC ₂ J	GE	40	No	No	Liver metastasis U-GI hemorrhage	Alive
9	F	69	Pancreatic cystadenoma (5 mm*)	PD	HC ₁ J	-	29	No	No	Abdominal wall hernia	Alive
10	M	47	Chronic pancreatitis (12 mm*)	Biliary and gastric bypass	HC ₁ J	GE	26	No	No	Diabetes	Alive
11	M	61	Pancreatic cystadenoma (7 mm*)	PD	HC ₁ J	-	21	No	No	Good	Alive

GE- Gastroenterostomy, HCD: hepatico-choledocal-duodenostomy, PD: Pancreaticoduodenectomy, AoV: Ampullary of Vater, PDAC: Pancreatic Ductal Adenocarcinoma, U-GI: Upper Gastrointestinal. HC₁J: End-to-Side hepatico-choledocal-jejunostomy, HC₂J: End-to-End hepatico-choledocal-jejunostomy, HC₁D: End-to-Side hepatico-choledocal-duodenostomy, HC₂D: End-to-End hepatico-choledocal-Duodenostomy.*Common hepatic duct size (mm).

Table-2: Laboratory findings of the patient.

Characteristics	Gani (2012), n = 30	Sohn (1999), n = 256	This study, n = 3 [†]
Mean Age (years), (min-max)	65.5	64±0.7 (32 – 88)	61.7±15.7 (31 – 85)
Sex, male (%)	19 (63)	146 (57)	2 (66.7)
Peri-operative mortality (%)	0	3.1	0
30-day mortality (%)	0	3.1	0
Mean length of Hospital stay (days)	8.6	10.1	15.2
Mean operative time (minutes)	147	234	165
Re-operation, (%)	3.4	1	0
Leaks (%)	3.4	5	0
Postoperative cholangitis (%)	0	2	0
Mean survival (months)	12	6.5	20

[†]Modifield HCE anastomosis.

jejunostomy (HCJ). Four individuals required a gastroenterostomy anastomosis. In the postoperative follow-up, all patients were free of jaundice. At the end of the study, four patients died between 8 and 13 months from common bile duct cancer (2 patients) and advanced pancreatic head cancer (2 patients) (Table 1).

Seven living individuals exhibited no evidence of biliary obstruction, two had biliary tract infection, and one had liver metastases along with an episode of upper gastrointestinal bleeding (Table 1 and Figure 2).

In three patients with advanced cancer, surgical bypass (2 cases of pancreatic cancer, 1 case of the ampulla of Vater cancer) was considered. Eight and 12 months were the median survival times for the two pancreatic cancer patients, respectively. Patients with ampulla of Vater cancer were still alive but had late-stage liver metastases, with no complications following surgery (Table 2).

Discussion

HCE is indicated as a palliative procedure in patients with cholangiocarcinoma or malignancy of the head of the pancreas causing complete obstruction of the bile flow.¹³ Many surgeons have improved the procedure for joining the hepatic duct to the intestine via the gallbladder.¹³⁻¹⁶ Gani also described 30 patients who developed biliary obstruction due to unresectable pancreatic cancer (Whipple surgery) and failed endoscopic stent implantation, necessitating bypass. The author noted that HCE is a safe and long-lasting procedure with survival and complication rates comparable with hepaticojejunostomy. It is also a simple technique that is easily performed by nonhepatobiliary surgeons. In many situations, surgical dissection of the cystic region of the gallbladder (Hartmann's pouch) is necessary to connect the common hepatic duct without distension and conduct a sufficient lateral-to-side anastomosis approximately 1-1.5cm long. The gallbladder fundus can be attached to either the duodenum or the jejunum. However, the problem of HCE anastomosis is that it results in the formation of sump syndrome. There will be stasis within this sac, resulting in biliary tract infection and the formation of stones. Additionally, malignant tumours may proceed to block the liver-gallbladder duct junction. Compared to a normal RYHJ, HCE allows for better access and visibility (to facilitate the anastomoses). These anastomoses are indeed relatively easy to conduct. To avoid straining the hepaticocholedocal anastomosis, the cystic duct area must be mobilised.¹⁴

However, this approach has the potential to injure the gallbladder artery.²³

For bypass surgery, the modified HCE procedure was determined. Given that approximately 20% of pancreatic cancers are resectable at diagnosis, surgical bypass remains critical for palliating patients who have been diagnosed with the unresectable disease during a trial dissection for a Whipple procedure. It can also be utilised as a substitute for percutaneous transhepatic stent implantation in selected patients when endoscopic biliary stenting fails.²³ According to the literature, sump syndrome can occur due to the side-to-side biliary-enterostomy anastomosis. This symptom results in biliary tract infection, gallstones, and, in the worst-case situation, a hepatobiliary tract abscess, which ruptures and results in peritonitis and intra-abdominal abscess.^{5,8} As a result, the HCE approach was modified in patients who underwent hepaticojejunostomy and gastrojejunostomy for palliative treatment (Figures 1 and 2). Monocryl 4.0 sutures were used to produce a 1-1.5cm long hepaticocholedocal anastomosis. This anastomosis had several noteworthy characteristics. First, it is necessary to maintain the gallbladder artery. To avoid damaging the artery, only the tissues around the cystic duct were dissected and not deep into the Calot's triangle. Second, the principle should be to avoid lacerating the portal vein. In situations of severely invasive cholangiocarcinoma, a hepaticocholedocal anastomosis should be placed above the neoplasm.

HCE anastomosis was performed after pancreaticoduodenectomy (PD). A low rate of stricture formation, ranging from 2.6% to 7.4%, was described when HCE was performed after PD.^{24,25} A small extrahepatic bile duct is highly valued among the predictors to be significantly associated with the outcome.^{4,24,25} Therefore, to reduce the risk for biliary-enteric anastomotic stricture, cholangioplasty is preferred in patients with a nondilated extrahepatic bile duct ($\leq 6\text{mm}$) during PD.⁴ At the time of surgery, none of the four patients had dilated biliary tracts. In this case, a patient developed biliary obstruction due to ampullary carcinoma of Vater but was treated with a biliary stent before surgery. The remainder of the cases involved pancreatic cancer and pancreatic head cysts. HCE anastomosis was used in certain instances to expand the anastomosis.

HCE was followed by choledochal cyst (CC) resection. A type I CC is associated with a risk of malignancy with the patient's age and is documented in the literature. The reported frequency varies from 2.5% to 28%, with up to 50% in patients over 50 years old.^{8,26} To decrease the complexity of the reconstruction in difficult situations and decrease the risk of anastomotic stricture, according to

some reports, 0.5–1.0 cm of the proximal cyst wall could be left behind to facilitate biliary anastomosis.^{8,27} Furthermore, the frequency of long-term postoperative anastomotic malignant transformation, after the proximal cystic wall remnant is left behind, is 0.7–5.4%, which is higher than that in the general population.^{8,28} Total resection of the CC combined with Roux-en-Y hepaticojejunostomy (RYHJ) is the most frequently accepted technique because of its simplicity and minimal risk of postoperative malignancy.⁸ The patients in this study were type I (Todani) with a 6mm diameter common hepatic duct. Therefore, all common bile duct cysts were resected which is recommended while preserving the gallbladder to perform HCE anastomosis. This procedure has been used to completely remove CCs. In this instance, HCE anastomosis was extremely useful for relieving tension while remaining relatively narrow.

For cholangiocarcinoma, biliary obstruction is frequently caused by common bile duct malignancy. High bilirubin levels require biliary stenting or percutaneous biliary drainage before surgery. The above measures restore liver function. This causes difficulty connecting the hepaticoenterostomy and increases the risk of anastomosis constriction.^{24,25} When the hepatic duct is small, or the tumour cannot be resected, an HCE anastomosis is reasonable.²³

This study has some strengths. It was noted that constructing an HCE anastomosis was simple and had no postoperative complications. During the follow-up period, no case of recurrent biliary obstruction necessitating biliary drainage or reoperation was observed. In situations where the hepatic duct was not dilated, the hilar vision was limited, the tumours were enormous, and the small bowel mesentery was limited. This approach was used to enlarge (instead of stretch) the hepaticoenterostomy anastomosis. This technique was performed to avoid sump syndrome in benign tumours (chronic pancreatitis- Patient No.10, pancreatic head cyst).

This study has some limitations. First, the study does not have a comparison group. Second, cancer patients failed to assess the efficacy of chemotherapy following surgery. Third, the number of patients is limited. Fourth, the procedure was conducted at a single centre by an experienced hepatobiliary and pancreatic surgeon. As a result, it is impossible to determine the technique's learning curve. This procedure should not be used if the gallbladder is inflamed or the gallbladder artery is injured during surgery. In the future, it will be important to establish patient eligibility criteria for this procedure, e.g., is it indicated for the malignant group? Is this method necessary for common bile duct cysts, or is the hepatic duct not dilated?

Conclusion

The findings indicate that HCE is an effective and long-lasting bypass procedure. Periapillary cancer patients with locally progressed or metastatic disease will benefit from hepaticojejunostomy. We suggest the HCE approach to all abdominal surgeons as a safe technique suitable for specialised (hepatobiliary) and general surgeons.

Disclaimer: None.

Conflict of Interest: None.

Funding Sources: None.

References

- Sohn TA, Lillemoe KD, Cameron JL, Huang JJ, Pitt HA, Yeo CJ. Surgical palliation of unresectable periampullary adenocarcinoma in the 1990s. *J Am Coll Surg* 1999;188:658-9. doi: 10.1016/s1072-7515(99)00049-6.
- Kneuert PJ, Cunningham SC, Cameron JL, Torrez S, Tapazoglou N, Herman JM, et al. Palliative surgical management of patients with unresectable pancreatic adenocarcinoma: trends and lessons learned from a large, single institution experience. *J Gastrointest Surg* 2011;15:1917-27. doi: 10.1007/s11605-011-1665-9.
- Pencovich N, Orbach L, Lessing Y, Elazar A, Barnes S, Berman P, et al. Palliative bypass surgery for patients with advanced pancreatic adenocarcinoma: experience from a tertiary center. *World J Surg Oncol* 2020;18:63. doi: 10.1186/s12957-020-01828-5.
- Zhu J, Kou J, Dong H, Ma J, Liu H, Bai C, et al. Biliary reconstruction with a pedicled gallbladder flap in patients during pancreaticoduodenectomy. *J Surg Res* 2018;225:76-81. doi: 10.1016/j.jss.2018.01.004.
- Yeung F, Fung ACH, Chung PHY, Wong KKY. Short-term and long-term outcomes after Roux-en-Y hepaticojejunostomy versus hepaticoduodenostomy following laparoscopic excision of choledochal cyst in children. *Surg Endosc* 2020;34:2172-7. doi: 10.1007/s00464-019-07004-5.
- Li SQ, Liang LJ, Peng BG, Lai JM, Lu MD, Li DM. Hepaticojejunostomy for hepatolithiasis: a critical appraisal. *World J Gastroenterol* 2006;12:4170-4. doi: 10.3748/wjg.v12.i26.4170.
- Okamoto H, Miura K, Itakura J, Fujii H. Current assessment of choledochoduodenostomy: 130 consecutive series. *Ann R Coll Surg Engl* 2017;99:545-9. doi: 10.1308/rcsann.2017.0082.
- Ma W, Tan Y, Shrestha A, Li F, Zhou R, Wang J, et al. Comparative analysis of different hepatico-jejunostomy techniques for treating adult type I choledochal cyst. *Gastroenterol Rep (Oxf)* 2018;6:54-60. doi: 10.1093/gastro/gox025.
- Schreuder AM, Franken LC, van Dieren S, Besselink MG, Busch OR, van Gulik TM. Choledochoduodenostomy versus hepaticojejunostomy - a matched case-control analysis. *HPB* 2021; 23:560-5. doi: 10.1016/j.hpb.2020.08.014.
- Stackhouse KA, Storino A, Watkins AA, Gooding W, Callery MP, Kent TS, et al. Biliary palliation for unresectable pancreatic adenocarcinoma: surgical bypass or self-expanding metal stent? *HPB* 2020;22:563-9. doi: 10.1016/j.hpb.2019.08.014.
- Satoh T, Ishiwatari H, Kawaguchi S, Shirane N, Matsubayashi H, Kaneko J, et al. Comparing the 14-mm uncovered and 10-mm covered metal stents in patients with distal biliary obstruction caused by unresectable pancreatic cancer: a multicentre retrospective study. *Surg Endosc* 2022;36:736-744. doi: 10.1007/s00464-021-08342-z.
- Waldthaler A, Rutkowski W, Valente R, Arnelo U, Lohr JM. Palliative therapy in pancreatic cancer-interventional treatment with stents. *Transl Gastroenterol Hepatol* 2019;4:e7. doi: 10.21037/tgh.2019.01.05.
- Weintraub S, Grunspan M, Singer D. Hepaticocholecystostomy and cholecystojejunostomy for bile drainage. A palliative procedure. *Am J Surg* 1980;139:441-2. doi: 10.1016/0002-9610(80)90311-6.
- Shah O, Shah P, Zargar S. Hepaticocholecystoduodenostomy compared with Roux-en-y choledochojejunostomy for decompression of the biliary tract. *Ann Saudi Med* 2009;29:383-7. doi: 10.4103/0256-4947.55169.
- Garnjobst W. Hepatocholecystostomy complementary to palliative cholecystoenterostomy. *Arch Surg* 1982;117:1246-7. doi: 10.1001/archsurg.1982.01380330100026.
- Allan SM, Jackson DB. The gallbladder as a bilioenteric conduit. *Ann R Coll Surg Engl* 1990;72:22.
- Kogo H, Takasaki H, Sakata Y, Nakamura Y, Yoshida H. Cholecyst-jejunostomy for palliative surgery. *Int J Surg Case Rep* 2021;79:178-83. doi: 10.1016/j.ijscr.2021.01.020.
- Kudo Y, Sato N, Tamura T, Hirata K. Triple bypass for advanced pancreatic head cancer associated with biliary stricture, duodenal stenosis, and recurrent obstructive pancreatitis. *Surg Case Rep* 2016;2:79. doi: 10.1186/s40792-016-0210-1.
- Kohan G, Ocampo CG, Zandalazini HI, Klappenbach R, Yazzi F, Ditulio O, et al. Laparoscopic hepaticojejunostomy and gastrojejunostomy for palliative treatment of pancreatic head cancer in 48 patients. *Surg Endosc* 2015;29:1970-5. doi: 10.1007/s00464-014-3894-y.
- Dindo D, Demartines N, Clavien PA. Classification of surgical complications: a new proposal with evaluation in a cohort of 6336 patients and results of a survey. *Ann Surg* 2004;240:205-13. doi: 10.1097/01.sla.0000133083.54934.ae.
- Miura F, Okamoto K, Takada T, Strasberg SM, Asbun HJ, Pitt HA, et al. Tokyo Guidelines 2018: initial management of acute biliary infection and flowchart for acute cholangitis. *J Hepatobiliary Pancreat Sci* 2018;25:31-40. doi: 10.1002/jhbp.509.
- Agha RA, Sohrabi C, Mathew G, Franchi T, Kerwan A, O'Neill N, et al. The PROCESS 2020 Guideline: Updating Consensus Preferred Reporting Of Case Series in Surgery (PROCESS) Guidelines. *Int J Surg* 2020;84:231-5. doi: 10.1016/j.ijsu.2020.11.005.
- Gani J, Lewis K. Hepaticocholecystoenterostomy as an alternative to hepaticojejunostomy for biliary bypass. *Ann R Coll Surg Engl* 2012;94:472-5. doi: 10.1308/003588412X13171221592294.
- House MG, Cameron JL, Schulick RD, Campbell KA, Sauter PK, Coleman J, et al. Incidence and outcome of biliary strictures after pancreaticoduodenectomy. *Ann Surg* 2006;243:571-8. doi: 10.1097/01.sla.0000216285.07069.fc.
- Malgras B, Duron S, Gaujoux S, Dokmak S, Aussilhou B, Rebours V, et al. Early biliary complications following pancreaticoduodenectomy: prevalence and risk factors. *HPB* 2016;18:367-74. doi: 10.1016/j.hpb.2015.10.012.
- Cerwenka H. Bile duct cyst in adults: interventional treatment, resection, or transplantation? *World J Gastroenterol* 2013;19:5207-11. doi: 10.3748/wjg.v19.i32.5207.
- Soares KC, Arnaoutakis DJ, Kamel I, Rastegar N, Anders R, Maithe S, et al. Choledochal cysts: presentation, clinical differentiation, and management. *J Am Coll Surg* 2014;219:1167-80. doi: 10.1016/j.jamcollsurg.2014.04.023.
- Takeshita N, Ota T, Yamamoto M. Forty-year experience with flow-diversion surgery for patients with congenital choledochal cysts with pancreaticobiliary maljunction at a single institution. *Ann Surg* 2011;254:1050-3. doi: 10.1097/SLA.0b013e3182243550.