

Methylprednisolone acetate injection with casting versus casting alone for the treatment of De-Quervain's Tenosynovitis: a randomized controlled trial

Muhammad Akhtar, Syed Faraz Ul Hassan Shah Gillani, Rana Dilawaiz Nadeem, Muhammad Tasneem

Abstract

Objective: To compare the success of treatment between thumb spica cast with "methylprednisolone acetate injection" versus thumb spica cast alone for the treatment of de Quervain's disease as functional outcomes, complications and patient compliance.

Methods: A single blinded randomized controlled trial using a probability sampling technique was conducted from January 2014 to February 2017 at the Orthopaedic Unit II, King Edward Medical University / Mayo Hospital, Lahore. A total of 134 patients of both genders, between 30-60 years of age presented with wrist pain and diagnosed de Quervain's disease, were included in the study. Patients were randomly divided into two groups by the computer allocation method. Patients in Group-A received thumb spica cast with methylprednisolone acetate and xylocaine injection while patients in Group-B were treated with thumb spica cast alone. The outcome variable was frequency of successful treatment which was noted and compared among the groups.

Results: Amongst the total 134 patients, the age of the patients ranged from 30 to 60 years with a mean of 37.16 ± 5.15 years. Most of the patients were aged between 30-40 years (78.8%) followed by 41-50 years (21.2%). There were 38 (28.4%) male and 96 (71.6%) female patients in the study group with a male to female ratio of 1:2.5. In group-A mean VAS and Quick DASH score before treatment and after the treatment was statistically significant (p -value < 0.001). In group-B mean VAS and Quick DASH score before and after the treatment was also significant (p -value < 0.001) (Table-2).

Conclusion: The effectiveness of treatment was significantly higher in patients treated with thumb spica cast with methylprednisolone acetate injection as compared to thumb spica cast alone.

Keywords: "de Quervain's Disease", "Methylprednisolone Acetate", "Thumb Spica Cast" (JPMA 70: 1314; 2020). <https://doi.org/10.5455/JPMA.293180>

Introduction

De Quervain's disease is a common cause of wrist pain that leads to dysfunction of the affected hand. It typically occurs in adults between 31 to 50 years. This condition is around 0.5% in men and 1.3% in women as reported in the United Kingdom.^{1,2}

The tendons of abductor policis longus and extensor policis brevis muscles are involved. Impaired gliding within tendon sheath of these muscles can cause the disease. Most likely it is caused by the thick structures of ligaments that cover the tendons of the first dorsal compartment.^{3,4} The commonly used term for the condition is stenosing tenosynovitis but microscopically the appearance is

consistent with degeneration, supplemented by myeloid, fibro-cartilaginous and mucopolysaccharides deposition.⁵

A good history and clinical examination are considered enough for the diagnosis. The patient reports pain at the radial styloid process with radiation to the thumb and forearm. Clinical examination reveals local tenderness, with possible swelling in some cases along with crepitation on palpation. In typical cases, Finkelstein's test is done⁶ and the patient is asked to clench the fist, keeping thumb inside and similarly examiner deviates the hand towards the ulnar side. In de Quervain disease the affected side of the patient is painful.⁷

No consensus is made on the best protocols of immobilization. Conservative management including rest, massage, cold and heat applications with a splint in this condition has shown no effect. Non-surgical treatment

Department of Orthopedic Surgery, King Edward Medical University / Mayo Hospital, Lahore, Pakistan.

Correspondence: Syed Faraz Ul Hassan Shah Gillani.
e-mail: faraz.hassan20@hotmail.com

such as injection of locally administered corticosteroid, thumb spica cast, bracing and physical therapy has been most widely used. These methods of treatment are effective for De Quervain's tenosynovitis and have an advantage over surgical intervention.⁸⁻¹⁰

Surgery is performed to release the 1st dorsal compartment of wrist. Surgical treatment (dividing or excision of strip covering tendon) has been reported cure rate of 90%, but it is associated with the risk of a surgical complication, hospital stay, and high cost.¹¹

There is no clear-cut treatment for the de Quervain's tenosynovitis and no consensus exists between conservative, intra-lesional steroid and surgical management for better outcomes. We wanted to carry out this treatment to find the outcome of one method over the other so in future treatment with better outcome can be selected as a preferred method of choice.

Methodology

It was a single-blinded randomized controlled trial using a probability sampling random technique. This study was conducted from January 2014 to February 2017 at the Orthopaedic Unit II, King Edward Medical University / Mayo Hospital, Lahore. A total of 134 patients were randomly divided into two groups A and B by the computer allocation method with 67 participants in each group. Our inclusion criteria were all adult patients between age 30 to 60 years and above with either gender, pain present at the radial side of the wrist with thumb restricted extension or abduction. Tenderness over the styloid process in the first dorsal extensor compartment with positive Finkelstein test. Participants already taking treatment of minimum of six weeks (range 4-6 weeks) with oral and local NSAIDs and who did not respond to treatment and/or not satisfied with treatment confirmed on history and examination were also included. Exclusion criteria were all patients with acute trauma and neoplasm involving wrist joint, previous treatment in the form of steroid injection, surgery in the past six months for distal radius and presence of absolute contraindication for steroid confirmed on history, examination and conventional radiographs.

Study participants were recruited after the approval from the Ethical research committee from KEMU Registered participants who presented in the outpatients and fulfilled the above criteria were counseled and explained the details of the study. Informed written consent was

obtained from all the patients. Data was recorded on a pre-tested questionnaire. Group A: Thumb Spica cast with Methylprednisolone acetate injection. Group-B: Thumb spica cast alone was given. The routine hospital purchased medicine from hospital supply were used. Patients' pain at presentation was measured by applying a visual analogue scale (VAS) from 0 (no pain) to 10 (severe pain) and function outcome with Quick disabilities_of_arm_ shoulder_hand_ (DASH) score before and after the treatment till the last follow up. Patients of both the groups received treatment as per group protocol. After two weeks of injection with thumb cast and thumb cast alone, each patient was examined clinically to find early clinical response after removal of thumb cast at two weeks intervals and followed fortnightly for six weeks. Successful treatment in two groups was documented by a reduction in the severity of pain on VAS and the absence of tenderness on the radial side of the wrist and negative Finkelstein test on every follow up till the last follow up. These were the primary outcomes that were measured in this study. All patients from both the groups in whom the primary outcome was not achieved, were probed about the presence of a continuous pain, pigmentation of the skin, tenderness test positive as secondary outcome. Failure was defined with the absence of any of the three findings or pain score improvement of less than 90%.

The Quick DASH is an 11-items questionnaire. It was used to assess the outcomes of function and patient's symptoms having disorders of the upper limb.¹² Participants were inquired to grade the capability to carry out eight routine activities of physical nature. Three-items, were related to the symptoms of a patient. According to literature the minimum change of 27.7 points in the Quick DASH score is statistically significant at the 95% confidence interval. Recently it is recommended that Minimum clinically important difference (MCID) with a Quick DASH score of 15, can be accepted for clinical significance, when each item is scored from scale one to five.¹³ The net raw score standardized to global score ranging from 0 to 100.

The data was entered into the software SPSS 21.0 for analysis, Numerical variables i-e age, pain score at presentation have been presented by mean \pm SD. Categorical variables i-e gender and successful treatment was presented as frequency and percentage. The paired t-test was applied to compare the effects of successful treatment between the two groups taking $p < 0.05$ as significant.

Injection Technique: For group A, one ml (10mg) of triamcinolone acetonide and one ml of 1% lidocaine hydrochloride mixed in 5 ml syringe with 24- or 26-gauge needle was administered and thumb spica cast was applied. The area of tenderness was confirmed in the first extensor compartment of the wrist, directing proximally towards styloid process of radius and parallel to the abductor policis longus and extensor policis brevis tendon. Presumably no medicine, even a pain killer was allowed, with no absolute contraindication.¹⁰ In Group-B patients received casting alone.

Results

The age of the patients ranged from 30 years to 60 years with a mean of 40.73±9.20 years in group-A and 41.44±8.5 in group-B. Most of the patients were aged between 30-40 years (78.8%) followed by 41-50 years (21.2%). The demographic details are given in Table-1. There were majority 41 (30.6%) who didn't receive a formal education, while 32 (23.8%) had primary education, 24 (17.9%) middle, 25 (18.6%) had intermediate, 8 (5.9%) graduate and only 4 (2.9%) had master's degree. In group-A mean VAS and Quick DASH score before treatment and after the treatment was statistically significant (p-value <0.001) (Table-2). In group-B mean VAS and Quick DASH score before and after the treatment was also significant (p-value <0.001) (Table-2). The secondary treatment outcomes were measured and in group-A and only 08

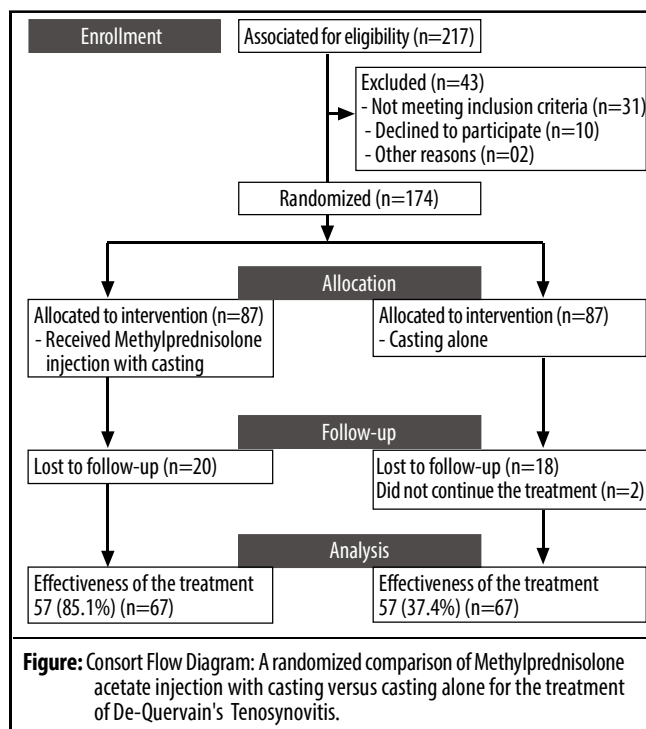
Table-1: Demographic Characteristics of Age, Marital Status, Gender, Financial Status, Income Group and Cigarette Smoker.

Variables	Injection with Thumb Cast (n=67) n (%)	Thumb Cast Alone (n=67) n (%)	Total (n=134) n (%)
Gender			
Male	20 (29.9)	18 (26.1)	38(28.4)
Female	47 (70.1)	49 (73.1)	96 (71.6)
Marital Status			
Married	61 (91)	58 (86.6)	119 (88.8)
Unmarried	06 (9)	09 (13.4)	15 (11.2)
Mean Age±SD (years)	(40.73±9.20)	(41.44±8.5)	
Financial Status			
Self-earning	28 (41.8)	31 (46.2)	59(44.02)
Dependent	31 (36.3)	27 (40.3)	58 (43.28)
Un-employed	8 (11.9)	9 (13.4)	17 (12.7)
Income Group			
Low	16 (23.9)	19 (28.3)	35 (16.14)
Middle	51 (76.1)	48 (71.7)	99 (51.36)
Cigarette Smoker			
Yes	26 (38.8)	15 (22.4)	41 (30.6)
No	41 (61.2%)	52 (77.6)	93 (69.4)

Table-2: Paired t-test of both Group A (Methylprednisolone acetate injection with thumb cast) & Group B (thumb cast alone) Visual Analogue Score & Quick DASH Score Before and After the Treatment.

Variables	n	Mean±SD	t-test	p-value
Group A			18.39	<0.001
Quick DASH before Treatment	67	46.75±14.84		
Quick DASH Score after Treatment	67	11.7±9.5		
Group B			8.137	<0.001
Quick DASH before Treatment	67	42.01±13.8		
Quick DASH Score after Treatment	67	28.25±18.71		
Group A			19.762	<0.001
VAS before Treatment	67	4.55±1.71		
VAS Score after Treatment	67	0.791±1.17		
Group B			8.906	<0.001
VAS before Treatment	67	4.45±1.01		
VAS Score after Treatment	67	2.53±1.67		

SD: Standard Deviation.



(11.9%) patients had skin pigmentation and 59 (88.1%) did not have skin pigmentation. In group-A, 57 (85.1%) had primary outcome while 10 (14.9%) were asked about secondary outcome. Out of 10 patients 07 (70%) did not have continuous pain in the wrist and 03 (30%) had continuous pain. In group-B, out of 42 patients who did not respond to treatment, majority 27 (64.3%) had continuous pain and most 15 (35.7%) did not have continuous wrist pain.

Discussion

De Quervain's tenosynovitis presents with pain at the radial styloid which is disabling and requires treatment. Non-surgical treatment is preferred over surgical management. Non-operative treatment consists of rest, physiotherapy, thumb casting, topical and intralesional corticosteroid.¹⁴ The corticosteroid treatment is given due to its anti-inflammatory effect, however, the exact mechanism of action is not yet fully elucidated.¹⁵

An earlier study from Pakistan evaluated the outcome of methylprednisolone treatment in 80 patients of de Quervain¹⁶ where the mean age of patients was 29.32 ± 6.09 years with a male to female ratio of 1:2.3. The mean baseline VAS score for pain was 6.2 ± 1.7 . They observed successful resolution of disease in 80% of patients.¹⁶ Another study conducted on a smaller sample size of 50 patients with a male to female ratio of 1:5.25 achieved a little higher, i.e. 84% success rate.¹⁷ The frequency of successful treatment with steroid injection in their series was 84%.¹⁷ A study from Thailand has reported 67% successful treatment rate with injection alone,¹⁵ while we had 85.1% successful treatment with combined effects of two treatments and the age of the patients ranged from 30 to 60 years with a mean of 40.73 ± 9.20 years in group-A. Thus our results of the combined treatment are a shade better, 85% in comparison to 83% reported in a recently published systemic review and meta-analysis¹⁸ The primary outcome was taken reduction in severity of pain on VAS and tenderness on the radial side of wrist and negative Finkelstein test with minimally important clinical difference of Quick DASH score was taken 15 score, The frequency of successful treatment was significantly higher in patients treated with thumb spica cast with methylprednisolone acetate injection (85.1% vs. 37.4%; $p < 0.001$) as compared to thumb spica cast alone. Hadianfard et al. (2013) studied 15 patients of de Quervain tenosynovitis with mean baseline pain score of 6.67 ± 1.75 . The mean age of the patients was 39.47 ± 12.10 years with male to female ratio of 1:2.7. They reported successful treatment in 87% of patients with local steroid injection.¹⁹ Peters-Veluthamaningal et al. (2009) studied Nine patients with de Quervain's disease undergoing triamcinolone injection with a mean age of 51.2 ± 20.2 years and male to female ratio of 1:3. The mean baseline pain score in their series was 7 ± 4.1 . They observed the frequency of successful treatment to be 78% with steroid injection alone.²⁰

It may be worth reemphasizing that our rate of 85 % success stays in good agreement with another randomized controlled trial conducted in Iran on 73 participants with a "mean age" of 32.83 ± 8.9 years and male to female ratio of 1:6.4.²¹ Rowland et al. (2015)²² in his meta-analysis assessed the resolution of symptoms [RR 2.59, 95% CI:1.25 to 5.37, $p=0.05$] and pain reduction on VAS after injection alone [mean difference -2.51, 95% CI: -3.11 to -1.90, $p=0.0003$].

The present study was first of its kind from Pakistan, which adds valuable information to the limited evidence available on the efficacy of thumb spica cast with methylprednisolone acetate injection as compared to conventional treatment of thumb spica cast alone. In the present study, the percentage of successful treatment was noticeably high amongst patients treated with thumb spica cast with methylprednisolone acetate injection (85.1% vs. 37.5%; $p < 0.001$) as compared to the thumb spica cast alone regardless of patient's age, gender and baseline pain severity. The results of the present study thus advocate the use of this combination therapy in future practice. Our study has revealed good results of combined effects of treatment with methylprednisolone injection plus casting.

In our study, we did not consider important limitation that was adverse effect other than corticosteroid treatment which are also equally important. We observed stiffness of the wrist in both patients and they required physiotherapy for rehabilitation in both groups and should be considered in future studies before adopting this treatment in routine practice.

Conclusion

We concluded that patients treated with methylprednisolone injection with casting showed the good results in pain relief, and negative Finkle-stein test and minimum to no complications. The patients also showed good compliance with corticosteroid injection with casting. The casting alone also showed reasonably good outcomes, but the success rate is lower in comparison to injection with casting.

Disclaimer: This study was part of the thesis for Master of Surgery in Orthopedic Surgery (MS Orthopedic Surgery).

Conflict of Interest: None.

Funding Sources: None.

References

1. Wright PE II. Carpal tunnel, ulnar tunnel, and stenosing tenosynovitis. In: Campbell WC, Canale ST, Beatty JH, eds. *Campbell's Operative Orthopaedics*. 11th ed. Philadelphia, PA: Mosby/Elsevier. 2008: 4230-99.
2. Walker-Bone K, Palmer KT, Reading I, Coggon D, Cooper C. Prevalence and impact of musculoskeletal disorders of the upper limb in the general population. *Arthritis Rheum*. 2004; 51:642-51.
3. Schned ES. De Quervain tenosynovitis in pregnant and postpartum women. *Obstet Gynecol*. 1986; 68: 411-4.
4. Batteson R, Hammond A, Burke F. The de Quervain's screening tool: validity and reliability of a measure to support clinical diagnosis and management. *Musculoskeletal Care*. 2008; 6: 160-80.
5. Clarke MT, Lyall HA, Grant JW, Matthewson MH. The histopathology of de Quervain's disease. *J Hand Surg*. 1998; 23:732-4.
6. Palmer K, Walker-Bone K, Linaker C, Reading I, Kellingray S, Coggon D, et al. The Southampton examination schedule for the diagnosis of musculoskeletal disorders of the upper limb. *Ann Rheum Dis*. 2000; 59:5-11.
7. Rettig AC. Wrist and hand overuse syndromes. *Clin Sports Med* 2001; 20:591-611.
8. Sluiter JK, Rest KM, Frings-Dresen MH. Criteria document for evaluating the work-relatedness of upper-extremity musculoskeletal disorders. *Scand J Work Environ Health*. 2001; 27:1-102.
9. Suresh SS, Zaki H, Ali A. Does Radial Styloid Abnormality in de Quervain's Disease Affect the Outcome of Management? *Hand*. 2010;5:374-7.
10. Ta KT, Eidelman D, Thomson JG. Patient satisfaction and outcomes of surgery for de Quervain's tenosynovitis. *J Hand Surg*. 1999; 24:1071-7.
11. Sawaizumi T, Nann M, Ito H. De Quervain's disease: efficacy of intra sheath triamcinolone Injection. *Int Orthop*. 2007; 31:265-8.
12. Goldfarb C, Ricci W, Tull F, Ray D, Borrelli J. Functional outcome after fracture of both bones of the forearm. *J Bone Joint Surg*. 2005. 87:374-79.
13. Sorensen AA, Howard D, Tan WH, Ketchersid J, Calfee RP. Minimal Clinically Important Differences of three Patient Rated Outcomes Instruments. *J Hand Surg*. 2013; 38:641-49.
14. Ilyas AM, Ast M, Schaffer AA. De quervain tenosynovitis of the wrist. *J Am Acad Orthop Surg*. 2007;15:757-64.
15. Kitti JI, Sukit S, Kitiwan V, Surut JI. Treatment of de Quervain disease with triamcinolone injection with or without nimesulide. *J Bone Joint Surg Am*. 2004;86: 2700-06.
16. Akram M, Shahzad ML, Farooqi FM, Irshad M, Shah RK, Awais SM. Results of injection corticosteroids in treatment of de Quervain's tenosynovitis. *J Pak Med Assoc* 2014; 64:30-3.
17. Khan MI, Saqib M, Hakim A. Outcome of methylprednisolone acetate injection for the treatment of de Quervain's tenosynovitis. *Pak J Surg* 2014; 30:256-8.
18. Hadianfard M, Ashraf A, Fakheri M, Nasiri A. Efficacy of acupuncture versus local methylprednisolone acetate injection in De Quervain's tenosynovitis: a randomized controlled trial. *J Acupunct Meridian Stud* 2014; 7:115-21.
19. Cavaleri R, Schabrun SM, Maxine Te, Lucy S. Chipchase. Hand therapy versus corticosteroid injections in the treatment of de Quervain's disease: A systematic review and meta-analysis. *J Hand Therapy*. 2016; 3-11. DOI: 10.1016/j.jht.2015.10.004
20. Peters-Veluthamaningal C, Winters JC, Groenier KH, Meyboom-DeJong B. Randomised controlled trial of local corticosteroid injections for de Quervain's tenosynovitis in general practice. *BMC Musculoskelet Disord* 2009; 10:131.
21. Mehdinasab SA, Alemohammad SA. Methylprednisolone acetate injection plus casting versus casting alone for the treatment of de Quervain's tenosynovitis. *Arch Iran Med*. 2010; 13:270-74.
22. Rowland P, Phelan1 N, Gardine S1, Linton KN, Rose Galvin. The Effectiveness of Corticosteroid Injection for De Quervain's Stenosing Tenosynovitis (DQST): A Systematic Review and Meta-Analysis. *Open Orthop J*. 2015; 9:437-44.