

Clinical outcome of patients with isolated tibial shaft fractures treated with S.I.G.N interlock nails in terms of surgical site infection and radiological bone healing on follow up

Muhammad Zain-ur-Rehman, Rana Dawood Ahmad Khan, Usama Bin Saeed, Ajmal Yasin

Abstract

Objective: To determine the clinical outcome of patients with isolated tibial shaft fractures treated with Surgical Implant Generation Network interlock nails.

Methods: The observational study was conducted from January 2010 to October 2014 at Allied Hospital, Faisalabad, Pakistan, and comprised in-patient charts. The Surgical Implant Generation Network Fracture Care Online Database was also screened for patients' data to be included in the study. The dependent variables were surgical-site infection and radiographic callus formation (bone healing). Data was analysed using SPSS 17.

Results: Out of the 80 patients in the study, 56(70%) were male and 24(30%) were female; the male-to-female ratio being 2.3:1. Overall, 64(80%) patients showed radiographic union and 3(3.75%) patients had surgical-site infection on follow-up after 12 weeks.

Conclusions: The treatment of isolated tibial shaft fractures with Surgical Implant Generation Network interlock nails showed good results in terms of infection and radiographic bone healing.

Keywords: Tibial shaft fractures, SIGN nails, Surgical site infection. (JPMA 65: S-175 (Suppl. 3); 2015)

Introduction

Tibial shaft fractures are among the most common fractures and are mostly caused by high-energy trauma. Surgical planning and documentation of these fractures have been guided through the Arbeitsgemeinschaft für Osteosynthesefragen (AO)-Orthopaedic Trauma Association Classification. Several treatment options are available for tibial shaft fractures depending on fracture pattern, degree of comminution, fracture location, either open or close, and soft tissue involvement. With the advent of intramedullary nailing, there is better angular and rotational control of fractures fragments, especially for comminuted and oblique fractures.¹

Küntscher developed his V-shaped and cloverleaf nails in the 1930s, but it was not until nearly 50 years later that rigid intramedullary nailing became a widely accepted treatment for tibial shaft fractures, with 98% good results in closed fractures and in 97.5% of open fractures treated with unreamed straight Küntscher nails. Herzog modified the straight Küntscher nail to accommodate the eccentric proximal portal. Some authors proposed reaming of the medullary canal to improve the fit of the nail and to increase its rotational control and strength. Slatis and

Rokkanen found that 50% of nailed fractures in their series required casting to control rotation. In the 1970s, Grosse and Kempf and Klemmand Schellmann developed nails with interlocking screws, which expanded the indications for nailing to include more proximal, distal, and unstable fractures. Early reports of interlocking nails inserted with reaming showed good results (97% union rate; 2.2% complication rate), especially in closed fractures. Ekeland et al. also reported good results with interlocking nails, but cautioned against their use in the dynamic or simple unlocked mode, noting that most complications in their series occurred with dynamic locked nails. They also did not recommend routine dynamisation.^{2,3}

In developing countries, such as Pakistan, patients from poverty are unable to afford the cost of intramedullary nails. Surgical Implant Generation Network (SIGN), a non-profit organisation from America, has been doing charitable work in Pakistan in collaboration with some tertiary hospitals since 2002. They have been providing solid intramedullary fixation of femoral and tibial fractures for patients who could not afford commercial cannulated interlocking nails. However, the nails were initially designed for tibial fractures and were eventually considered for femoral shaft fractures as an extended use. Ikem et al. did a prospective descriptive analysis of 40 patients with diaphyseal fractures of the tibia, humerus, and mainly the femur (65%) treated with SIGN

.....
Department of Orthopedic Surgery, Allied Hospital, Punjab Medical College, Faisalabad.

Correspondence: Muhammad Zain-ur-Rehman. Email: zainpmc@hotmail.com

intramedullary nails (Figure-1). All cases were done without intra-operative imaging and results showed all cases had 100% fracture union at a mean time of 2.93 months.⁴

The current literature regarding SIGN intramedullary nails in tibial shaft fractures does not offer any head on clinical outcomes in this regard. The paucity of literature in this regard stressed the need for the current study which was planned to determine the clinical outcome of patients with isolated tibial shaft fractures treated with SIGN interlock nails.

Materials and Methods

The observational study was conducted from January 2010 to October 2014 at Allied Hospital, Faisalabad, Pakistan, and comprised in-patient charts. The SIGN Fracture Care Online Database was also screened for patients to be included in the study. The patients were selected with the following inclusion criteria: isolated diaphyseal tibial shaft fracture; Gustilo classification closed or open type I; fractures fixed with only SIGN interlock nails; fractures fixed in ≤ 30 days from time of injury; and those who had a minimum follow-up of ≥ 12 weeks.

Gustilo open fracture types II and III, those with other associated long bone fractures, conversion intramedullary nailing from external fixator, and pathological fractures were excluded.

The dependent variables measured in the study were the surgical site infection (SSI) and radiographic union. SSI was defined as the presence of pus or discharge from the incision sites affecting either the superficial or deep tissues on follow-up. The majority of SSIs become apparent within 30 days of an operative procedure and most often between the 5th and 10th postoperative days. However, where a prosthetic implant is used, SSIs affecting the deeper tissues may occur several months after the operation.⁵

Radiographic union was defined as the presence of bridging callus formation in four cortices on anterior and lateral radiographs. The presence of callus at the fracture site was described as: union = callus in four cortices and non-union - no callus formation.⁶

Data was analysed using SPSS 17. Quantitative data like age was presented in the form of mean \pm standard deviation (SD) and qualitative data like gender was presented as frequency and percentage.

Results

There were 103 cases of tibial shaft fractures, but only




Figure-1: The Surgical Implant Generation Network (SIGN) intramedullary nail is a straight solid stainless steel nail.⁴

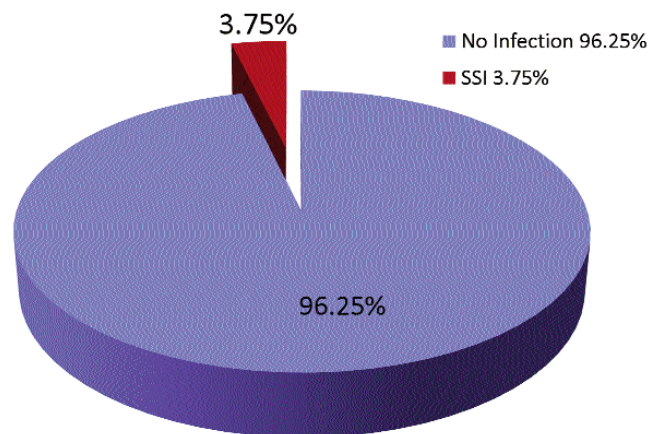


Figure-2: Surgical site infection (SSI).

Table-1: Gender Distribution.

Sex	Frequency	Percentage
Male	56	70%
Female	24	30%
Male-to-female ratio: 2.3:1		

80(82%) met the inclusion criteria. Of them, 56(70%) were male and 24 (30%) were female patients; the male-to-female ratio being 2.3:1 (Table-1).

There were 4(5%) patients in age group 10-20 years, 28(35%) in 21-30 years, 24(30%) in 31-40 years, 14(17.5%) in 41-50 years, 6(7.5%) in 51-60 years and 4(5%) in age group above 60 years. The overall mean

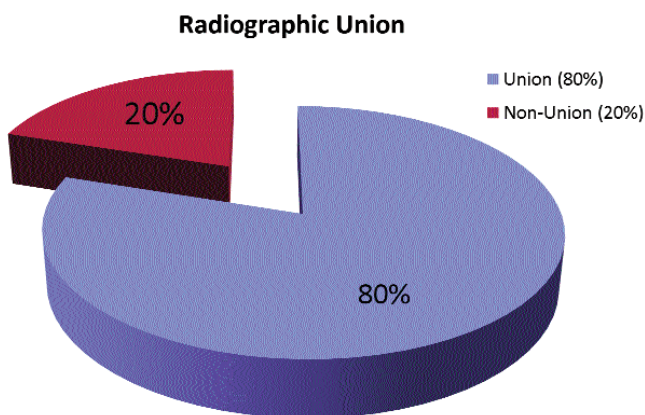


Figure-3: Radiographic Union rates.

Table-2: Age Distribution.

Age (years)	Frequency	Percentage
10-20	4	5%
21-30	28	35%
31-40	24	30%
41-50	14	17.5%
51-60	6	7.5%
>60	4	5%

age was 35.86 ± 10.42 years (Table-2).

In terms of SSIs, only 3(3.75%) patients had them and were managed with antibiotics (Figure-2).

There was significant radiographic union of patients on follow-up after 12 weeks, with 64(80%) patients showing union and 16(20%) showing no callus formation on radiograph (Figure-3).

Discussion

SIGN interlock nails of diaphyseal fractures of the tibia have proven to be a comparable implant to conventional cannulated interlocking nails. They provide angular and rotational stability despite fracture comminution, and result in high union rates and low infection rates.⁷ Unfortunately, in a third world country such as Pakistan, not everyone has the finances to procure funds for the ideal implant. The introduction of the SIGN nail as an alternative free-of-charge implant has been very appealing to the surgeons dealing with the poor.

The study population for this study included patients treated with SIGN nails. The mean time of surgery was almost 1 week post-injury. The main reasons for the

delay in the surgery were over-burden, lack of blood donors, and lack of associated facilities.

Surgeons were unable to identify the time for radiographic union since the subjects did not follow a uniform timetable of follow-up. Some patients were lost for several weeks and then showed up at the out-patient department (OPD) already with radiographic union. However, there was better record-keeping due to an online database available.

Patients were diagnosed using the criteria of the Centers for Disease Control and Prevention (CDC) guidelines for SSIs. The study population also consisted of patients with open type 1 fractures which had adequate debridement. Infection rates of open type 1 fractures were reported to be 0-2% in literature.⁸ Surprisingly, all the subjects with infection were with closed fractures in our study.

All patients required opening the fracture site since the SIGN system does not use intra-operative imaging to insert a guide-wire.⁹ Management of the infections comprised operative debridement, suppression with antibiotics and retention of hardware until fracture union. These results were comparable to the gold standard treatment of tibial shaft fractures (cannulated interlock intramedullary nails), where the incidence of infection in closed and type 1 open fractures was around 2%.¹⁰

Poor patient follow-up and lack of uniformity in follow-up periods was a limitation of the study. Besides, lack of randomisation and blinding and the fact that surgeries were performed by different surgeons also limited the scope of the study.

Conclusions

The treatment of isolated tibial shaft fractures with SIGN interlock nails showed good results in terms of infection and radiographic bone healing.

References

1. Nork SE. Fractures of the shaft of the femur. In: Bucholz RW, Heckman JD, Court-Brown C, eds. Rockwood & Green's Fractures in Adults. Vol 2. 6th ed. Philadelphia, PA: Lippincott Williams & Wilkins; 2006. pp. 1849-50.
2. Bong MR, Koval KJ, Egol KA. The history of intramedullary nailing. Bull NYU Hosp Jt Dis 2006; 64: 94-97.
3. Whittle AP. Fractures of the lower extremity. In: Canale ST, Beaty JH, eds. Campbell's Operative Orthopaedics. Vol 3. 11th ed. Philadelphia, PA: Mosby; 2007; pp 3085-3236.
4. Feibel RJ, Zirkle LG. Use of interlocking intramedullary tibial nails in developing countries. Tech Orthop 2009; 24: 233-246.
5. Vallier HA, Cureton BA, Patterson BM. Randomized, prospective comparison of plate versus intramedullary nail fixation for distal

- tibia shaft fractures. *J Orthop Trauma* 2011; 25: 736-741.
6. Lefavre KA, Guy P, Chan H, Blachut PA. Long-term follow-up of tibial shaft fractures treated with intramedullary nailing. *J Orthop Trauma* 2008; 22: 525-9.
 7. Berkes M, Obremsky WT, Scannell B, Ellington JK, Hymes RA, Bosse M, et al. Maintenance of hardware after early post-operative infection following fracture internal fixation. *J Bone Joint Surg Am* 2010; 92: 823-8.
 8. Young S, Lie SA, Hallan G, Zirkle LG, Engesaeter LB, Havelin LI. Risk factors for infection after 46,113 intramedullary nail operations in low- and middle-income countries. *World J Surg* 2013; 37: 349-55.
 9. Ikem IC, Ogunlusi JD, Ine HR. Achieving interlocking nails without using an image intensifier. *Int Orthop* 2007; 31: 487-490.
 10. Tanner J, Woodings D, Moncaster K. Preoperative hair removal to reduce surgical site infection. *Cochrane Database Syst Rev* 2006; 3: CD004122.
-