

Survival benefit of surgery in recurrent glioblastoma multiforme

Usama Khalid Choudry, Saad Akhtar Khan, Muhammad Shahzad Shamim

Abstract

There is an ongoing debate regarding role of surgery for recurrent glioblastoma multiforme (GBM). Older literature hinted at only modest survival benefits with surgery and a high rate of morbidity. However, more recent literature suggests better survival that may be attributed to better surgical techniques and better options in adjuvant treatment. Herein the authors review recent literature with regards to the possible role of surgery in recurrent GBM and also look into the key factors impacting second surgery.

Keywords: Recurrence, brain tumour, Glioblastoma multiforme.

Introduction

Glioblastoma multiforme (GBM) is the commonest and one of the most aggressive primary brain tumour, and despite all the advances in diagnosis and management continues to be uniformly fatal.¹ The presently accepted protocol requires aggressive surgery, followed by chemotherapy and radiation therapy for best outcomes. However, the tumour invariably recurs, raising the question for second line management, including reoperation. Most GBMs recur locally in the resection cavity, and are therefore potential candidates both for surgery as well as adjuvant chemo-radiation therapy.² Although many studies have suggested improved outcomes with re-operations in case of recurrence, there are also reports of substantial morbidity in re-operations.

Review of Evidence

A systematic review published in 2014 provides level II

.....
Aga Khan University Hospital, Karachi, Pakistan.

Correspondence: Muhammad Shahzad Shamim.

Email: shahzad.shamim@aku.edu

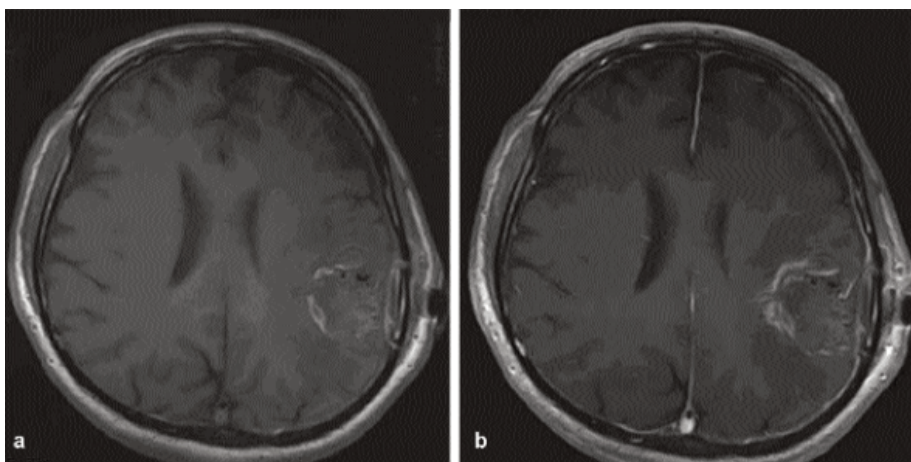


Figure-1: (a,b) Post-operative MRI T1W pre and post-contrast axial images, showing gross total resection of GBM.

evidence that reoperation is beneficial in symptomatic patients with locally recurrent or progressive high-grade gliomas.³ The study also recommended the use of preoperative factors like location of recurrence in eloquent brain regions, Karnofsky Performance Status (KPS) and tumour volume; to be considered when evaluating a patient for reoperation.³ The role of extent of resection (EOR) has also remained a topic of debate and the various options vary from debulking (maximal safe resection), border resection (resection margins at the tumour edge), gross total resection and extended resection (resection margins 1-2 cm away from tumour edges). Some authors have also predicted survival outcomes based on the pattern of recurrence such as local recurrence (LR) at the site of primary resection cavity, or distant recurrence (DR) at a distant site. Bonis et al., reported statistically significant improvements in rates of tumour progression after border resection ($p < 0.05$) and reported survival outcomes for 60 patients with local recurrence to be 16-months as compared to 35-months for 15 patients with distant recurrence ($p = 0.06$).⁴ Oppenlander et al., reported EOR thresholds for recurrent GBM concluding that a significant improvement in overall survival (OS) was achieved with 80% EOR. The median progression free survival (PFS) following reoperation was estimated at 5.2 months, while median OS was 1.9 years for same

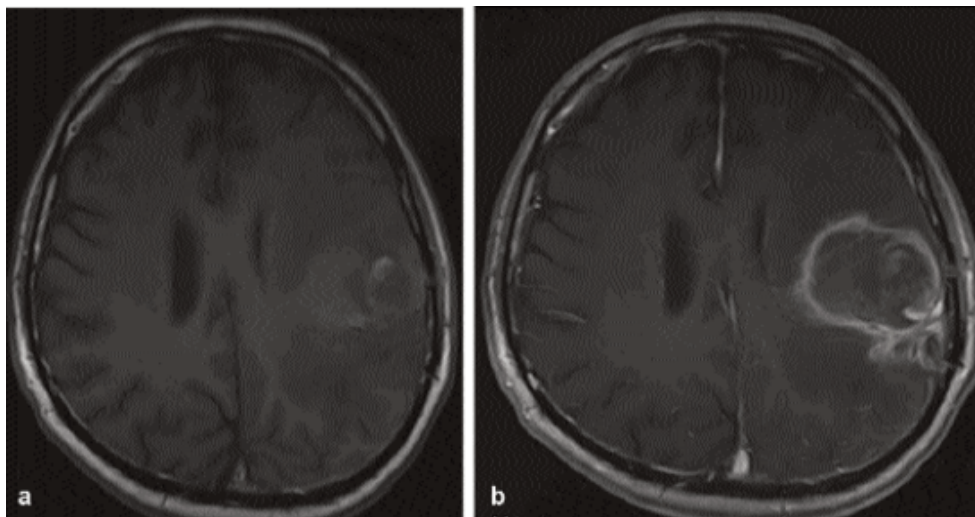


Figure-2: (a,b) 6-month follow-up MRI T1W pre and post-contrast axial images, showing recurrence of disease at the site of surgery.

population. They also reported an extremely promising 2.5 years OS in a subset with EOR $\geq 97\%$ for recurrent GBM, with age, KPS, and EOR as predictors of survival ($P < 0.05$).⁵

De Bonis et al., in another paper also compared outcomes for 76 consecutive patients with recurrent glioblastoma. Treatment was categorized into surgical resection alone (17 patients), chemotherapy alone (24 patients), combined approach (16 patients) and no intervention (19 patients). They concluded that patients with a KPS ≥ 70 had a considerably prolonged survival (9 months vs. 5 months, $p < 0.05$) and OS was 6 months for patients in surgical resection only, 5 months for patients that received no intervention, 8 months for patients treated with chemotherapy alone, while 14 months for patients treated with surgery and adjuvant therapy combined ($p < 0.05$). Their surgical morbidity however, was substantial (16 out of 33 patients, 48%).⁶ Skeie et al., reported their comparison between gamma knife surgery (GKS) and surgery for recurrent GBM. The study had 32 patients who underwent GKS alone, 26 underwent surgery alone, and 19 received both treatment modalities. They reported median time from second intervention to tumour progression was significantly longer after GKS than after surgery ($P < 0.05$). Median survival after radiosurgery was 12 months for the 51 patients receiving GKS (with or without surgery) in comparison to 6 months for surgery only (hazards ratio 2.4). They also reported fewer complications after GKS (9.8% vs. 25.2%).⁷ Brandes et al., in 2016, analyzed OS in 270 patients who received surgery for recurrent GBM. Of

these patients, 128 had complete resection and 142 had partial resection. Median survival from surgery was 11.4 months and age < 70 years ($p < 0.05$), MGMT methylation status ($p < 0.05$), and EOR ($p < 0.05$) were associated with better survival.⁸

Sughrue et al., studied the clinical outcome with EOR for recurrent GBM in a cohort of 105 patients. Post-surgical analysis was based on gadolinium contrast-enhanced MRI that was available in 59 patients who were re-operated. In these patients,

complete resection of contrast-enhancing tumour (N=40) versus residual detection of contrast enhancement (N=19) was correlated with improved survival and quality of life (QoL). Incomplete tumour resection was correlated with poorer survival compared with patients who did not undergo surgery. No significant difference in QoL was found in these two groups. They concluded that reoperation improves outcomes if complete resection of contrast-enhancing tumour is attained.⁹ The DIRECTOR trial reported median PFS of 7.8 months, 6 months, and 4.8 months following the second, third, and more craniotomies for glioblastomas, respectively. The study also concluded that previous PFS is not a predictor of PFS the next surgery will provide the patient.¹⁰ Surgery, re-irradiation and systemic chemotherapy provided short-term disease control and modest survival benefit.

Conclusion

The authors conclude that there is a definite role of surgery in the management of recurrent GBM. The factors to be considered before opting for reoperation are (i) age of the patient, (ii) KPS score, (iii) eloquent vs. non-eloquent location of recurrence, (iv) MGMT methylation status. Operative factors associated with better survival include extent of resection $> 80\%$ (EOR) and distant site of recurrence. Repeat surgery can improve both OS and PFS.

References

1. Khan I, Waqas M, Shamim MS. Prognostic significance of IDH 1 mutation in patients with glioblastoma multiforme. *J Pak Med Assoc* 2017; 67: 816-7.

2. Norden AD, Young GS, Setayesh K, Muzikansky A, Klufas R, Ross GL, et al. Bevacizumab for recurrent malignant gliomas; efficacy, toxicity, and patterns of recurrence. *Neurology*. 2008; 70: 779-87.
 3. Indian J Endocr Metab De Bonis P, Anile C, Pompucci A, Fiorentino A, Balducci M, Chiesa S, et al. The influence of surgery on recurrence pattern of glioblastoma. *Clin Neurol Neurosurg*. 2013; 115: 37-43.
 4. Oppenlander ME, Wolf AB, Snyder LA, Bina R, Wilson JR, Coons SW, et al. An extent of resection threshold for recurrent glioblastoma and its risk for neurological morbidity: clinical article. *J Neurosurg*. 2014; 120: 846-53.
 5. De Bonis P, Fiorentino A, Anile C, Balducci M, Pompucci A, Chiesa S, et al. The impact of repeated surgery and adjuvant therapy on survival for patients with recurrent glioblastoma. *Clin Neurol Neurosurg*. 2013; 115: 883-6.
 6. Skeie BS, Enger PO, Brogger J, Ganz JC, Thorsen F, Heggdal JI, et al. Gamma knife surgery versus reoperation for recurrent glioblastoma multiforme. *World Neurosurgery*. 2012; 78: 658-69.
 7. Brandes AA, Bartolotti M, Tosoni A, Poggi R, Bartolini S, Paccapelo A, et al. Patient outcomes following second surgery for recurrent glioblastoma. *Future Oncol*. 2016; 12: 1039-44.
 8. Sughrue ME, Sheean T, Bonney PA, Maurer AJ, Teo C. Aggressive repeat surgery for focally recurrent primary glioblastoma: outcomes and theoretical framework. *Neurosurg focus*. 2015; 38: E11.
 9. Suchorska B, Weller M, Tabatabai G, Senft C, Hau P, Sabel MC, et al. Complete resection of contrast-enhancing tumor volume is associated with improved survival in recurrent glioblastoma - results from the DIRECTOR trial. *Neuro-oncol*. 2016; 18: 549-56.
-