

Multidisciplinary approach to the prenatal diagnosis and Post natal management of a large suprasellar arachnoid cyst: A case report

Omar Irfan,¹ Heera Nand Rathore,² Sarfraz Karim,³ Shabina Ariff,⁴ Aneela Darbar⁵

Abstract

Arachnoid cysts are intra-arachnoid sacs filled with cerebrospinal fluid representing a rare occurrence in neonates. We report the case of a suprasellar arachnoid cyst diagnosed prenatally at 21 weeks gestation on routine obstetric ultrasound. A cystic lesion was picked up incidentally at routine antenatal scan. The cyst was noted to be increasing in size over a series of radiological scans. The cyst was diagnosed as a suprasellar arachnoid cyst compressing the third ventricle and bilateral lateral ventricles. A left pterional craniotomy for cystocisternostomy of large suprasellar cyst was performed initially. Within a month the cyst recurred with clinical and radiological evidence. An Endoscopic Third Ventriculostomy (ETV) with fenestration was performed. The patient was shifted to the NICU and discharged after 3 days in a stable condition. Patient was followed after 1 week and reassured and advised for one year follow-up.

Keywords: Arachnoid cyst, suprasellar, cystocisternostomy.

Introduction

Arachnoid cysts are intra-arachnoid sacs containing cerebrospinal fluid and represent about 1% of all intracranial masses in neonates. Suprasellar arachnoid cysts comprise approximately 5 - 12.5% of all intracranial arachnoid cysts.¹ A suprasellar arachnoid cyst can be challenging to diagnose, as it is usually asymptomatic unlike many other arachnoid cysts and most often present with endocrine abnormalities due to its close proximity to the pituitary gland.

Being developmental in origin, arachnoid cysts can be detected on prenatal screening. Prenatal ultrasound and magnetic resonance imaging (MRI) have led to the increased diagnosis of central nervous system abnormalities of the fetuses over the past few years.

¹Medical College, The Aga Khan University, ²⁻⁵Section of Neonatology Department of Pediatrics Aga Khan University Hospital, Karachi, Pakistan.

Correspondence: Aneela Darbar. Email: aneela.darbar@aku.edu

Mostly the arachnoid cysts are an incidental finding. Through this report, we aim to help the reader to understand the importance of diagnosing a potentially life threatening cyst prenatally and the treatment approaches in such conditions.

Case Report

A 22 years old primigravida was scanned routinely at 21 weeks of gestation at a local private Hospital in Karachi, Pakistan. The ultrasound scan showed a non-communicating arachnoid cyst measuring 1.6 x 2.9 cm in the foetus. The scan was repeated after 7 weeks which showed a rapid increase in the size of the cystic lesion. The ultrasound findings were explained to the family and the mother was referred to our institution Aga Khan University Hospital, immediately.

Foetal Magnetic Resonance Imaging (MRI) was recommended to rule out agenesis of corpus callosum. Antenatal MRI was performed at 29 weeks gestation which revealed an extra-axial mass measuring 35.9 x 30.7 x 34 mm having compression effect over midbrain and medulla with no evidence of hydrocephalus. A series of ultrasound scans at 31 and 35 weeks gestation showed sequential increase in size of the cyst. An antenatal neurology input was taken by the primary Obstetrician. The mother had no known co-morbid and all the infectious viral markers were negative. The plan was to

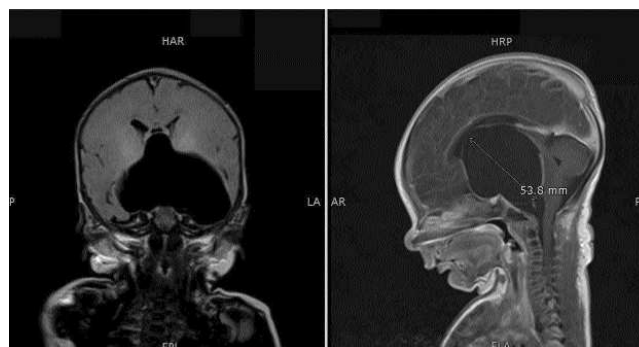


Figure-1: A large extra-axial, well defined CSF intensity cystic lesion seen in midline in sellar and suprasellar region causing compression effect on third ventricle and bilateral lateral ventricles.

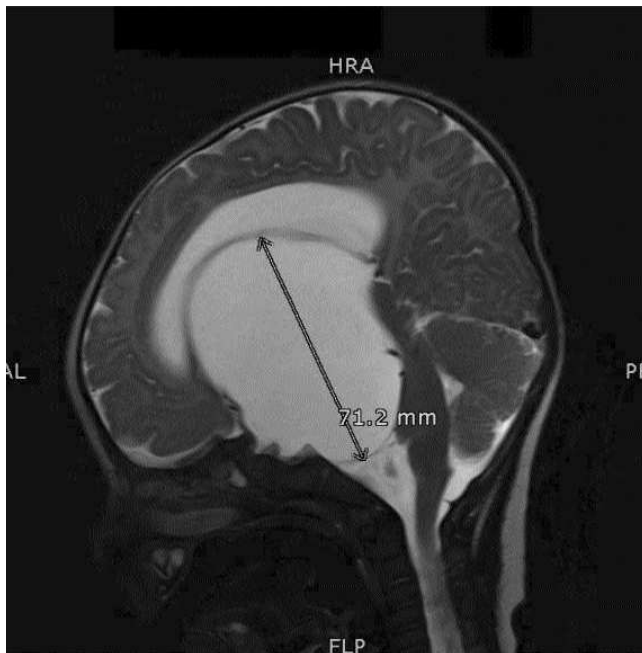


Figure-2: Status post left pterional craniotomy. Redemonstration of large well defined extra axial CSF intensity in sellar and suprasellar region. Interval increase in size and development of hydrocephalus.

followup after birth of the baby.

A baby, weighing 3700 grams, was born at 38 weeks of gestation via emergency Lower Segment Caesarean Section (LSCS) due to non-progress of labour on 19/2/15. The neonate had stable vital findings with unremarkable physical examination. A post natal MRI performed in the first week of life showed a large extra-axial, well defined CSF intensity cystic lesion identified in suprasellar region. Since the baby was asymptomatic, any urgent intervention was deferred. The baby was, therefore, discharged from NICU after 3 days in stable condition. The plan was to follow head circumference and signs and symptoms of raised intra-cranial pressure (ICP).

During his third week of life, baby developed signs and symptoms of raised ICP with FOC increased from 36 cm to 41 cm over a span of 40 days. He was admitted and underwent another MRI which reported a large extra-axial, well-defined CSF intensity cystic lesion identified in the midline in the sellar and suprasellar region compressing the third and lateral ventricles.

Since the bilateral frontal horns of the lateral ventricle were small, this cyst could not be accessed endoscopically via the right frontal horn. Therefore a left pterional craniotomy for cystocisternostomy of large suprasellar cyst was carried out on 08/04/15. The intra-operative

findings included a cystic lesion containing CSF like fluid and involving sellar, suprasellar and left temporal area. The final diagnosis was of Suprasellar arachnoid cyst with raised ICP. Unfortunately, the success of the surgery was short lived and the baby presented in Neurosurgery Clinic after a month with bulging anterior fontanelle and FOC of 43.5 cm (> 98th percentile). The repeat MRI showed hydrocephalus and recurrence of arachnoid cyst. Due to hydrocephalus left ventricle was dilated ten days later, Endoscopic Third Ventriculostomy with fenestration of cyst was done. On follow-up the baby is doing well with no delayed milestones and FOC at 90th percentile on the last visit. The parents' consent was taken prior to surgery and the case to be available for any future research study as part of our institutions routine protocol.

Discussion

Suprasellar arachnoid cysts arise from diencephalic membrane of Lilliequist.² An arachnoid cyst can develop at a number of locations within the brain including the main brain fissures such as Sylvian, Rolandic and interhemispheric fissures, the anterior and the middle cranial fossa or the Sella.³ Foetal arachnoid cysts can also be associated with chromosomal abnormalities.⁴ Prenatal diagnosis of an arachnoid cyst, therefore, should be followed by cytogenetic investigation.

Most suprasellar arachnoid cysts are diagnosed after they have caused symptoms in childhood. The symptoms depend upon the location of the cyst and may include endocrine abnormalities. Adan et al. reported that of 30 suprasellar arachnoid cysts studied, 60% had association with endocrine disorders.⁵

Arachnoid cysts occasionally present with neurologic signs and symptoms but most cases are asymptomatic with the cysts as incidental findings.⁶ Cysts, if symptomatic, should always be treated.⁷ Arachnoid cyst, no matter how small in size, if they block the normal CSF pathways and cause symptomatic hydrocephalus, merit surgical intervention.

Prenatal sonography can show an arachnoid cyst as early as 20 weeks' gestation. Bretelle et al. has reported a posterior fossa arachnoid cyst detected at 13 weeks' gestation by Transvaginal Sonography (TVS).⁸ Recent larger studies have estimated prevalence of arachnoid cyst on imaging at about 2%.⁶ This means that prenatal diagnosis is not that rare in the developed countries where neuro-rehabilitation as well as resources in terms of health care, social support and parental guidance education and awareness are available.

Health and rehabilitation systems of a developing country

including Pakistan are believed to have negligible recognition of disabled in the society. A low literacy rate and health budget, there is lack of awareness of such disorders amongst patients, parents and, no recognition in society about, available treatment options and post-treatment rehabilitation.

Operative management is indicated for increased cyst growth and neural compression in paediatric patients. The significant potential morbidity of microsurgical fenestration and the high incidence of failures and infections in cystoperitoneal shunting compelled neurosurgeons to search for an alternative procedure. Endoscopy has been recently considered to be a better intervention as it maintains the basic surgical strategy of marsupialization without the invasiveness of open craniotomy and avoiding the complications caused by shunt treatment.⁹ Suprasellar arachnoid cysts are especially amenable to endoscopic treatment because of their location in the anterior portion of the third ventricle.

Conclusion

This case of a suprasellar arachnoid cyst, identified on a prenatal sonography was managed successfully at our institution, involving multidisciplinary approach with consultants from Obstetric, Neonatologists, Neurologist and Neurosurgery team.

To our knowledge, 3-D sonographic findings and related images in such a case have been rare. Use of radiology doesn't end with initial diagnosis. There is a need of series of ultrasound scans and MRI to monitor the changes in cyst size and, if any complications arise in the brain,

prompting interventional measures. Clearly, any such diagnosis indicates the healthcare advancement of a country by making way for early treatment and better outcome.

Disclaimer: None.

Conflict of Interest: None.

Funding Disclosure: None.

References

1. Moon KS, Lee JK, Kim JH, Kim H: Spontaneous disappearance of a suprasellar arachnoid cyst: Case report and review of the literature. *Childs Nerv Syst.* 2007; 23: 99-104.
2. Miyajima M, Arai H, Okuda O, Hishii M, Nakanishi H, Sato K: Possible origin of suprasellar arachnoid cysts: neuroimaging and neurosurgical observations in nine cases. *J Neurosurg.* 2000; 93: 62-7.
3. Gelabert-González M. [Intracranial arachnoid cysts] *Rev Neurol.* 2004; 39: 1161-6.
4. Chen CP. Prenatal diagnosis of arachnoid cysts. *Taiwan J Obstet Gynecol.* 2007; 46: 187-98.
5. Adan L, Bussieres L, Dinand V, Zerah M, Pierre-Kahn A, Brauner R. Growth, puberty and hypothalamic-pituitary function in children with suprasellar arachnoid cyst. *Eur J Pediatr.* 2000; 159: 348-55.
6. Al-Holou WN, Terman S, Kilburg C, Garton HJ, Muraszko KM, Maher CO. Prevalence and natural history of arachnoid cysts in adults. *J Neurosurg.* 2013; 118: 222-31.
7. Gangemi M, Seneca V, Colella G, Cioffi V, Imperato A, Maiuri F. Endoscopy versus microsurgical cyst excision and shunting for treating intracranial arachnoid cysts. *J Neurosurg Pediatr.* 2011; 8: 158-64.
8. Bretelle F, Senat MV, Bernard JP, Hillion Y, Ville Y. First-trimester diagnosis of fetal arachnoid cyst: prenatal implication. *Ultrasound in obstetrics & gynecology: the official Ultrasound Obstet Gynecol.* 2002; 20: 400-2.
9. Shim KW, Lee YH, Park EK, Park YS, Choi JU, Kim DS: Treatment option for arachnoid cysts. *Childs Nerv Syst.* 2009; 25: 1459-66.